

## Anomalous Hepatic Venous Drainage into the Left Atrium: An Unusual Cause of Hypoxemia

James K Stoller MSc MD FAARC, Robert M Hoffman MD,  
Richard D White MD, and Roger BB Mee MB ChB

**A 50-year-old woman with life-long hypoxemia and digital clubbing had a transient ischemic attack at age 47, without identifiable vascular or cardioembolic source. Extensive work-up revealed a 20% anatomic shunt (while breathing 100% oxygen) and evidence of an intrapulmonary shunt (an agitated saline, contrast-enhanced transesophageal echocardiogram showed bubbles in the left atrium and in 3 of the 4 visualized pulmonary veins) but without evidence of the hepatopulmonary syndrome, intrapulmonary arteriovenous malformations, or any intracardiac shunt. She had the congenital anomalies of cleft palate and lip and inferior vena caval interruption with azygos continuation, and anomalous hepatic venous drainage into the left atrium. In keeping with the sparse evidence of 12 previously reported patients with anomalous hepatic-venous-to-left-atrial drainage, the intrapulmonary shunt was believed to result from the diversion of hepatic venous blood from the pulmonary circulation. Surgical correction of the anomalous drainage and restoration of hepatic venous drainage into the right atrium immediately improved oxygenation, and follow-up contrast-enhanced echocardiography 3 months after the surgery showed resolution of the associated intrapulmonary shunt. This case extends the sparse available evidence with this unusual combination of congenital anomalies, reminds clinicians to consider unusual causes of right-to-left shunt and of paradoxical embolization, and invites clarification of the mechanism by which anomalous hepatic venous drainage into the left atrium allows reversible intra-pulmonary right-to-left shunt. Key words: hypoxemia, right-to-left shunt, anatomic shunt, anomalous hepatic venous drainage. [Respir Care 2003;48(1):58–62]**

### Introduction

Anatomic shunts that permit venous admixture with oxygenated blood cause hypoxemia that is refractory to the

---

James K Stoller MSc MD FAARC is affiliated with the Section of Respiratory Therapy, Department of Pulmonary and Critical Care Medicine, Division of Medicine, The Cleveland Clinic Foundation, Cleveland, Ohio. Robert M Hoffman MD is affiliated with the Division of Pulmonary, Allergy, and Critical Care Medicine, Department of Medicine, University of Pittsburgh School of Medicine, Pittsburgh, Pennsylvania. Richard D White MD is affiliated with the Section of Cardiovascular Imaging, The Cleveland Clinic Foundation, Cleveland, Ohio. Roger BB Mee MB ChB is affiliated with the Department of Pediatric and Congenital Heart Surgery, The Cleveland Clinic Foundation, Cleveland, Ohio.

Correspondence: James K Stoller MSc MD FAARC, Department of Pulmonary and Critical Care Medicine, A 90, The Cleveland Clinic Foundation, 9500 Euclid Avenue, Cleveland OH 44195. E-mail: stollej@ccf.org.

administration of supplemental oxygen.<sup>1</sup> Though uncommon, well-recognized causes of anatomic shunt include: intrapulmonary right-to-left shunt (such as occurs with arteriovenous malformations<sup>2</sup> or intrapulmonary vascular dilatation in hepatopulmonary syndrome<sup>3,4</sup> or “pulmonary telangiectasia”<sup>5</sup>), and intracardiac shunt with predominately right-to-left flow<sup>6</sup> (such as may accompany atrial septal defect or ventricular septal defect with Eisenmenger’s physiology).

To extend the spectrum of causes of anatomic right-to-left shunt leading to hypoxemia, we describe the unusual case of a middle-aged woman with longstanding hypoxemia found to have anomalous hepatic venous drainage into her left atrium. Concomitant congenital anomalies included interruption of the intrahepatic inferior vena cava with azygos extension, and cleft palate and lip. Another unusual aspect of this patient’s findings was echocardiographic evidence of an intrapulmonary shunt (agitated saline, contrast-enhanced echocardiogram showed bubbles

in 3 of the 4 visualized pulmonary veins), which resolved after surgical diversion of hepatic venous blood to the right atrium.

### Case Presentation

A 50-year-old woman was referred to the Cleveland Clinic Foundation for evaluation of life-long dyspnea on exertion and hypoxemia without platypnea. She had undergone cleft lip and palate repair in childhood for a congenital defect.

She reported having had blue, clubbed digits since her earliest memory. Her medical history included a reported pulmonary embolism after childbirth, for which she was anticoagulated for 6 months. A second pulmonary angiogram was performed 1 year later to assess persistent hypoxemia and failed to show evidence of either acute or chronic thromboembolism. There was no history of chronic liver disease or known hepatic risk factors. At age 47, she experienced a transient ischemic attack for which anticoagulation was resumed and continued until her current referral. Over several years before her referral, she had undergone an extensive workup at several institutions, which included a normal chest radiograph, abdominal computed tomography that showed a normal liver and spleen and azygos extension of the inferior vena cava, and a contrast-enhanced surface echocardiogram showing bubbles in 3 of 4 visualized pulmonary veins, consistent with an intrapulmonary shunt. A prior technetium<sup>99m</sup> pyrophosphate lung scan showed no uptake over brain and kidneys (estimated shunt 2.8%), and a pulmonary angiogram was normal (ie, with no pulmonary emboli, no visible arteriovenous malformations, and no “spongy” vasculature to suggest intrapulmonary vascular dilatations [Figure 1]). A shunt study in which she breathed 100% oxygen estimated a 20% shunt.

On presentation to the Cleveland Clinic, her physical examination showed digital clubbing, cyanosis, a clear chest examination without bruits, normal cardiac examination, and no stigmata of chronic liver disease. Her blood oxygen saturation (measured via pulse oximetry) on room air, in the sitting position, was 86%, with no further desaturation on standing. Liver function tests were normal.

Our evaluation included a 100% oxygen shunt study that confirmed a 19.6% shunt ( $P_{aO_2}$  253 mm Hg,  $P_{aCO_2}$  34 mm Hg while on 100% oxygen) and, on suspicion of a right-to-left shunt involving abdominal vessels, a gadolinium-enhanced magnetic resonance image of the chest and abdomen, with injection through the femoral vein. This study confirmed her known azygos extension of the inferior vena cava and revealed complete anomalous drainage of the hepatic veins into the left atrium (Fig. 2). Cardiac catheterization showed normal pulmonary artery pressures (32/12 mm Hg, mean 20 mm Hg).

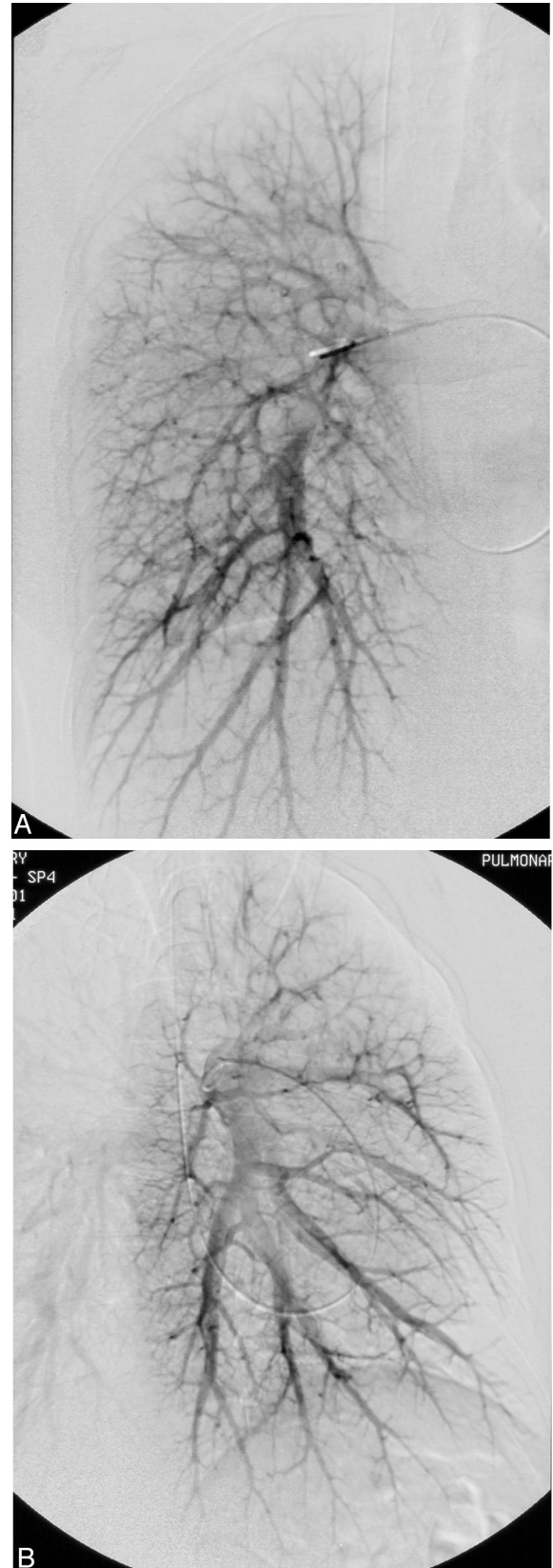


Fig. 1. A: Right pulmonary angiogram. B: Left pulmonary angiogram.

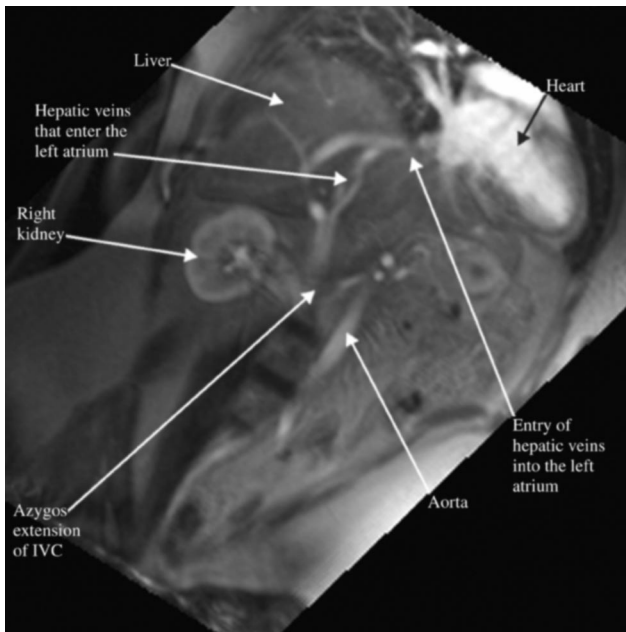


Fig. 2. Magnetic resonance image of abdomen and chest shows the inferior vena cava, the azygos extension, and the anomalous entry of the hepatic veins into the left atrium.

Surgical repair successfully diverted the hepatic venous blood to the right atrium by excising the intrapericardial vena cava and hepatic veins from the left atrium and anastomizing the hepatic veins to the right atrium. The patient's intra-operative oxygenation improved dramatically but incompletely; an arterial blood gas sample while on 100% oxygen showed a  $P_{aO_2}$  of 520 mm Hg, suggesting postoperative persistence of some anatomic shunt. At a 3-month postoperative follow-up visit, her resting, room-air, pulse-oximetry saturation was 98%, and a repeat agitated saline, contrast-enhanced echocardiogram showed resolution of the pre-operative intrapulmonary shunt (ie, no bubbles were visible in the left-sided cardiac chambers).

### Discussion

Our patient's unusual clinical presentation highlights several noteworthy features:

1. Anomalous hepatic venous drainage into the left atrium, causing an anatomic right-to-left shunt and, along with the associated intrapulmonary shunt, sequelae of hypoxemia
2. Suspected paradoxical embolism as a cause of her transient ischemic attack, probably through the anomalous hepatic-venous-to-left-atrial shunt
3. The association of an intrapulmonary shunt with the anomalous hepatic venous drainage
4. Concomitant congenital anomalies, including cleft lip and palate and intrahepatic inferior vena caval interruption with azygos extension to the superior vena cava

5. Successful surgical repair with correction of the anomalous venous drainage and subsequent resolution of the intrapulmonary right-to-left shunt

Though review of the literature does not indicate a recognized syndrome that subsumes all the congenital anomalies present in our patient, an extensive MEDLINE search (1966–July 2002, using the search terms “anomalous venous drainage, hepatic veins, left atrium”) identified 12 earlier-reported patients with anomalous hepatic venous drainage into the left atrium (Table 1).<sup>7–17</sup> In 7 of those patients, the hepatic venous drainage into the left-sided circulation was a consequence of a cardiac surgical shunt procedure,<sup>9,10,12–14,16</sup> whereas 5 patients<sup>7,8,11,15,17</sup> have been described with congenital anomalous hepatic venous drainage into the left atrium. Notably, unlike our patient, all the described patients were children (ages 20 months to 12 years), and in none was cleft palate and lip reported. As in our patient, azygos extension of the inferior vena cava was present in 2 of the previously reported individuals<sup>15,17</sup> with congenital anomalous hepatic venous drainage into the left atrium, and was also described in 2 children<sup>12,16</sup> in whom the anomalous hepatic venous drainage developed after a cardiac procedure, either a Kawashima operation (a procedure that creates a total cavopulmonary shunt by creating an end-to-side anastomosis between the superior vena cava [with azygos or hemiazygos flow] and the confluent pulmonary artery)<sup>12</sup> or closure of a ventricular septal defect with resection of right ventricular outflow obstruction.<sup>16</sup>

The unusual constellation of congenital anomalies in our patient invites embryologic explanation. Indeed, in an early report of anomalous hepatic venous drainage into the left atrium, Yee<sup>8</sup> suggested that the malformation involves abnormal enlargement of the sinus venosus (the precursor of the heart) and preservation of the right subcardinal vein.

We speculate that the anomalous hepatic venous drainage into the left atrium provided the conduit for paradoxical embolism that caused our patient's transient ischemic attack at age 47. In the absence of our assessing the patient close in time to the ischemic event (ie, she was first referred to the Cleveland Clinic only several years later), several indirect lines of evidence support this suggestion:

1. No cardioembolic source was evident.
2. The patient's youth at the time of the ischemic event argues against carotid disease as a cause.
3. No patent foramen ovale or other cardiac-level communication was found on subsequent transesophageal echocardiography conducted specifically to look for sources of right-to-left flow.
4. Recurrent cerebral ischemia has been described as a consequence of anomalous hepatic venous drainage into the left atrium.<sup>18</sup>

## ANOMALOUS HEPATIC VENOUS DRAINAGE INTO THE LEFT ATRIUM

Table 1. Available Reports of Anomalous Hepatic Venous Drainage into the Left Atrium

Author	Year	Patients (n)	Presentation	Associated Anomalies/Comments
Nagai et al <sup>7</sup>	1966	1	12-year-old girl	Left atrium communicates with coronary sinus through a 1.5-cm ostium; hepatic vein opened into the coronary sinus
Yee <sup>8</sup>	1968	1	20-month-old boy with cyanosis	Tetralogy of Fallot; anomalous pulmonary venous drainage into right atrium; right-sided aortic arch; patent foramen ovale; bicuspid pulmonary valve
Guenthard et al <sup>9</sup>	1990	1	11-year-old with cyanosis after Blalock shunt for subpulmonary stenosis	Hepatic vein drained to right-sided, physiologically left atrium; subpulmonary stenosis; common atrium; common atrioventricular valve
Hirayama et al <sup>10</sup>	1991	1	5-year-old boy	Double-outlet right ventricle; mitral atresia; pulmonic stenosis
Mantri et al <sup>11</sup>	1994	1	12-year-old girl	Infundibular pulmonic stenosis; bifurcated inferior vena cava with drainage into coronary sinus and entry of hepatic vein
Knight and Mee <sup>12</sup>	1995	1	Infant with progressive hypoxemia after Kawashima operation	Left atrial isomerism; double-outlet right ventricle; hypoplastic left ventricle; subpulmonic stenosis; azygos extension of inferior vena cava; intrapulmonary shunt regressed after anomalous hepatic venous blood was redirected
Fernandez-Martorell et al <sup>13</sup>	1996	2	5-year-old girl with cyanosis following fenestrated Fontan procedure for tricuspid atresia; anomalous hepatic vein to right atrium was included in the pulmonary venous atrium following procedure.	Double-outlet right ventricle; hypoplastic left ventricle; anomalous pulmonary venous drainage to right atrium
			2-year-old boy with cyanosis following Fontan procedure, anomalous hepatic venous drainage as above.	Double-outlet right ventricle; mitral atresia; pulmonary atresia; D-malposition of the great vessels
Tofeig et al <sup>14</sup>	1998	1	67-month-old underwent Fontan procedure, after which cyanosis developed because of hepatic venous entry into the pulmonary venous atrium.	Right atrial isomerism; common atrium; small left ventricle with atrioventricular septal defect; double-outlet right ventricle; pulmonary stenosis; hepatic venous return was occluded with a septal occluder, with restoration of normal oxygenation
Lee et al <sup>15</sup>	1998	1	9-year-old with cyanosis and clubbing	Azygos extension of the inferior vena cava; intrapulmonary right-to-left shunt accompanied the anomalous hepatic venous drainage to left atrium; the intra-pulmonary shunt resolved after the hepatic veins were diverted to the right atrium
Duncan et al <sup>15</sup>	1999	1	12-year-old boy with cyanosis	Visceral heterotaxia; dextrocardia; ventricular septal defect; right ventricular outflow tract obstruction; secundum atrial septal defect; left inferior vena cava; azygos extension of inferior vena cava; thoracic left isomerism
Johnson et al <sup>17</sup>	2002	1	11-year-old boy with total anomalous systemic venous return	Azygos extension of a left-sided inferior vena cava; secundum atrial septal defect; left-sided superior vena cava; mild factor VIII deficiency; asplenia

5. The absence of angiographically visible intrapulmonary right-to-left shunt makes the intrapulmonary shunt an unlikely conduit for paradoxical embolization.

Based on this assessment, surgical diversion of the anomalous hepatic venous drainage into the pulmonary circulation allowed us to recommend cessation of her anticoagulation several months after the surgery.

Another unusual aspect of this patient's presentation is the concurrent presence of an intrapulmonary right-to-left shunt accompanying the anomalous hepatic venous drainage. Widely recognized causes of intrapulmonary shunt,

such as intrapulmonary dilatations accompanying the hepatopulmonary syndrome,<sup>3,4</sup> pulmonary arteriovenous malformations in Rendu-Osler-Weber syndrome,<sup>2</sup> or "pulmonary telangiectasia"<sup>5</sup> were excluded in our patient by the absence of liver disease and by the normal pulmonary angiogram. Rather, we suspect that the cause of the intrapulmonary shunt in this patient was the exclusion of hepatic venous blood from the lung. Indeed, this mechanism has been amply described in children undergoing Glenn shunt (superior vena cava to right pulmonary artery anastomosis), Fontan procedure (atriopulmonary anasto-

mosis to allow bilateral pulmonary arterial flow), and Kawashima shunt procedure for tricuspid atresia, where intrapulmonary shunt have been described as developing in up to 21% of patients undergoing the procedure.<sup>19</sup> Furthermore, such shunts have been shown to regress when the hepatic venous drainage is diverted back through the pulmonary circulation.<sup>14,17</sup> Similarly, intrapulmonary shunt has been described in a patient like ours with anomalous hepatic venous drainage to the left atrium accompanying inferior vena cava interruption and azygos extension of the inferior vena cava.<sup>15</sup> As in our patient, that patient's intrapulmonary shunt regressed with surgical correction of the anomalous venous drainage.

Regarding the putative mechanism by which intrapulmonary shunt develops, several investigators<sup>12,16</sup> have proposed that the exclusion of a hepatic factor from the pulmonary circulation allows shunt development. Based on observations of lakes of dilated, thin-walled vessels and chains of clustered, smaller vessels in the lungs from 2 children in whom intrapulmonary shunt developed after cardiac surgery, Duncan et al<sup>16</sup> speculated that this factor may be an inhibitor of endothelial proliferation. The similarity to the development of intrapulmonary vascular dilatations in patients with the hepatopulmonary syndrome invites speculation about whether nitric oxide could be implicated in inducing the observed vascular changes.<sup>20,21</sup> As with the reversal of intrapulmonary vascular dilatations in the hepatopulmonary syndrome following liver transplantation,<sup>22</sup> further evidence of a humoral mediator is the reversal of the intrapulmonary shunt after surgical diversion of anomalous hepatic venous blood into the pulmonary circulation and the ipsilateral, single-lung angiographic appearance of intrapulmonary shunt when hepatic venous blood is excluded from only one lung.<sup>19</sup>

In summary, this report of a patient with hepatic venous drainage into the left atrium extends the sparse available evidence about this unusual anomaly. As in a few earlier reports, our patient also experienced an intrapulmonary shunt accompanying the anomalous hepatic venous drainage, which regressed after surgical correction of the anomalous hepatic venous drainage. Indeed, these prior reports documenting disappearance of the intrapulmonary shunt once the hepatic venous drainage was diverted to the right atrium suggest that exclusion of hepatic venous blood from the lungs can predispose to a reversible intrapulmonary shunt.

#### REFERENCES

- Comroe JH, Forster RE, Dubois AB, Briscoe WA, Carlsen E. The lung: clinical physiology and pulmonary function tests, 2nd ed. St Louis: Year Book Medical Publishers; 1977:148–149.
- Guttmacher AE, Marchuk DA, White RI Jr. Hereditary hemorrhagic telangiectasia. *N Engl J Med* 1995;333(14):918–924.
- Krowka MJ, Cortese DA. Hepatopulmonary syndrome: current concepts in diagnostic and therapeutic considerations. *Chest* 1994;105(5):1528–1537.
- Lange PA, Stoller JK. The hepatopulmonary syndrome. *Ann Intern Med* 1995;122(7):521–529.
- Charles TJ, Davies AB. Pulmonary telangiectasia. *Br J Dis Chest* 1979;73(3):309–313.
- Mercho N, Stoller JK, White RD, Mehta AC. Right-to-left interatrial shunt causing platypnea after pneumonectomy: a recent experience and diagnostic value of dynamic magnetic resonance imaging. *Chest* 1994;105(3):931–933.
- Nagai I, Oda Y, Kawada K, Yamamoto K, Iri H. [Case of communication of the left atrium and the coronary sinus complicated by anomalous hepatic vein return.] *Kyobu Geka* 1966;19(5):363–366. *article in Japanese*
- Yee KF. Anomalous termination of a hepatic vein in the left atrium. *Arch Pathol* 1968;85(2):219–223.
- Guenthard J, Carvalho JS, Anderson RH, Rigby ML. Hepatic venous connection to a persistent inferior caval vein in left isomerism. *Eur Heart J* 1990;11(9):845–847.
- Hirayama T, Imai Y, Kurosawa H, Nakae S, Fukuchi S, Hoshino S. [Fontan procedure for DORV with mitral atresia and anomalous hepatic vein connection to the left atrium: advantage of leaving right to left shunt in situ]. *Nippon Kyobu Geka Gakkai Zasshi* 1991;39(1):76–80. *article in Japanese*
- Mantri RR, Bajaj R, Shrivastava S. Multiple anomalies of caval veins in a patient with pulmonic stenosis. *Int J Cardiol* 1994;46(2):172–174.
- Knight WB, Mee RB. A cure for pulmonary arteriovenous fistulas? *Ann Thorac Surg* 1995;59(4):999–1001.
- Fernandez-Martorell P, Sklansky MS, Lucas VW, Kashani IA, Cocalis MW, Jamieson SW, Rothman A. Accessory hepatic vein to pulmonary venous atrium as a cause of cyanosis after the Fontan operation. *Am J Cardiol* 1996;77(15):1386–1387.
- Tofeig M, Walsh KP, Arnold R. Transcatheter occlusion of a post-Fontan residual hepatic vein to pulmonary venous atrium communication using the Amplatzer septal occluder. *Heart* 1998;79(6):624–626.
- Lee J, Menkis AH, Rosenberg HC. Reversal of pulmonary arteriovenous malformation after diversion of anomalous hepatic drainage. *Ann Thorac Surg* 1998;65(3):848–849.
- Duncan BW, Kneebone JM, Chi EY, Hraska V, Isik FF, Rosenthal GL, et al. A detailed histologic analysis of pulmonary arteriovenous malformations in children with cyanotic congenital heart disease. *J Thorac Cardiovasc Surg* 1999;117(5):931–938.
- Johnson TR, Schamberger MS, Brown JW, Girod DA. Resolution of acquired pulmonary arteriovenous malformations in a patient with total anomalous systemic venous return. *Pediatr Cardiol* 2002;23(2):210–212.
- Busch T, Aleksic I, Schulze F, Sirbu H, Dalichau H. Retrocardiac arteriovenous malformation causing recurrent cerebral ischemia. *Ann Thorac Surg* 2000;70(2):663–665.
- Srivastava D, Preminger T, Lock JE, Mandell V, Keane JF, Mayer JE Jr, et al. Hepatic venous blood and the development of pulmonary arteriovenous malformations in congenital heart disease. *Circulation* 1995;92(5):1217–1222.
- Soderman C, Leone A, Furst V, Persson MG. Endogenous nitric oxide in exhaled air from patients with liver cirrhosis. *Scand J Gastroenterol* 1997;32(6):591–597.
- Fallon MB, Abrans GA, Luo B, Hou Z, Dai J, Ku DD. The role of endothelial nitric oxide synthase in the pathogenesis of a rat model of hepatopulmonary syndrome. *Gastroenterology* 1997;113(2):606–614.
- Stoller JK, Lange PA, Westveer MK, Carey WD, Vogt D, Henderson JM. Prevalence and reversibility of the hepatopulmonary syndrome after liver transplantation: The Cleveland Clinic experience. *West J Med* 1995;163(2):133–138.