

Tracheal Bronchus

Naim Y Aoun MD, Eduardo Velez MD, Lawrence A Kenney MD, and Edwin E Trayner MD

Introduction

The term tracheal bronchus refers to an abnormal bronchus that comes directly off the lateral wall of the trachea (ie, above the main carina) and supplies ventilation to the upper lobe. It is most often an asymptomatic anatomical variant found on bronchoscopy as seen in the following case presentation.

Case Report

A 65-year-old white woman was seen because of 2 episodes of mild hemoptysis complicating a persistent cough. Her medical history was positive for 8 years of mild shortness of breath and an indirect exposure to asbestos. Her review of systems was unremarkable and physical examination showed normal vital signs and blood oxygen saturation of 97% on room air. Air entry was normal and there were no wheezes, crackles, or rhonchi. No lymph nodes were palpated and there was no clubbing. Pulmonary function testing showed a mild restriction. For hypertension and coronary artery disease she was taking furosemide and atenolol. A high-resolution computed tomogram of the chest was entirely normal.

Flexible bronchoscopy was performed to investigate the etiology of the hemoptysis. No sources of bleeding or endobronchial lesions were found. Bronchoalveolar lavage was negative for culture and cytology. However, the patient was found to have an accessory bronchial take-off on the right side of the trachea 1–2 cm above the main carina, leading to the apical segment of the right upper lobe (Figs. 1, 2, and 3). The right main bronchus morphology was normal. The right upper-lobe bronchus had only 2 segments: the posterior and the anterior.

At a 6-month follow-up visit the patient's hemoptysis had not recurred.

Discussion

The patient had an anatomical variant called tracheal bronchus or eparterial bronchus. We believe her symptoms were unrelated to the tracheal bronchus and that it was an incidental bronchoscopy finding.

Sandifort first described tracheal bronchus in 1785.¹ Its incidence^{2,3} is 0.1–2% and in most cases it is incidentally found during bronchoscopy or tomography.^{4,5} In the majority of cases a tracheal bronchus arises from the right wall of the trachea. In a recent series of 35 tracheal bronchus patients 28 originated from the right wall and 7 from the left,⁴ which disproves the previous belief that tracheal bronchi are exclusively right-sided.² There is an association between tracheal bronchus and other congenital malformations, mainly malformations of the ribs and vertebrae.⁶ Patients with Down syndrome have a higher incidence of tracheal bronchus.³

The anomalous bronchus can arise anywhere from the carina to the cricoid cartilage, but most frequently within 2 cm of the carina.⁴ Tracheal bronchi are classified as being either “displaced” or “supernumerary.”

A *displaced* bronchus is an anomalous cephalad location of the right upper lobe bronchus or any of its segments, most commonly the apical. If the entire right upper lobe takes off from the trachea the right main bronchus is the bronchus intermedius, feeding the right middle and lower lobes, and the malformation is called “true tracheal bronchus” or “bronchus sui” (“pig bronchus,” because that is the normal morphology in pigs). The incidence of true tracheal bronchus is 0.2%.⁴

If the anomalous bronchus is the take-off of the apical segment of the right upper lobe, as was the case in our patient, the right main bronchus will be normal looking, but the right upper lobe will not have its trifurcation. Instead there will be a bifurcation, corresponding to the anterior and posterior segments. That variant is called “apical tracheal bronchus,”⁷ which has been described in patients who have an azygos lobe. In that situation the apical segment will have its own displaced bronchus and its own

Naim Y Aoun MD, Eduardo Velez MD, Lawrence A Kenney MD, and Edwin E Trayner MD are affiliated with the Department of Pulmonary and Critical Care Medicine, Caritas Saint Elizabeth Medical Center, Brighton, Massachusetts.

Correspondence: Naim Y Aoun MD, Department of Pulmonary and Critical Care Medicine, Caritas Saint Elizabeth Medical Center, 736 Cambridge Street, Brighton MA 02135. E-mail: naoun@copdnet.org.

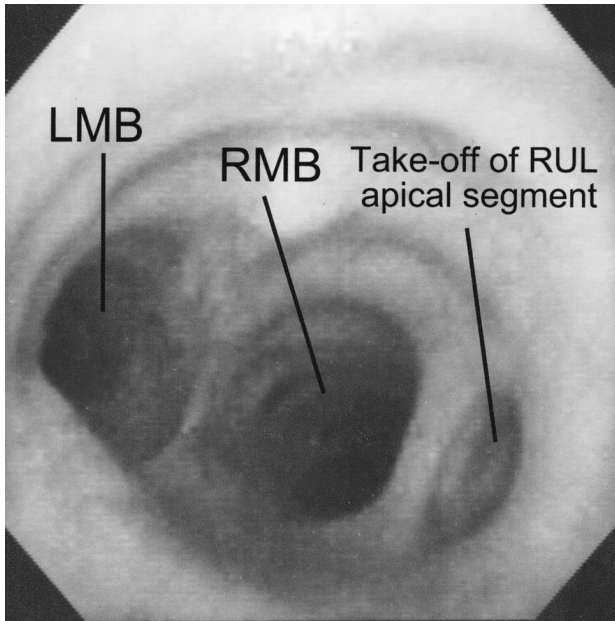


Fig. 1. Bronchoscopic view of a tracheal bronchus. The tracheal bronchus takes off approximately 2 cm above the main carina and feeds the apical segment.

pleural investment.⁶ Vascular supply and venous drainage are usually normal in the displaced bronchus variant and are provided by the pulmonary artery and pulmonary veins.⁸

Supernumerary bronchus is less common than displaced bronchus⁴ and can coexist with normal right-upper-lobe branching. Supernumerary tracheal bronchus aerates either normal lung parenchyma, a cyst,⁴ or (rarely) ends in a blind pouch, called a "trachea diverticulum."³ The supernumerary lung tissue can be intralobar or extralobar, depending on whether it shares

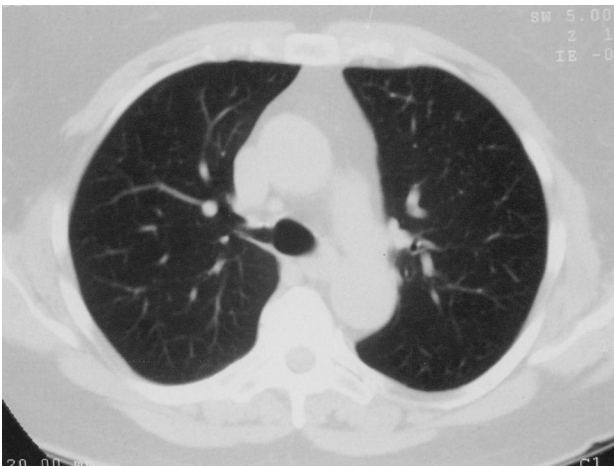


Fig. 2. Computed tomogram of the chest. This slice is through the trachea, 2 cm above the main carina and shows the take-off of the tracheal bronchus into the apical segment of the right upper lobe.

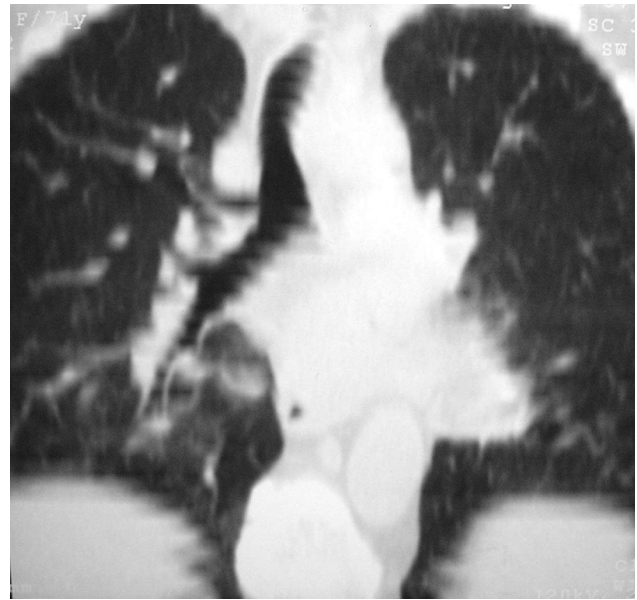

Fig. 3. Frontal-view reconstruction tomogram of the tracheal bronchus.

the pleura of the upper lobe. It can have its own vascular supply, which can be from the systemic or the pulmonary artery system.⁸

Tracheal bronchi are usually asymptomatic. Among pediatric patients tracheal bronchi have been associated with recurrent infection, stridor, respiratory distress, and thoracic masses.² With adults the main implication of a tracheal bronchus is during endotracheal intubation: an endotracheal tube can occlude the lumen of the tracheal bronchus, resulting in atelectasis of the involved lobe or segment, post-obstructive pneumonia, or even respiratory failure.⁹ Accidental intubations of the anomalous lobe can cause pneumothorax and inadequate ventilation of the remaining lung.³ Patients who are aware that they have tracheal bronchus should inform the anesthesiologist prior to elective surgery, to avoid complications.^{10,11} Several cases have been reported of lung carcinoma and adenomatoid cysts originating in a tracheal lobe.¹²

The majority of patients with tracheal bronchi are asymptomatic and do not require any medical intervention. In the case of recurrent pneumonia complicated by bronchiectasis surgical resection of the anomalous lobe or segment is the treatment of choice.²

REFERENCES

1. Kubik S, Muntener M. [Bronchus abnormalities: tracheal, eparterial, and pre-eparterial bronchi] *Fortschr Geb Rontgenstr Nuklearmed* 1971;114(2):145-163. article in German
2. McLaughlin FJ, Strieder DJ, Harris GB, Vawter GP, Eraklis AJ. Tracheal bronchus: association with respiratory morbidity in childhood. *J Pediatr* 1985;106(5):751-755.

TRACHEAL BRONCHUS

3. Doolittle AM, Mair EA. Tracheal bronchus: classification, endoscopic analysis, and airway management. *Otolaryngol Head Neck Surg* 2002;126(3):240–243.
4. Ghaye B, Szapiro D, Fanchamps J-M, Dondelinger RF. Congenital bronchial abnormalities revisited. *Radiographics* 2001;21(1):105–119.
5. Freeman SJ, Harvey JE, Goddard PR. Demonstration of supernumerary tracheal bronchus by computed tomographic scanning and magnetic resonance imaging. *Thorax* 1995;50(4):426–427.
6. Setty SP, Michaels AJ. Tracheal bronchus: case presentation, literature review, and discussion. *J Trauma* 2000;49(5):943–945.
7. Barat M, Konrad HR. Tracheal bronchus. *Am J Otolaryngol* 1987;8(2):118–122.
8. Rodgers BM, Harman PK, Johnson AM. Bronchopulmonary foregut malformations: the spectrum of anomalies. *Ann Surg* 1986;203(5):517–524.
9. O'Sullivan BP, Frassica JJ, Rayder SM. Tracheal bronchus: a cause of prolonged atelectasis in intubated children. *Chest* 1998;113(2):537–540.
10. Owen RL, Cheney FW. Endotracheal intubation: a preventable complication. *Anesthesiology* 1987;67(2):255–257.
11. Ikeno S, Mitsuhashi H, Saito K, Hirabayashi Y, Akazawa S, Kasuda H, Shimizu R. Airway management for patients with a tracheal bronchus. *Br J Anaesth* 1996;76(4):573–575.
12. Sato M, Hasegawa S, Shoji T, Wada H. Treacheobronchoplasty for resection of lung cancer arising from a tracheal bronchus. *Ann Thorac Surg* 2002;73(1):310–312.



Bedside Teaching in Scholastic Times.
From *Hortus Sanitatis*, Mainz, 1485.