

## Right Paratracheal Air Cyst (Tracheal Diverticulum)

Ziaollah Haghi MD, Mohammad Towhidi MD, Hossein Fattahi MD, and Shahrzad M Lari MD

### Introduction

Paratracheal air cysts are collections of air adjacent to the trachea. These lesions are usually an incidental finding at routine chest computed tomography (CT) scan, and their frequency is probably underestimated, because almost all patients are asymptomatic.<sup>1</sup> Differential diagnosis of paratracheal air cysts includes tracheal diverticulum, pharyngocele, laryngocele, Zenker diverticulum, apical lung hernia, blebs and bulla, and pneumomediastinum.<sup>1-4</sup>

We present here a case of chronic obstructive pulmonary disease (COPD) with incidental finding of a large tracheal diverticulum.

### Case Report

A 72-year-old man presented with productive bloody cough and exertional dyspnea for 3 years. He was a farmer, and his past medical history was positive only for smoking. The physical examination was normal except for scattered rhonchi in both lungs. Routine laboratory tests were found normal. Pulmonary function tests revealed a moderate obstructive pattern, with no post-bronchodilator change. Chest radiography was normal. The chest high-resolution CT showed a thin-walled 20×30-mm air cyst in the medial aspect of the right upper lobe, adjacent to the trachea (Figs. 1 and 2). Fiberoptic bronchoscopy revealed a normal tracheobronchial tree, with no obvious orifices in the tracheal wall. But in 3-dimensional reconstruction CT there was a very small direct connection between the trachea and the paratracheal air cyst (Fig. 3).

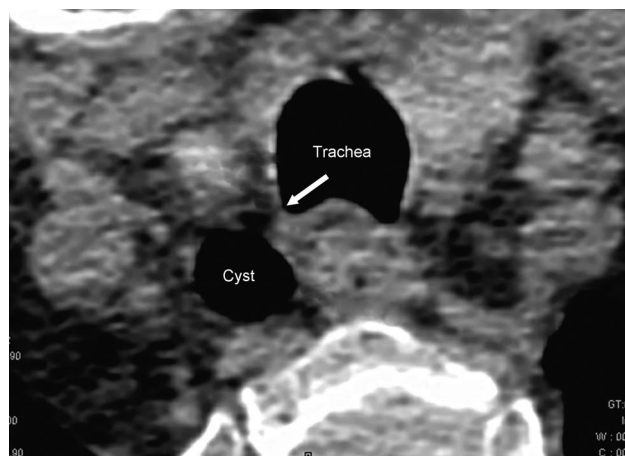


Fig. 1. Axial computed tomography scan of the upper thorax shows a thin-walled air cyst located posterior to and right of the trachea, with connection to the trachea (arrow).

Pharyngoesophagram was normal. The patient was discharged in good condition, with the diagnosis of tracheal diverticulum, and bronchodilator and mucolytic treatments. Twelve months later the patient was in a good condition and there was no change in the features of the tracheal diverticulum.

### Discussion

Paratracheal air cysts are commonly encountered in clinical practice, and were first described by Rokitansky in 1838.<sup>5</sup> Their frequency is reported to be 1–2% in autopsy and 0.3% in children.<sup>1,2,5,6</sup> They are usually incidental radiographic or CT findings.<sup>3</sup> The paratracheal air cyst is a collection of air in the paratracheal region. All these lesions are lined by ciliated columnar epithelium.<sup>2,7</sup> In the study by Goo et al on 65 patients with paratracheal air cysts, 98% of the lesions were located in the right paratracheal region, and there was a communicating channel between the cyst and the trachea in only 5 patients (8%).<sup>2</sup> The right-sided predominance of these lesions may be due to the supportive effect of the esophagus on the left side.<sup>2</sup> Paratracheal air cysts are usually asymptomatic, but sometimes compression of the trachea or infection of the cyst can occur.<sup>1,8</sup>

Ziaollah Haghi MD and Hossein Fattahi MD are affiliated with the Department of Thoracic Surgery, and Mohammad Towhidi MD and Shahrzad M Lari MD are affiliated with the Department of Lung Disease and the Tuberculosis Research Center, Mashhad University of Medical Sciences, Mashhad, Islamic Republic of Iran.

The authors have disclosed no conflicts of interest.

Correspondence: Shahrzad M Lari MD, Department of Pulmonary Diseases, Mashhad University of Medical Sciences, 2/99, Asrare-Gharbi, Koye-Doctora, Mashhad, Islamic Republic of Iran 91836-33871. E-mail: larish851@mums.ac.ir.

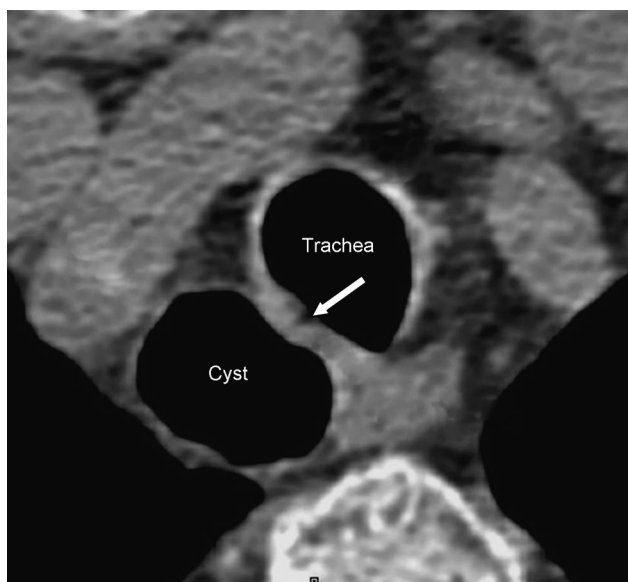


Fig. 2. Axial computed tomography scan of the thorax shows an air cyst in the right aspect of the trachea, with connection to the trachea (arrow).

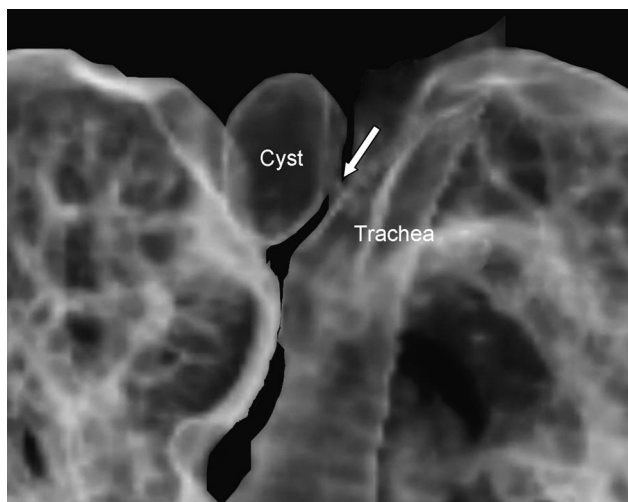


Fig. 3. Three-dimensional reconstructive computed tomography image shows a thin-wall cyst posterolateral to the trachea, with obvious connection with the trachea (arrow).

Tracheal diverticula are characterized by single or multiple outpouchings of the tracheal wall. A tracheal diverticulum resembles a laryngeal diverticulum, which is a more common disorder and may share the same pathogenic mechanism.<sup>8</sup> By strict definition, a diverticulum would have a communication (sometimes very small) with the trachea, and a cyst would not.

This abnormality can be divided into congenital and acquired forms. Congenital tracheal diverticula are very rare and thought to be due to malformed supernumerary branches of trachea.<sup>9</sup> The acquired form is thought to be

produced by bulging of a weak part in the tracheal wall, secondary to increased intraluminal pressure.<sup>9</sup> Coughing was the most common symptom in the Goo et al study, and they pointed out that not only did tracheal diverticula have an association with COPD, but it could also be a sign of COPD.<sup>1,2</sup> The hemoptysis of our patient could be due to COPD. Another mechanism that has been postulated for development of acquired tracheal diverticula is cystic distention of mucous gland ducts and the consequent enlargement of the ducts draining these glands.<sup>6</sup> Acquired tracheal diverticula may arise at any level, and are said to be larger than congenital types.<sup>10</sup> Cartilaginous rings in the wall of diverticula strongly suggest the congenital form, which do not occur in acquired diverticula.<sup>10</sup>

The other differential diagnoses of such a collection is laryngocele, pharyngocele, Zenker diverticulum, apical hernia of the lung, apical paraseptal blebs/bullae, and pneumomediastinum.<sup>1-4</sup> These lesions are ruled out by pharyngoesophagram, fiberoptic bronchoscopy, and chest CT scan. Unfortunately, our case was not pathologically proven, but the presence of a connection between the paratracheal air cyst and the trachea on 3-dimensional reconstruction chest CT scan and negative pharyngoesophagram limited our diagnosis to tracheal diverticulum. As Goo et al<sup>2</sup> mentioned, it can be hard to find an air cyst orifice of very small size on routine bronchoscopy. In other words, the best modality for diagnosis of tracheal diverticula is CT scan of the trachea and reconstruction with various angles in the coronal plane to visualize the communication of the cyst with the tracheal wall.<sup>9</sup> Tracheal diverticula are often found posterior to and slightly to the right of the trachea.<sup>10</sup> Particular sonographic findings of paratracheal air cyst have been reported.<sup>7</sup>

Treatment options are surgery in young patients or conservative medical treatment with bronchodilators, antibiotics, and physiotherapy in the elderly and debilitated patients.<sup>8,10,11</sup> As our patient was a 72-year-old man with COPD, he was advised to quit smoking and prescribed a standard treatment regimen for COPD.

### Teaching Points

The tracheal diverticulum is a kind of paratracheal air cyst that is usually an incidental finding. It may be congenital or acquired. The latter is more common. They are usually asymptomatic, but occasionally may cause compression-of-trachea symptoms. In addition, a tracheal diverticula can act as a reservoir for secretions, with secondary chronic infections, and may present clinically with chronic cough, dyspnea, stridor, and repeated episodes of tracheobronchitis. These lesions can sometimes be confused with pneumomediastinum, prompting an unnecessary and expensive workup. Diagnosis of this lesion may be made via CT scan and 3-dimensional reconstructions.

Treatment options are surgery in young patients and conservative management in the elderly.

**ACKNOWLEDGMENTS**

The authors wish to thank Ms Zahra S Masoumi, Department of Radiology, Razavi Hospital, Mashhad, Iran, for her valuable cooperation in providing the 3-dimensional computed tomography images.

**REFERENCES**

1. Mineshita M, Tajima O, Kondo T. Paratracheal air cysts in middle-aged Japanese men. *J Bronchol* 2006;13(1):6-8.
2. Goo JM, Im JG, Ahn JM, Moon WK, Chung JW, Park JH, et al. Right paratracheal air cysts in the thoracic inlet: clinical and radiologic significance. *AJR Am J Roentgenol* 1999;73(6):65-70.
3. Tanaka H, Mori Y, Kurokawa K, Abe S. Paratracheal air cysts communicating with the trachea: CT findings. *J Thorac Imaging* 1997;12(1):38-40.
4. Buterbaugh JE, Erly WK. Paratracheal air cysts: a common finding on routine CT examinations of the cervical spine and neck that may mimic pneumomediastinum in patients with traumatic injuries. *Am J Neuroradiol* 2008;29(1):1218-1221.
5. Soto-Hurtado EJ, Peñuela-Ruiz L, Rivera-Sánchez I, Torres-Jiménez J. Tracheal diverticulum: a review of the literature. *Lung* 2006;184(6):303-307.
6. MacKinnon D. Tracheal diverticula. *J Pathol Bacteriol* 1953;65(2):513-517.
7. Kim YJ, Kim EK, Kim J, Park CS. Paratracheal air cysts: sonographic findings in two cases. *Korean J Radiol* 2003;4(2):136-139.
8. Infante M, Mattavelli F, Valente M, Alloisio M, Preda F, Ravasi G. Tracheal diverticulum: a rare cause and consequence of chronic cough. *Eur J Surg* 1994;160(5):315-316.
9. Rahalkar MD, Lakhkar DL, Joshi SW, Gundawar S. Tracheal diverticula-report of 2 cases. *Indian J Radiol Imaging* 2004;14(2):197-198.
10. Waite S, Sharma A, Machnicki S. Right paratracheal air cyst/tracheal diverticulum. *Applied Radiology Online* 2003;32(8). <http://www.appliedradiology.com/cases/case.asp?id=410&subcatid=287&catid=29&threadid=>. Accessed August 9, 2009.
11. Caversaccio M, Becker M, Zbären P. Tracheal diverticulum presenting with recurrent laryngeal nerve paralysis. *Ann Otol Rhinol Laryngol* 1998;107(4):362-364.