Varicose Bronchiectasis and Bronchopulmonary Dysplasia

Don Hayes Jr MD, Vesna M Kriss MD, Joseph A Iocono MD, Brian J Dixon MD, Paul Bryan Collins RRT RPFT, and Hubert O Ballard MD

As a result of improved therapies and technology, including the use of surfactant replacement, the features of bronchopulmonary dysplasia (BPD) have changed, and a "new BPD" is emerging that is substantially different from the classical form of the disease. As the pathogenesis of BPD is evolving, so are other features of the disorder, including radiologic features. We describe varicose bronchiectasis with a bulbous appearance in a 6-year-old child with a complicated course including BPD during the neonatal period. *Key words: varicose, bronchiectasis, bronchopulmonary dysplasia, chronic lung disease of infancy.* [Respir Care 2009;54(11):1493–1495. © 2009 Daedalus Enterprises]

Introduction

Bronchopulmonary dysplasia (BPD) is the term used when an infant requires supplemental oxygen for at least 28 postnatal days[1] or at 36 weeks postmenstrual age.[2] In 2001 the National Institute of Child Health and Human Development (NICHD) workshop developed diagnostic criteria for BPD, which addressed gestational age and disease severity.[3] A study from the NICHD Neonatal Research Network demonstrated that the NICHD criteria accurately predicted pulmonary and neurodevelopmental outcomes in preterm infants < 32 weeks gestation, with severity defined by the NICHD: mild BPD is the need for oxygen for ≥ 28 days but not at 36 weeks postmenstrual age or discharge; moderate BPD is the need for oxygen for ≥ 28 days plus treatment with < 30% oxygen at 36 weeks postmenstrual age; and severe BPD is the need for oxygen for ≥ 28 days plus ≥ 30% oxygen and/or positive pressure at 36 weeks postmenstrual age.[4]

The typical support needed by these patients includes mechanical ventilation or noninvasive ventilation, oxygen, nutrition, and fluid balance. Medical therapy often includes bronchodilators, inhaled and systemic corticosteroids, and diuretics. Comorbidities of BPD can include pneumonia and other infections, as well as pulmonary hypertension, so optimal treatment is needed for any coexisting condition. Despite important obstetric and neonatal advancements in treatment and technology, BPD remains a factor in premature infants, especially those born with very low birth weight, as defined by ≤ 1,500 g.[5] With therapeutic improvements the characteristics of BPD are changing and, thus, the term "new BPD" is now being used. The more "classic BPD" was described in infants with severe respiratory distress syndrome who received aggressive mechanical ventilation with high positive airway pressure and inspired oxygen concentration. The new BPD, as it is termed, is seen in smaller preterm infants who have received antenatal steroids and postnatal surfactant therapy. The classical BPD clinical picture that resulted from tissue damage and scarring is becoming less common, and new BPD is emerging and is characterized by large, irregularly formed sacculi and alveoli, with septation only just beginning, and poor vascularization. As the pathophysiology and treatment of BPD is evolving, radiographic features of the disease are also changing.

The involvement of genetic variations or polymorphisms in the pathogenesis of BPD will be recognized in the future. The genetic predispositions for the development of

Don Hayes Jr MD is affiliated with the Departments of Pediatrics and Internal Medicine; Joseph A Iocono MD is affiliated with the Department of Surgery; Brian J Dixon MD is affiliated with the Departments of Pediatrics and Psychiatry; and Hubert O Ballard MD is affiliated with the Department of Pediatrics, University of Kentucky College of Medicine, Lexington, Kentucky. Paul Bryan Collins RRT RPFT is affiliated with the Pulmonary Function Laboratory, University of Kentucky Medical Center, Lexington, Kentucky. At the time of this study Vesna M Kriss MD was affiliated with the Department of Pediatrics, University of Kentucky College of Medicine, Lexington, Kentucky. She is now affiliated with the Department of Radiology, Kosair Children's Hospital, Norton Healthcare System, Louisville, Kentucky.

Correspondence: Don Hayes Jr MD, Department of Pediatrics, University of Kentucky College of Medicine, J410 Kentucky Clinic, 740 South Limestone Street, Lexington KY 40536-0284. E-mail: don.hayes@uky.edu.

BPD have been identified in regards to antioxidant defenses, including less efficient isoforms of glutathione-S-transferase-P1 and surfactant proteins, including both SP-B intron 4 variant allele 5 and SP-A 6A6 polymorphism.[2,6-9] The medical literature in relation to genetic polymorphisms and their role in BPD is quickly expanding. Due to the interference from genetic and environment factors, an association study of polymorphism is better examined with case-control studies, to avoid the confounding factors due to the multifactorial etiology of BPD.

Case Report

A 6-year-old male child who was a former 26-week premature infant with BPD presented for evaluation of worsening dyspnea related to physical activity. There were no symptoms of chronic cough, sputum production, hemoptysis, or wheezing. His medical history included a 3-month hospitalization in the neonatal intensive care unit, with the need for pressure-limited mechanical ventilation for 38 days, and then supplemental oxygen until 6 months of age. A patent ductus arteriosus was closed surgically after medical treatment with indomethacin was unsuccessful. Neither tracheal stenosis nor tracheomalacia was diagnosed during his neonatal course. His remaining course was unremarkable except for the clinical diagnosis of viral-induced asthma at 2 years of age. His asthma symptoms were well controlled, with no previous need for systemic corticosteroids. There was no history of pneumonia, tuberculosis, nontuberculous mycobacteria, *Aspergillus fumigatus*, measles, pertussis, respiratory syncytial virus, or adenovirus infection. His medications included montelukast 4-mg chewable tablet orally once daily and 2 aerosols via nebulization: budesonide 0.5 mg twice daily and albuterol as needed. His only need for antibiotics after discharge from the neonatal intensive care unit was at 9 and 11 months of age, for otitis media.

Previous chest radiographs that were not available revealed chronic left-upper-lobe changes, as reported by the family. A high-resolution chest tomography (HRCT) of the chest (Fig. 1) was obtained and found left-upper-lobe varicose bronchiectasis. A clinical evaluation to rule out other etiologies of bronchiectasis revealed normal immunoglobulin and alpha-1 antitrypsin levels, normal sweat chloride test (3 mEq/L), normal respiratory ciliary function on nasal septal biopsy, and no evidence of gastroesophageal reflux or aspiration via barium swallow and pH probe. His medications were continued, and airway clearance with vibratory PEP (Acapella, Smiths Medical, United Kingdom) with albuterol via nebulization twice daily was started. His dyspnea had resolved at follow-up at 3 months, with normal spirometry measurements.

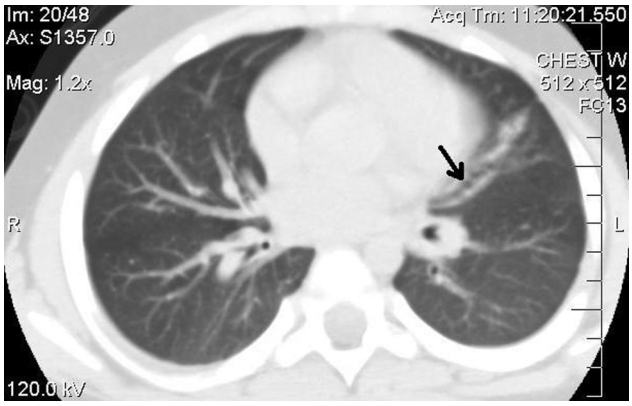

Fig. 1. Computed tomography scan of the chest, demonstrating a focal area of varicose bronchiectasis (black arrow) in the left upper lobe.

Discussion

This case illustrates focal varicose bronchiectasis in an early school-age child with BPD.

The medical literature does not define bronchiectasis as a complication of new or classical BPD in early childhood. Li and colleagues reviewed 2 tertiary pediatric respiratory units to assess the etiology of non-cystic-fibrosis bronchiectasis as determined by HRCT imaging.[10] A total of 136 patients were identified (65 males, median age 12.1 y, age range 3.1–18.1 y) with immunodeficiency, aspiration, and primary ciliary dyskinesia accounting for 67% of the cases, with no cases of BPD observed in the cohort.[10] Table 1 lists the reported etiologies of bronchiectasis unrelated to cystic fibrosis that can occur in children. Bronchiectasis was not identified in a retrospective review of computed tomography scans performed in 41 very-low-birth-weight infants with BPD between the ages of 10.6 months and 20.2 months of age.[11] In still yet another study, bronchiectasis was not detected in 23 children with BPD in a cohort 2 months to 13 years of age.[12]

Aukland et al evaluated a scoring system for HRCT scan for radiographic findings in young people born at a gestational age of $\leq$ 28 weeks or with a birth weight of $\leq$ 1,000 g, within a defined region in western Norway, from 1982 to 1985 ($n = 40$) or from 1991 to 1992 ($n = 32$).[13] A total of 56 of the 72 children (78%) had a clinical diagnosis of BPD in the neonatal period.[13] A total of 63 (88%) of the subjects had abnormal lung findings, with the most common being linear opacities ($n = 52$), triangular opacities ($n = 42$), air trapping ($n = 19$), and mosaic perfusion ($n = 10$), with right and left lungs being equally affected.[13] There were fewer abnormalities in the younger age group who were born in 1991-1992.[13] In this cohort, HRCT in young people with history of preterm birth

Table 1. Non-Cystic-Fibrosis Etiologies of Bronchiectasis in Children

Allergic bronchopulmonary aspergillosis
Alpha-1 antitrysin deficiency
Aspiration
Autoimmune diseases and idiopathic inflammatory disorders
Rheumatoid arthritis
Sjögren syndrome
Ankylosing spondylitis
Systematic lupus erythematosus
Relapsing polychondritis
Inflammatory bowel disease (ulcerative colitis and Crohn's disease).
Sarcoidosis
Bronchial obstruction
Focal post-obstruction (eg, endobronchial tumors, broncholithiasis, bronchial stenosis from infections, encroachment of hilar lymph nodes, foreign-body aspiration)
Right-middle-lobe syndrome
Childhood respiratory infections
Bacterial infections, including *Klebsiella* species, Haemophilus species, Pseudomonas species, *Staphylococcus aureus*, *Mycoplasma pneumoniae*, *Mycobacterium tuberculosis*, and nontuberculous mycobacteria
Viral infections, including adenovirus, influenza virus, herpes simplex virus, measles virus, pertussis virus, and respiratory syncytial virus
Congenital anatomic defects and connective-tissue disorders
Bronchomalacia
Bronchial atresia with bronchocele
Bronchopulmonary sequestration
Congenital lobar emphysema
Pulmonary artery sling
Williams-Campbell syndrome
Mounier-Kuhn syndrome or tracheobronchomegaly
Swyer-James syndrome
Yellow-nail syndrome
Marfan syndrome
Idiopathic
Immunodeficiency states
Combined variable immunodeficiency
Undefined combined immunodeficiency
X-linked agammaglobulinemia
Panhypogammaglobulinemia
Primary immune defects
Secondary immune defects (post-chemotherapy)
Acquired immune deficiency syndrome (AIDS)
Hyperimmunoglobulin E (IgE) syndrome
Qualitative antibody deficiency
Immunoglobulin G deficiency
B-cell deficiency
Major histocompatibility complex (MHC) class-2 deficiency
Chronic mucocutaneous candidiasis
Chronic granulomatous disease
Wiskott-Aldrich syndrome
Mannose-binding protein deficiency
Lung inhalation injury or toxic gas exposure
Primary ciliary dyskinesia
Young syndrome

revealed abnormal radiographic findings in 81.3% of the patients at age 10 years and 92.5% at age 18 years.[13]

In conclusion, non-cystic-fibrosis bronchiectasis is uncommon in children, and HRCT of the chest is needed to accurately diagnose it. BPD is typically not associated with bronchiectasis; however, this case demonstrates the development of varicose bronchiectasis in a young child with no other identifiable cause. We conclude that periodic HCRT may be needed to determine the development of bronchiectasis in patients with new BPD, especially if there are persistent abnormalities on plain radiographs in the setting of clinical deterioration.

REFERENCES

1. Kraybill EN, Runyan DK, Bose CL, Khan JH. Risk factors for chronic lung disease in infants with birth weights of 751 to 1000 grams. J Pediatr 1989;115(1):115-120.
2. Shennan AT, Dunn MS, Ohlsson A, Lennox K, Hoskins EM. Abnormal pulmonary outcomes in premature infants: prediction from oxygen requirement in the neonatal period. Pediatrics 1988;82(4):527-532.
3. Jobe AH, Bancalari E. Bronchopulmonary dysplasia. Am J Respir Crit Care Med 2001;163(7):1723-1729.
4. Ehrenkranz RA, Walsh MC, Vohr BR, Jobe AH, Wright LL, Fanaroff AA, et al. Validation of the National Institutes of Health consensus definition of bronchopulmonary dysplasia. Pediatrics 2005;116(6):1353-1360.
5. Fanaroff AA, Hack M, Walsh MC. The NICHD neonatal research network: changes in practice and outcomes during the first 15 years. Semin Perinatol 2003;27(4):281-287.
6. Manar MH, Brown MR, Gauthier TW, Brown LA. Association of glutathione-S-transferase-P1 (GST-P1) polymorphisms with bronchopulmonary dysplasia. J Perinatol 2004;24(1):30-35.
7. Makri V, Hospes B, Stoll-Becker S, Borkhardt A, Gortner L. Polymorphisms of surfactant protein B encoding gene: modifiers of the course of neonatal respiratory distress syndrome? Eur J Pediatr 2002;161(11):604-608.
8. Rova M, Haataja R, Marttila R, Ollikainen V, Tammela O, Hallman M. Data mining and multiparameter analysis of lung surfactant protein genes in bronchopulmonary dysplasia. Hum Mol Genet 2004;13(11):1095-1104.
9. Weber B, Borkhardt A, Stoll-Becker S, Reiss I, Gortner L. Polymorphisms of surfactant protein A genes and the risk of bronchopulmonary dysplasia in preterm infants. Turk J Pediatr 2000;42(3):181-185.
10. Li AM, Sonnappa S, Lex C, Wong E, Zacharasiewicz A, Bush A, Jaffe A. Non- CF bronchiectasis: does knowing the aetiology lead to changes in management? Eur Respir J 2005;26(1):8-14.
11. Mahut B, De Blic J, Emond S, Benoist MR, Jarreau PH, Lacaze-Masmonteil T, et al. Chest computed tomography findings in bronchopulmonary dysplasia and correlation with lung function. Arch Dis Child Fetal Neonatal Ed 2007;92(6):F459-F464.
12. Oppenheim C, Mamou-Mani T, Sayegh N, de Blic J, Scheinmann P, Lallemand D. Bronchopulmonary dysplasia: value of CT in identifying pulmonary sequelae. AJR Am J Roentgenol 1994;163(1):169-172.
13. Aukland SM, Halvorsen T, Fosse KR, Daltveit AK, Rosendahl K. High-resolution CT of the chest in children and young adults who were born prematurely: findings in a population-based study. AJR Am J Roentgenol 2006;187(4):1012-1018.