

An Unusual Case of Pulmonary Embolism

Dercio Mendonca MD, Davi Sa Leita MD, Rahsaan Friend DO,
Joyce Epelboim MD, and Glenn Eiger MD

Introduction

Silicone pulmonary embolism is an unusual complication of cosmetic silicone injection. An accurate history is essential in considering this diagnosis. Bronchoscopy with transbronchial biopsy can provide confirmatory pathologic findings. We report a classic case of silicone pulmonary embolism in a transsexual patient.

Case Summary

A 51-year-old African American female presented to the emergency department with shortness of breath, non-productive cough, pleuritic chest pain, fever, and chills. The symptoms began 2 days prior to presentation and had become progressively worse.

The patient had a history of type 2 diabetes mellitus, hypertension, and hepatitis C diagnosed 1 year ago. She had breast silicone implants placed 5 years ago. Her social history revealed occasional alcohol consumption and a few cigarettes daily for 20 years. She had no history of recent travel, and review of systems was otherwise unremarkable.

On physical examination the patient was febrile, at 38.8°C, with a blood pressure of 160/82 mm Hg, heart rate of 105 beats/min, and respiratory rate of 26 breaths/min. Oxygen saturation was 89% on room air, and 95% on supplemental oxygen at 2 L/min. The patient was comfortable while resting in bed, but became short of breath when she tried to speak in complete sentences. No rash or lymphadenopathy was noted. The jugular venous pressure was normal. Coarse crackles were heard in both lower lung fields, and the heart sounds were normal. Abdominal

exam was benign. She refused examination of her genitalia. There was no peripheral edema, tenderness of the calves, or digital clubbing. The neurologic examination was unremarkable. Complete blood count, including differential, serum chemistry and liver function tests, was normal. A chest x-ray showed bilateral air space disease in a peripheral pattern (Fig. 1). The diagnosis of community-acquired pneumonia was entertained, and the patient was started on ceftriaxone and azithromycin.

A few hours after admission she became more tachycardic and her oxygen requirement increased. A contrast enhanced chest computed tomography angiography showed mixed interstitial and alveolar densities along the dependent, peripheral regions of the lungs (Fig. 2). There was no pulmonary thromboembolism seen.

The differential diagnosis included pneumocystis pneumonia, bacterial pneumonia, Loeffler syndrome, chronic eosinophilic pneumonia, alveolar hemorrhage, or cryptogenic organizing pneumonia. Test for human immunodeficiency virus was negative, and sputum Gram-stain and culture revealed normal flora.

A bronchoscopy with bronchoalveolar lavage showed numerous macrophages, some with cytoplasmic vacuoles and abundant blood. No bacteria, pneumocystis, or fungal forms were noted, making infection unlikely. A transbronchial biopsy revealed vacuolated deposits felt to be consistent with silicone embolism (Fig. 3).

After extensive conversation with the patient, she admitted to using cosmetic silicone injections in the past. Her last buttock injection was approximately 2 weeks prior to admission. The patient also revealed that she was transgender and underwent orchiectomy in the distant past and was on hormonal therapy. She had not yet completed the entire sex change procedure.

The patient was managed with intravenous solumedrol and transitioned to an oral prednisone taper, along with oxygen supplementation. She had an excellent clinical response.

Discussion

Silicone has been used for many years to enhance body shape and contour. Its use by illegal practitioners persists,

The authors are affiliated with the Department of Medicine, Albert Einstein Medical Center, Philadelphia, Pennsylvania.

The authors have disclosed no conflicts of interest.

Correspondence: Dercio Mendonca MD, Department of Medicine, Albert Einstein Medical Center, 5501 Old York Road, Philadelphia PA 19141. E-mail: dercioam@hotmail.com.

DOI: 10.4187/respcare.01555

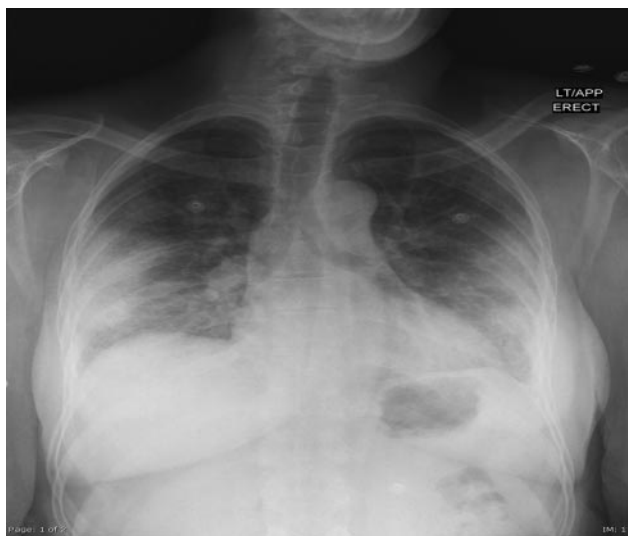

Fig. 1. Chest x-ray showing bilateral peripheral air-space disease.

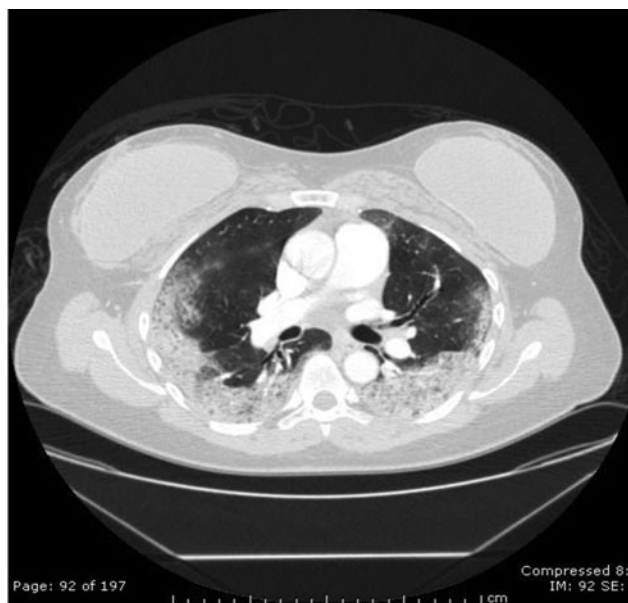


Fig. 2. Computed tomography chest showing mixed interstitial and alveolar densities along the dependent and peripheral region of the lungs, with sparing of the central regions.

especially among some groups in the United States, such as exotic entertainers, prostitutes, and transsexual individuals.¹ Complications of silicone injections are believed to be in the range of 1–2%, including that of silicone embolism to the lungs.²

Complications of silicone fluid injections have been reported dating back to 1975; cases of granulomatous hepatitis and pulmonary hemorrhage have been described. In addition, in 1983 silicone was detected in cells obtained from bronchoalveolar lavage by the use of spectrophotometry in patients presenting with acute pneumonitis.² Lung

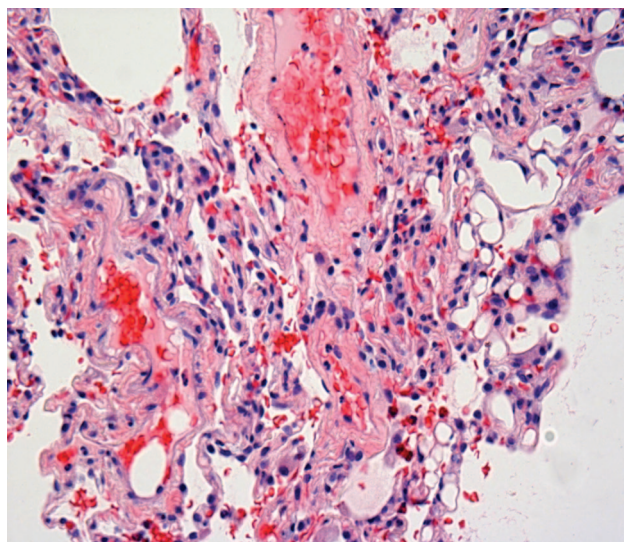


Fig. 3. The hematoxylin-eosin stain of a transbronchial biopsy specimen from the left lower lobes shows foci of intra-alveolar hemorrhage, with fibrin, focal thickening of alveolar walls due to inflammatory infiltrates, and prominent type II pneumocytes. In the interstitial capillaries, vacuolated globular deposits of silicone were found.

damage from silicone injection has been described in the literature as silicone emboli, alveolar hemorrhages, and diffuse alveolar damage (acute pneumonitis).^{3,4}

In the silicone embolism syndrome, hypoxia (92%), dyspnea (88%), fever (70%), alveolar hemorrhage (64%), and cough (52%) are the most prevalent clinical findings, which are similar to that of fat embolism syndrome. Moreover, both entities might share similar pathophysiology, in that ingestion by alveolar macrophages of silicone could then trigger an inflammatory response, ultimately causing lung injury.⁵

There are mainly 2 distinctive clinical presentations; one is characterized predominantly by pulmonary involvement (82%), with a mortality rate of 24%, and the other one by neurologic toxicity (18%), where the course is often fatal.⁵

Most cases tend to present in the first 48 hours of silicone injection. However, in a few cases, patients can present months after the last injection (range of 6–13 months). These patients show mild respiratory symptoms.⁶ Our patient reportedly presented 2 weeks after the injection of silicone, though the accuracy of the history was questionable.

The pathogenesis of pulmonary disease caused by silicone is not yet clearly elucidated; however, it is strongly believed to be related to embolization of the silicone, and therefore the mechanism is suspected to be largely similar to that of pulmonary fat embolism.⁵ There have also been reports of the formation of antibodies to silicone, and thus an immunologic mechanism may have a role.^{3,7}

Computed tomography scan in this entity most often shows peripherally distributed ground-glass opacities associated with interlobular septal thickening, similar to what can be observed in some eosinophilic lung diseases and fat embolism syndrome.²

In the cases of illegal practice of silicone injection, the mechanism of pulmonary silicone embolism may occur in a number of ways, such as excessive local tissue pressure induced by large dose and high pressure injection, local massage by the illegal practitioner, migration effect, or direct intravascular injections. It has already been documented that injection of large volumes of silicone directly into the body tissues may result in local tissue damage; the silicone eventually gains access to the bloodstream and results in embolization to the lungs.^{1,3} The few days' delay of symptoms after injection into the tissue (as shown in this case) favors this pathway rather than intravascular administration, which would have resulted in immediate embolization and symptoms. In this case the amount of fluid injected was reported by our patient to be greater than what she usually had.

A case series published in 2009 by Zamora et al showed that patients had a good response to steroids, compounding the idea that an immune-mediated response to the injected silicone might play a role in its pathophysiology.⁸ Moreover, other reports also show a favorable response with the use of steroids in the treatment of these patients.^{3,9} However, there is no consensus regarding the use of steroids yet.

Teaching Points

- The diagnosis of silicone embolism should be suspected after the development of respiratory distress in a patient

who has undergone a cosmetic procedure with silicone injections.

- Radiographically, it can look similar to other pulmonary disorders; therefore, a high index of suspicion is needed for the diagnosis.

REFERENCES

1. Price EA, Schueler H, Perper JA. Massive systemic silicone embolism: a case report and review of literature. *Am J Forensic Med Pathol* 2006;27(2):97-102.
2. Restrepo CS, Artunduaga M, Carrillo JA, Rivera AL, Ojeda P, Martinez-Jimenez S, et al. Silicone pulmonary embolism: report of 10 cases and review of literature. *J Comput Assist Tomogr* 2009; 33(2):233-237.
3. Chung KY, Kim SH, Kwon IH, Choi YS, Noh TW, Kwon TJ, Shin DH. Clinicopathologic review of pulmonary silicone syndrome embolism with special emphasis on the resultant histologic diversity in the lung: a review of five cases. *Yonsei Med J* 2002;43(2):152-159.
4. Parikh R, Karim K, Parikh N, Han P, Daoko J, Shamoon FE. Acute pneumonitis and alveolar hemorrhage after subcutaneous injections of liquid silicone. *Ann Clin Lab Sci* 2008;38(4):380-385.
5. Smith A, Tzur A, Leshko L, Krieger BP. Silicone embolism syndrome: a case report, review of literature and comparison with fat embolism syndrome. *Chest* 2005;127(6):2276-2281.
6. Chastre J, Brun P, Soler P, Basset F, Trouillet JL, Fagon JY, et al. Acute and latent pneumonitis after subcutaneous injections of silicone in transsexual man. *Am Rev Respir Dis* 1987;135(1):236-240.
7. Bartsich S, Wu JK. Silicone emboli syndrome: a sequel of clandestine silicone injections. A case report and review of literature. *J Plast Reconstr Aesthet Surg* 2010;63(1):e1-e3.
8. Zamora AC, Collard HR, Barrera L, Mendoza F, Webb WR, Carrillo G. Silicone injection causing acute pneumonitis: a case series. *Lung* 2009;187(4):241-244.
9. Clark RF, Cantrell FL, Pacal A, Chen W, Betten DP. Subcutaneous silicone injections leading to multi-system organ failure. *Clin Toxicol (Phila)* 2008;46(9):834-837.