RESPIRATORY CARE Paper in Press. Published on June 12, 2013 as DOI: 10.4187/respcare.02150

Necrotizing Tracheitis secondary to Corynebacterium species presenting with Central Airway Obstruction

Jorge Guerrero, MD [1], Pavan Mallur, MD[2], Erik Folch, MD, MSc[1], Colleen Keyes, MD, MPH[1], Isaac E Stillman MD[3], Sidhu P. Gangadharan, MD[1], Adnan Majid, MD, FCCP[1]

1. Division of Thoracic Surgery and Interventional Pulmonology, Beth Israel Deaconess Medical Center, Harvard Medical School, Boston, MA.
2. Department of Otolaryngology*, Beth Israel Deaconess Medical Center, Harvard Medical School, Boston, MA
3. Department of Pathology, Beth Israel Deaconess Medical Center, Harvard Medical School, Boston, MA

Corresponding author:
Adnan Majid, MD, FCCP
Director, Interventional Pulmonology,
Division of Thoracic Surgery and Interventional Pulmonology,
Beth Israel Deaconess Medical Center,
Assistant Professor of Medicine,
Harvard Medical School,
185 Pilgrim Road, Deaconess-201
Boston, MA 02215
Phone: (617) 632-8060
Fax: (617) 632-8253
amajid@bidmc.harvard.edu

No funding was used. The authors have no conflict of interest related to this publication

RESPIRATORY CARE Paper in Press. Published on June 12, 2013 as DOI: 10.4187/respcare.02150

ABSTRACT

Pseudomembranous necrotizing tracheitis is a rare cause of life threatening central airway obstruction (CAO). Patients present with hoarseness, cough, dyspnea, wheezing, stridor and occasionally with respiratory failure. Diagnosis requires high index of suspicion and should be confirmed with a comprehensive bronchoscopic examination and biopsy. For patients with signs and symptoms of airway obstruction, a therapeutic rigid bronchoscopy with mechanical debridement is recommended. We present a rare case of necrotizing tracheitis secondary to Corynebacterium species causing life threatening airway obstruction in an adult.

Key Words: Central Airway Obstruction, Necrotizing Tracheitis, Rigid Bronchoscopy.

INTRODUCTION:

Pseudomembranous necrotizing tracheitis is a rare cause of life threatening central airway obstruction (CAO). Pseudomembrane airway disease is due to either an infectious or non-infectious process. The most common infectious etiologies include: *Corynebacterium diphtheria*, *Corynebacterium pseudodiphtheriticum*, *Staphylococcus aureus*, *Bacillus cereus*, *Aspergillus* species and *Haemophilus influenza* (1-7). Among the non-infectious etiologies, endotracheal intubation is the most common (8). Other reported etiologies include: smoke inhalation, Stevens - Johnson syndrome, Paraquat ingestion and autoimmune disorders like Crohn's disease (9-12). Patients will present with hoarseness, cough, dyspnea, wheezes, stridor and occasionally respiratory failure. Diagnosis requires a high index of suspicion and should be confirmed with a comprehensive bronchoscopic examination and biopsy. For patients with signs and symptoms of airway obstruction, a therapeutic rigid bronchoscopy with mechanical debridement is recommended. We present a rare case of necrotizing tracheitis secondary to Corynebacterium species causing life threatening airway obstruction in an adult.

RESPIRATORY CARE Paper in Press. Published on June 12, 2013 as DOI: 10.4187/respcare.02150

CASE SUMMARY:

A thirty-nine year-old woman with morbid obesity, diabetes mellitus, coronary artery disease and Crohn's disease presented with acute shortness of breath and stridor five weeks after coronary artery bypass surgery. Her postoperative course was complicated with postpericardiotomy syndrome (Dressler's syndrome) and was treated with Dexamethasone 4mg intravenously every 8 hours for a period of at least 10 days. Her shortness of breath progressed to stridor in a matter of hours. Computed tomography images from the upper chest showed severe tracheal narrowing with an airway lumen of 4mm (Figure 1). The patient was bridged with Heliox 70/30 and emergently underwent rigid bronchoscopy. Endoscopic examination revealed a grossly estimated 95% obstruction of the proximal trachea mainly due to the formation of a pseudomembrane. Mechanical debridement uncovered an area of severe tracheal inflammation with multiple mucosal plaque-like lesions suggestive of an infectious etiology (Figure 2). Pathological examination revealed extensively necrotic soft tissue, cartilage and bone with acute and chronic inflammation and bacterial overgrowth (Figure 3a). Tissue Gram stain revealed numerous Gram-positive rods (Figure 3b). Biopsies grew Corynebacterium species sensitive to clindamycin. She was discharged with a two-week course of antibiotic and close follow-up in the outpatient clinic. Unfortunately, patient did not return to her follow up visit and three weeks later, presented with acute dyspnea, stridor and required emergent intubation with a size 5.0 endotracheal tube. Flexible bronchoscopy was attempted in an effort to bronchoscopically advance the endotracheal tube past area of tracheal stenosis, but this was unsuccessful given the reduced diameter of the airway. The patient was taken to the operating room emergently for rigid bronchoscopy and was started on Imipenem and Vancomycin to treat her recurrent infection. Endoscopic exam showed critical airway obstruction due to complex tracheal stenosis, which started at 1.8cm from the vocal cords and extended 4cm in length. Dilatation with the rigid bronchoscope barrel was performed to 10 mm with suboptimal response, and the decision was to perform a percutaneous dilatation tracheostomy during the same case guided by rigid bronchoscopy. After the procedure, the patient was admitted to the medical floor for observation and was discharged at 72hrs with scheduled follow up in 2 weeks.

Eight days later, the patient was readmitted with sudden dyspnea secondary to mucus plugging of the tracheostomy tube. A repeat flexible bronchoscopy showed complete airway obstruction from progressive granulation tissue formation at the proximal trachea right above the stoma (Figure 4). The tracheostomy tube was left in place and the

RESPIRATORY CARE Paper in Press. Published on June 12, 2013 as DOI: 10.4187/respcare.02150

DISCUSSION:

Corynebacterium is an aerobic gram-positive bacillus widely distributed in nature and is mostly innocuous. Although it can be an airway colonizer in the immunocompetent patient, it is known to cause a severe form of pseudomembranous necrotizing tracheitis in the immunocompromised host (3). Risk factors that have been identified based on the few case reports published in the literature include diabetes mellitus, immunosuppression, chronic obstructive pulmonary disease, congestive heart failure and underlying malignancy (1-5). The diagnosis of Corynebacterium infectious tracheitis should be confirmed with a comprehensive bronchoscopic examination and biopsy.

Specific antibiotic therapy is warranted once the organism is isolated. One study evaluating the Minimum Inhibitory Concentrations (MICs) for antibiotics revealed that Corynebacterium pseudodiphtheriticum isolates are susceptible to ampicillin, amoxicillin/clavulanic acid, cefazolin, cefuroxime, ceftazidime, and imipenem (1). Another study showed that it is susceptible to beta-lactam antibiotics, clindamycin, vancomycin and trimethoprim-Sulfamethoxazole (2). Given the possibility of resistance to antibiotic monotherapy, especially in patients with severe airway involvement, antibiotic combination to achieve synergy would be reasonable to avoid relapse and further complications as seen with our patient. Ultimately the recommendations for choice of antibiotic should be based on organism specific sensitivities and patient characteristics including renal function, allergies, and cross reactivity with other medications.

Alternate etiologies for this presentation should be considered as described previously. Central airway obstruction due to Crohn's disease is of particular concern given the patient's prior medical history. However, Crohn's disease in the airway is typically responsive to steroids or may happen after steroids are withdrawn (12). Our patient was on high doses of Dexamethasone prior and during her presentation. Furthermore, given the rapid onset of symptoms, it makes it less likely for Crohn's disease to be the underlying etiology and makes an infection a more plausible cause.

airway surgeon was consulted. The patient underwent tracheal resection and reconstruction restoring complete patency to the airway and no longer requires a tracheostomy tube.

In addition to antibiotic therapy for Corynebacterium tracheitis, patients with signs and symptoms of central airway obstruction need immediate bronchoscopic intervention in order to restore airway patency. Furthermore, whenever feasible, patients should be weaned off immunosuppressive medications and other underlying conditions like diabetes need to be aggressively controlled. In patients with evidence of severe tracheitis, we suggest early

bronchoscopic follow up within the first week after the initial intervention given the concern of early scar formation and recurrent airway obstruction as seen with the case presented here. In patients with recurrent airway obstruction, therapeutic options include placement of a tracheostomy tube, Montgomery T-Tube or an airway stent. For patients who present in respiratory failure, as in our case, a tracheostomy tube is the best option since it allows ‘ for positive pressure ventilation and serves as a conduit for suctioning inflammatory debri. These prosthesis can be used either as a bridge to surgical intervention or permanent in patients deemed not to be surgical candidates. Due to the need for complex endoscopic multimodality therapy and the potential for complications, these cases are best managed at a center of excellence where an interventional pulmonologist, a laryngologist and a thoracic surgeon are available.

REFERENCES

1. Ahmed K, Kawakami K, Watanabe K, Mitsushima H, Nagatake T, Matsumoto K. Corynebacterium pseudodiphtheriticum pathogen: A respiratory tract pathogen. Clin Infect Dis. 1995 Jan; 20(1) : 41-46.

2. Craig TJ, Maguire FE, Wallace MR. Tracheobronchitis due to Corynebacterium pseudodiphtheriticum. South Med J. 1991 Apr; 84(4): 504-506.

3. Colt HG, Morris JF, Marston BJ, Sewell DL. Necrotizing Tracheitis caused by Corynebacterium pseudodiphtheriticum: Unique case and review. Rev Infect Dis. 1991 Jan-Feb;13(1): 73-76.

4. Hadfield TL, McEvoy P, Polotsky Y, Tzinserling V, Yaklovev A. The pathology of diphtheria. J Infect Dis 2000 Feb; 181 Suppl 1: S116-120.

5. Yamazi Y, Hirai K, Honda T. Pseudomembranous tracheobronchitis caused by methicillin resistant Staphylococcus aureus. Scand J Infect Dis. 2002; 34(3):211-213.

6. Machida U, Kami M, Kanda Y, Takeuchi K, Akahane M, Yamaguchi I, et al. Aspergillus tracheobronchitis after allogenic bone marrow transplantation. Bone Marrow Transplant. 1999 Nov; 24(10):1145-1149.

7. Strauss R, Mueller A, Wehler M, Neureiter D, Fischer E, Gramatzki M, et al. Pseudomembranous Tracheobronchitis due to Bacillus cereus. Clin Infect Dis. 2001 Sep 1; 33(5): E39-41.

8. Deslee G, Brichet A, Lebuffe G, Copin MC, Ramon P, Marquette CH. Obstructive fibrinous tracheal pseudomembrane. A potential fatal complication of tracheal intubation. Am J Respir Crit Care Med 2000 Sep; 162(3 Pt 1): 1169-1171.

9.Koch WM, McDonald GA. Stevens-Johnson Syndrome with subglottic laryngeal obstruction. Arch Otolaryngol Head Neck Surg. 1989 Nov; 115(11):1381-1383.

10. Hubbard GB, Langlinais PC, Shimazu T, Okerberg CV, Mason AD, Pruitt BA Jr. The morphology of smoke inhalation in sheep. J Trauma. 1991 Nov; 31(11): 1477-1486.

11. Stephens DS, Walker DH, Schaffner W, Kaplowitz LG, Brashear HR, Roberts R. Spickard WA Jr. Pseudodiphteria: Prominent pharyngeal membrane associated with fatal paraquat ingestion. Ann Intern Med 1981 Feb; 94(2):202-204.

12. Herny MT, Davidson LA, Cooke NJ. Tracheobronchial Involvement with Crohn's. European Journal of Gastroenteroloy and Hepatology. 2001; 13: 12; 1495-1497.

FIGURES:

Figure 1: Computed tomography of the chest shows severe tracheal stenosis with an airway lumen of 4mm.

Figure 2: Tracheal inflammation suggestive of an infectious etiology as seen from the subglottic area via rigid bronchoscopy.

Figure 3a: Extensive necrotic tissue with neutrophilic infiltrate and bacterial overgrowth.

Figures 3b: Tissue gram stain revealing numerous gram positive rods.

Figure 4: Complete central airway obstruction due to tracheal stenosis as seen from subglottic area via bronchoscopy.

RESPIRATORY CARE Paper in Press. Published on June 12, 2013 as DOI: 10.4187/respcare.02150

Computed tomography of the chest shows severe tracheal stenosis with an airway lumen of 4mm.
180x180mm (72 x 72 DPI)

RESPIRATORY CARE Paper in Press. Published on June 12, 2013 as DOI: 10.4187/respcare.02150

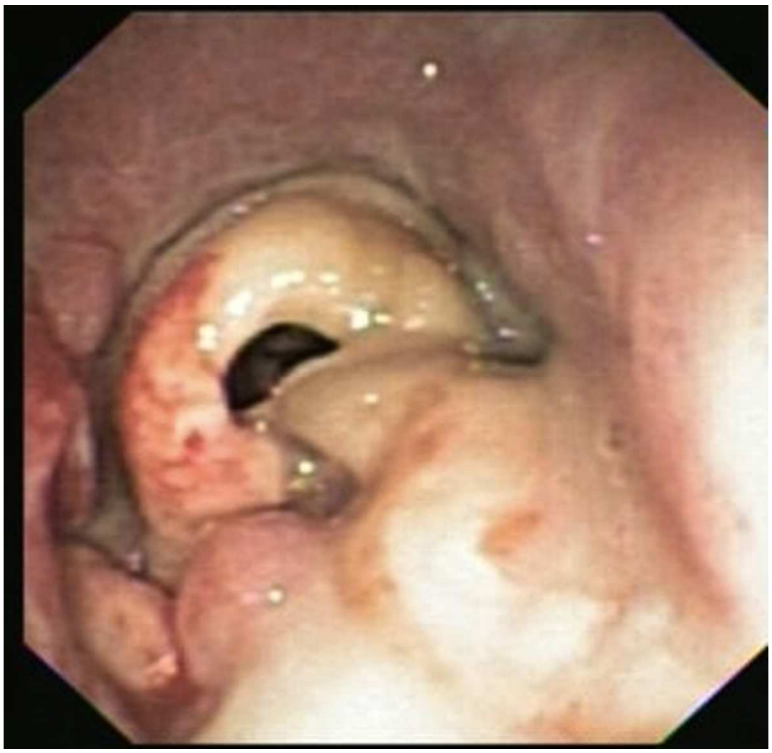

Tracheal inflammation suggestive of an infectious etiology as seen from the subglottic area via rigid bronchoscopy.
134x130mm (72 x 72 DPI)

RESPIRATORY CARE Paper in Press. Published on June 12, 2013 as DOI: 10.4187/respcare.02150

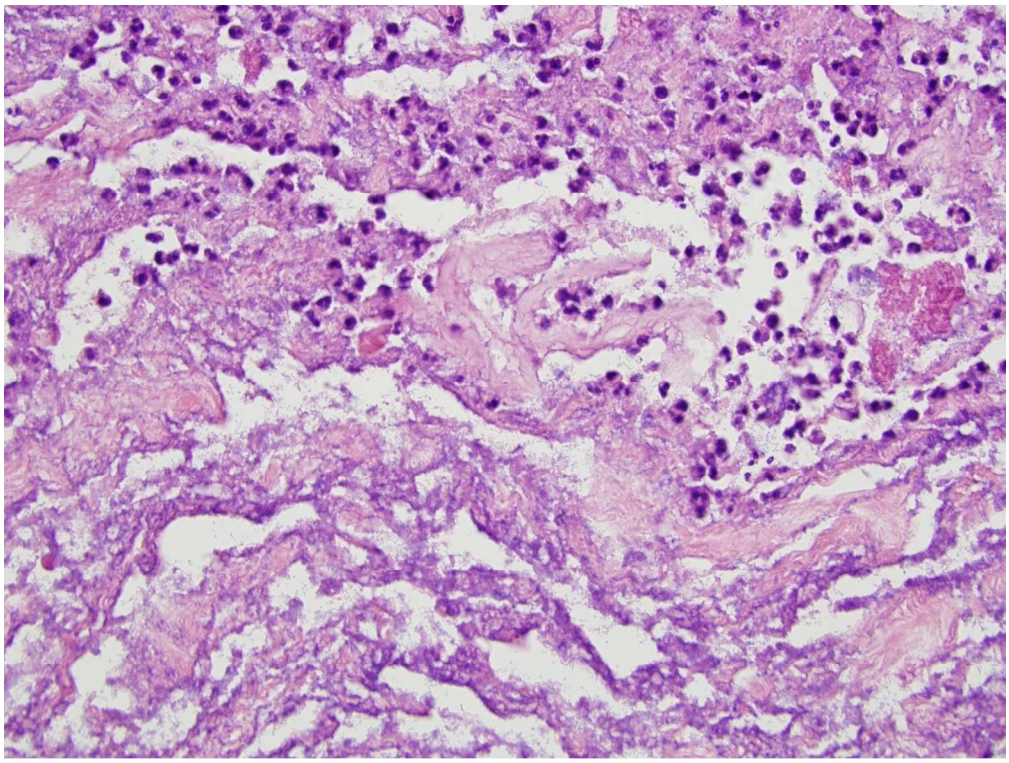

Extensive necrotic tissue with neutrophilic infiltrate and bacterial overgrowth. (H&E Original Magnification x40)
150x113mm (216 x 216 DPI)

RESPIRATORY CARE Paper in Press. Published on June 12, 2013 as DOI: 10.4187/respcare.02150

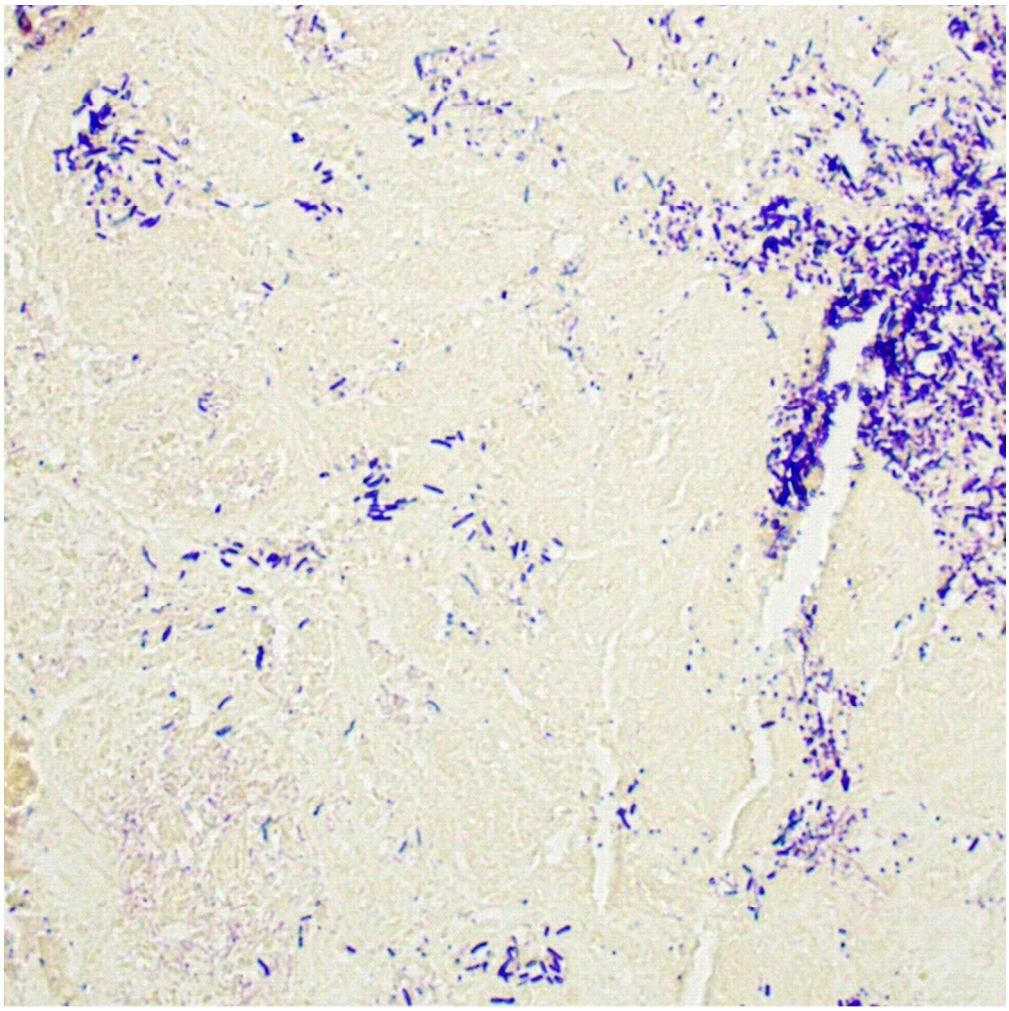

Tissue gram stain revealing numerous gram positive rods. (Original Magnification 60X)
75x75mm (300 x 300 DPI)

RESPIRATORY CARE Paper in Press. Published on June 12, 2013 as DOI: 10.4187/respcare.02150

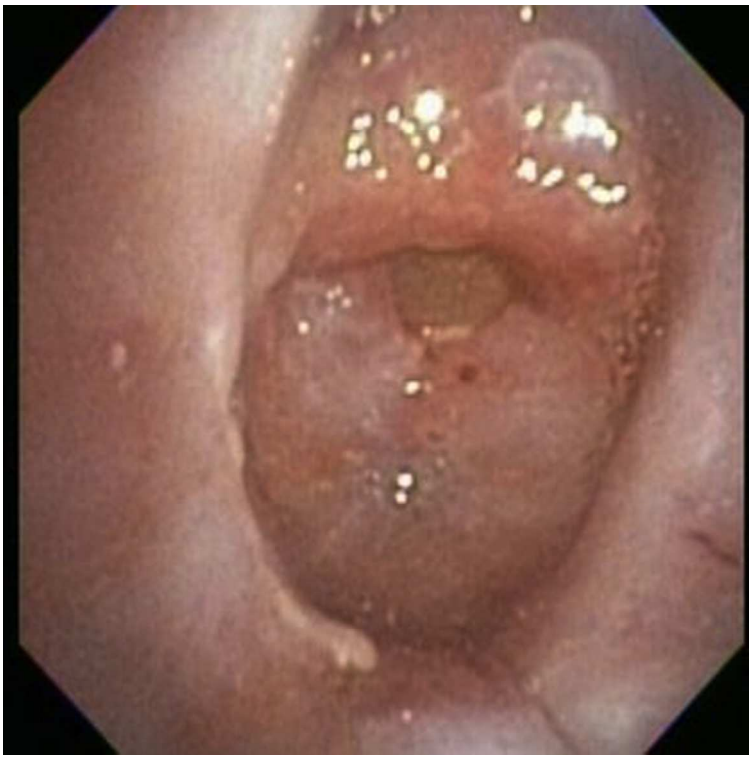

Complete central airway obstruction due to tracheal stenosis as seen from subglottic area via flexible bronchoscopy.
131x131mm (72 x 72 DPI)