RESPIRATORY CARE Paper in Press. Published on November 19, 2013 as DOI: 10.4187/respcare.02775

Benign "metastasizing" leiomyoma presenting as cavitating lung nodules.

Angeliki Loukeri, MD[1]

Ioannis Pantazopoulos, MD, MSc[2]

Rodoula Tringidou, MD, PhD[3]

Pantelis Giampoudakis, MD[2]

Argyro Valaskatzi, MD[3]

Pinelopi Loukeri, MD[4]

Christos Kampolis, MD[2]

[1] Respiratory Intensive Care Unit, Athens Chest Hospital "Sotiria", [2] 12th Respiratory Medicine Dept, Athens Chest Hospital "Sotiria", [3] Pathology Dept, Athens Chest Hospital "Sotiria", [4] 1st Paediatric Clinic, National and Kapodistrian University of Athens Medical School, "Aghia Sophia" Children's Hospital

Conflicts of interest: None, **Financial support:** None

Specific contributions of each contributor to the paper:

Angeliki Loukeri: Patient management, data collection, manuscript preparation, literature search, Ioannis Pantazopoulos: Patient management, data collection, review of manuscript, Rodoula Tringidou: Data collection, review of manuscript, Pantelis Giampoudakis: Patient management, review of manuscript, Argyro Valaskatzi: Data collection, Pinelopi Loukeri: Literature search, Review of manuscript, Christos Kampolis: Data collection, manuscript preparation, literature search

Correspondence:

RESPIRATORY CARE Paper in Press. Published on November 19, 2013 as DOI: 10.4187/respcare.02775

Angeliki Loukeri, MD

Respiratory Intensive Care Unit

Athens Chest Hospital "Sotiria"

Mesogeion 152, 11527, Athens, Greece

Tel. 00302107763439

Fax. 00302107770210

angelouk@live.com

RESPIRATORY CARE Paper in Press. Published on November 19, 2013 as DOI: 10.4187/respcare.02775

Abstract

Benign "metastasizing" leiomyoma (BML) was initially used to describe single or multiple pulmonary nodules composed of proliferating smooth muscle cells, lacking cellular atypia, in premenopausal females 3 months to 20 years after hysterectomy for uterine leiomyoma. The lung is the most commonly involved site, thus including many malignant and benign entities in the differential diagnosis. The present article refers to a 47-year-old premenopausal woman with a history of subtotal hysterectomy for a uterine leiomyoma presenting with bilateral cavitating pulmonary nodules. A number of nodules were resected by video-assisted thoracoscopic surgery. The histological findings in correlation with the immunohistochemical results were consistent with the diagnosis of BML. The patient was subjected to bilateral salpingo-oophorectomy combined with complete removal of the remained cervix. One year later, the patient remains asymptomatic and the pulmonary nodules stable in terms of number, size, location and morphology.

Key words: pulmonary nodules, cavitary, uterine leiomyoma, benign, hysterectomy, premenopause

RESPIRATORY CARE Paper in Press. Published on November 19, 2013 as DOI: 10.4187/respcare.02775

Introduction

Benign "metastasizing" leiomyoma (BML) is a rare entity that usually presents in women who have previously undergone hysterectomy for uterine leiomyomatosis. The typical clinical presentation consists of multiple, benign, slow-growing, smooth muscle tumors in various locations outside the uterus. Lungs are the most frequent site of involvement, while skin, abdomen, mediastinum, nervous system and bones are less commonly affected. Pulmonary nodules of variable size that rarely cavitate, is the most common radiological finding. We report an interesting case of a 47-year-old female patient with BML presenting with cavitating pulmonary nodules.

Case Report

A 47-year-old premenopausal woman, current smoker (50 pack/years), was referred to our department for evaluation of nonproductive cough lasting several days. On admission, she had no additional respiratory or systemic symptoms, such as dyspnea, fever, hemoptysis, pleuritic chest pain, weight loss, or fatigue. Her medical history included a subtotal hysterectomy 9 years ago for a uterine leiomyoma, a colonoscopic polypectomy 2 months before admission and surgical correction of rectovaginal fistula in childhood. She had no family history of gynecological malignancy, had two normal deliveries and had never received oral contraceptives.

Apart from a hysterectomy scar over the lower abdomen, physical examination on admission was unremarkable. Chest x-ray showed multiple bilateral nodular opacities (Figure 1). Laboratory studies including arterial blood gas analysis, complete blood count and erythrocyte sedimentation rate were within normal ranges.

Skin testing for tuberculosis was reactive with a 25mm diameter of induration. Sputum cytology, culture and stains for common bacteria and mycobacteria were negative. Blood tests for collagen vascular disease (ANA, c-ANCA, p-ANCA) and serologic testing for viral or microbial infections were negative as well. Tumor markers including CA125, CA19-9 and CEA were all negative.

A CT scan confirmed the presence of multiple well-circumscribed nodules of varying size, some of them with central cavitation, throughout both lung fields (Figure 2, Panels A+B), without involvement of the mediastinum or pleural space. In view of the presence of bilateral lung nodules, a common appearance of metastatic lesions, a search for a primary carcinoma was performed. Mammography and thyroid ultrasound excluded breast or thyroid neoplasia. Abdominal and pelvic CT-scan revealed a cyst of the right ovary and a cystic formation of the liver.

Fiberoptic bronchoscopy was carried out, and no endobronchial lesions were observed. Cytologic analysis, gram and acid-fast stains and cultures for common bacteria and mycobacteria of BAL fluid were negative. Endobronchial biopsies from normal-appearing mucosa did not reveal neoplasia or inflammatory disease. Subsequent percutaneous fine needle biopsy (FNB) of the lesions was not diagnostic, so a number of nodules were resected by video-assisted thoracoscopic technique. The microscopic examination of all surgical specimens showed multiple nodules variable in size (1-3 cm in diameter) with features of mesenchymal desmoplastic neoplasm. The histological findings in correlation with the immunohistochemical results [Vimentin(+), SMA(+), Desmin (+), ER(+), S-100(-), HMB45(-) and Ki67(+) <3%] were consistent with the diagnosis of benign "metastasizing" leiomyoma (Figure 3, Panels A to F).

18F-FDG positron emission tomography (PET)-computed tomography (CT)

was performed one month after surgery, in order to evaluate the primary lesion and identify potential metastases. The majority of multiple, bilateral, pulmonary nodules were not avid for 18F-FDG, with the exception of the larger one (2cm in diameter) situated in the right upper lobe, which had mild F-FDG uptake (SUV_{max}=2,2) (Figure 4). Increased F-FDG uptake was also observed in the left lung at the site of surgical biopsy. There were no signs of distant malignancy.

Since metastatic lung lesions of benign "metastasizing" leiomyoma may disappear following resection of the primary lesion, therefore indicating hormone dependency, the patient was referred to gynecologists for further evaluation and treatment planning. Bilateral salpingo-oophorectomy was performed and the remained cervix, from the previous subtotal hysterectomy, was additionally removed with simultaneous dissection of both ureters. At the same time, a thorough examination and evaluation of the whole abdomen revealed no further macroscopic disease and peritoneal washings for cytological examination and omental biopsy for pathologic analysis were obtained. Histological examination of all specimens did not reveal any evidence of disease. The postoperative period was uneventful. Pulmonary lesions remained stable, in terms of number, size, location and morphology, in a CT scan performed one year later.

Discussion

Benign "metastasizing" leiomyoma is a term initially used by Steiner in 1939, to describe single or multiple pulmonary nodules composed of proliferating smooth muscle cells, lacking cellular atypia, in premenopausal females after hysterectomy for uterine leiomyoma.[1] It is a rare condition (over 150 cases recorded until 2010) occuring 3 months to 20 years after hysterectomy. The conflicting terminology

"benign" and "metastasizing" reflects its benign histological appearance in contrast to the presence of metastases from the primary site (uterus) to other organs such as lungs, lymph nodes, bone, skeletal muscle and retroperitoneal space.

Several theories have been proposed for the pathogenesis of BML, including:

a) Presence of undetected low grade uterine leiomyosarcoma with metastases.[2] The incidence of malignancy (e.g.,leiomyosarcoma) is low and ranges between 0,13% and 6%.[3] Patients with leiomyoma with a mitotic index of 5-9 per 10hpf or greater, cellular atypia, and coagulative tumor cell necrosis are associated with malignant activity and should be managed as leiomyosarcoma.[4]

b) Lung emboli of cells originating from benign leiomyoma of the uterus. A unified histogenetic view of leiomyoma with vascular microinvasion, BML and intravenous leiomyomatosis has been proposed.[5] Some authors suggest that surgical manipulation may predispose to bloodstream dissemination.[6]

c) Systemic leiomyomatosis with multifocal (in various organs) but independent muscle proliferation, resulting from an abnormal sexual hormonal status.[7]

In our case the more plausible theory seems to be that of intravascular seeding of benign smooth muscle cells during the initial operation. Absence of foci of cellular atypia in pulmonary nodules, residual uterine and peritoneal tissue exclude the presence of low grade leiomyosarcoma. In addition, normal chest x-ray at initial surgery and a prolonged ensuing time interval and absence of extrathoracic lesions in CT scan make the synchronous multifocal leiomyomatosis theory less likely.

The lung is the most common site of involvement, with typically indolent clinical course. Typical radiographic presentation is well-circumscribed solitary or multiple pulmonary nodules with smooth or lobulated margins, unilaterally or mostly bilaterally distributed. Lesion size ranges from few millimeters to several

centimeters.[8] The nodules do not display contrast enhancement in CT scan and rarely present calcification, cavitation[9,10] or cystic degeneration[11] frequently complicated by pneumothorax. The radiological imaging appearance of multiple pulmonary nodules with cavitation, mimics many entities that have to be included in the differential diagnosis: metastases from malignant tumors such as sarcoma, squamous cell cancer (especially spindle cell subtype), transitional cell carcinoma of the bladder, melanoma and less frequently lymphoma, the multinodular form of bronchioalveolar cell carcinoma, ANCA-associated granulomatous vasculitis, necrotizing bacterial pneumonia or multifocal parenchymal infarctions, granulomas due to fungal or mycobacterial infections and the rare, smoking-related, Langheran's cell histiocytosis.

PET/CT scan findings in our patient were consistent with previously published cases, reporting non-avid or mild FDG uptake (SUV_{max} <3) by pulmonary nodules. [12,13]

The presence of estrogen and progesterone receptors has been documented in most of the cases of BML, and it is likely that the growth and progression of BML is closely related to stimulation by reproductive hormones.[14] Since BML is a hormone-dependent tumor, the objective of the therapy is to prevent the proliferation of the smooth-muscle cells, due to hormonal stimulation, by reducing the estrogen levels. The choice of the treatment can be difficult, especially for younger women in reproductive age. Bilateral salpingo-oophorectomy without estrogen replacement therapy is usually effective.[15] Hormonal treatment (GnRh analogues, progestins, tamoxifen, raloxifen or aromatase inibitors) is reported as an alternative method in selected patients with beneficial effects,[16] obviating the need for a surgical procedure or allowing symptom control when surgical management is not possible.

Occasionally, the combination of pelvic surgery and hormonal treatment has been proposed.[17] Other reported treatment methods include chemotherapy, radiotherapy of the ovary, resection of the pulmonary nodules or careful observation, especially in women in menopause with declining estrogen levels. Most BML lesions remain constant or decrease in size, during the follow-up after bilateral salpingo-oophorectomy.[15] Long-term follow up is recommended in all cases of BML, because of the potential risk of recurrence[4] and malignant behavior despite oophorectomy or hormonal suppression. PET/CT scan may reveal a mild FDG uptake and the potential of low grade malignancy cannot be excluded if the pulmonary nodule has not been biopsied and/or surgically removed. In our patient, pulmonary lesions remained stable, in terms of number, size, location and morphology, in a CT scan performed one year later.

Benign "metastasizing" leiomyoma, presenting as cavitating pulmonary nodules, is a rare clinical entity and should be part of the differential diagnosis in women with a history of hysterectomy.

References

1. Steiner PE. Metastasizing fibroleiomyoma of the uterus: Report of a case and review of the literature. Am J Pathol 1939;15(1):89–110.

2. Jautzke G, Müller-Ruchholtz E, Thalmann U. Immunohistological detection of estrogen and progesterone receptors in multiple and well differentiated leiomyomatous lung tumors in women with uterine leiomyomas (so-called benign metastasizing leiomyomas). A report on 5 cases. Pathol Res Pract 1996;192(3):215–223.

3. Robboy SJ, Bentley RC, Butnor K, Anderson MC. Pathology and

pathophysiology of uterine smooth-muscle tumors. Environ Health Perspect 2000;108 Suppl 5:779–784.

4. Awonuga AO, Rotas M, Imudia AN, Choi C, Khulpateea N. Recurrent benign metastasizing leiomyoma after hysterectomy and bilateral salpingo-oophorectomy. Arch Gynecol Obstet 2008;278(4):373–376.

5. Canzonieri V, D'Amore ES, Bartoloni G, Piazza M, Blandamura S, Carbone A. Leiomyomatosis with vascular invasion. A unified pathogenesis regarding leiomyoma with vascular microinvasion, benign metastasizing leiomyoma and intravenous leiomyomatosis. Virchows Arch 1994;425(5):541–545.

6. Egberts JH, Schafmayer C, Bauerschlag DO, Jänig U, Tepel J. Benign abdominal and pulmonary metastasizing leiomyoma of the uterus. Arch Gynecol Obstet 2006;274(5):319–322.

7. Cho KR, Woodruff JD, Epstein JI. Leiomyoma of the uterus with multiple extrauterine smooth muscle tumors: a case report suggesting multifocal origin. Hum Pathol 1989;20(1):80–83.

8. Abramson S, Gilkeson RC, Goldstein JD, Woodard PK, Eisenberg R, Abramson N. Benign metastasizing leiomyoma: clinical, imaging, and pathologic correlation. AJR Am J Roentgenol 2001;176(6):1409–1413.

9. Shin MS, Fulmer JD, Ho KJ. Unusual computed tomographic manifestations of benign metastasizing leiomyomas as cavitary nodular lesions or interstitial lung disease. Clin Imaging 1996;20(1):45–49.

10. Fasih N, Prasad Shanbhogue AK, Macdonald DB, Fraser-Hill MA, Papadatos D,

Kielar AZ, et al. Leiomyomas beyond the uterus: unusual locations, rare manifestations. Radiographics 2008;28(7):1931–1948.

11. Gotti G, Haid MM, Paladini P, Di Bisceglie M, Volterrani L, Sforza V. Pedunculated pulmonary leiomyoma with large cyst formation. Ann Thorac Surg 1993;56(5):1178–1180.

12. Lin X, Fan W, Lang P, Hu Y, Zhang X, Sun X. Benign metastasizing leiomyoma identified using 18F-FDG PET/CT. Int J Gynaecol Obstet 2010;110(2):154–156.

13. Di Scioscio V, Feraco P, Miglio L, Toni F, Malvi D, Pacilli AM, et al. Benign metastasizing leiomyoma of the lung: PET findings. J Thorac Imaging 2009;24(1):41–44.

14. Jiang GQ, Gao YN, Gao M, Zheng H, Yan X, Wang W, et al. Benign metastasizing leiomyoma: report of two cases and literature review. Chin Med J (Engl) 2010;123(22):3367–3371.

15. Banner AS, Carrington CB, Emory WB, Kittle F, Leonard G, Ringus J, et al. Efficacy of oophorectomy in lymphangioleiomyomatosis and benign metastasizing leiomyoma. N Engl J Med 1981;305(4):204–209.

16. Rivera JA, Christopoulos S, Small D, Trifiro M. Hormonal manipulation of benign metastasizing leiomyomas: report of two cases and review of the literature. J Clin Endocrinol Metab 2004;89(7):3183–3188.

17. Nasu K, Tsuno A, Takai N, Narahara H. A case of benign metastasizing leiomyoma treated by surgical castration followed by an aromatase inhibitor, anastrozole. Arch Gynecol Obstet 2009;279(2):255–257.

RESPIRATORY CARE Paper in Press. Published on November 19, 2013 as DOI: 10.4187/respcare.02775

Figure legends

Figure 1: Posteroanterior radiograph of chest shows multiple bilateral nodules.

Figure 2: Initial CT scan (Panels A+B) showed a partially cavitated nodule (black arrowhead) and thin-walled cavities (white arrows) in the upper and lower lung fields bilaterally.

Figure 3: Histological features of benign "metastasizing" leiomyoma in lung.

A: Area of ''metastasizing'' leiomyoma in lung parenchyma (H-E stain x 40), B: Area of ''metastasizing'' leiomyoma in a partially cavitated nodule of the left upper lobe (thick arrow) (H-E stain x 100), C: Area of ''metastasizing'' leiomyoma in a solid nodule of the left lower lobe (H-E stain x 100), D: Area with spindle and round neoplastic cells in H-E stain x 100 (thin arrows), E: SMA positivity in spindle and round neoplastic cells in "metastasizing" leiomyoma. (SMA stain x 100), F: Higher magnification of the square area of SMA positivity (SMA stain x 400).

Figure 4: The larger of multiple lung nodules (d=2cm), situated in the right upper lobe, had mild 18F-FDG uptake (SUV_{max}=2,2) in PET/CT scan (Panels A + B).

RESPIRATORY CARE Paper in Press. Published on November 19, 2013 as DOI: 10.4187/respcare.02775

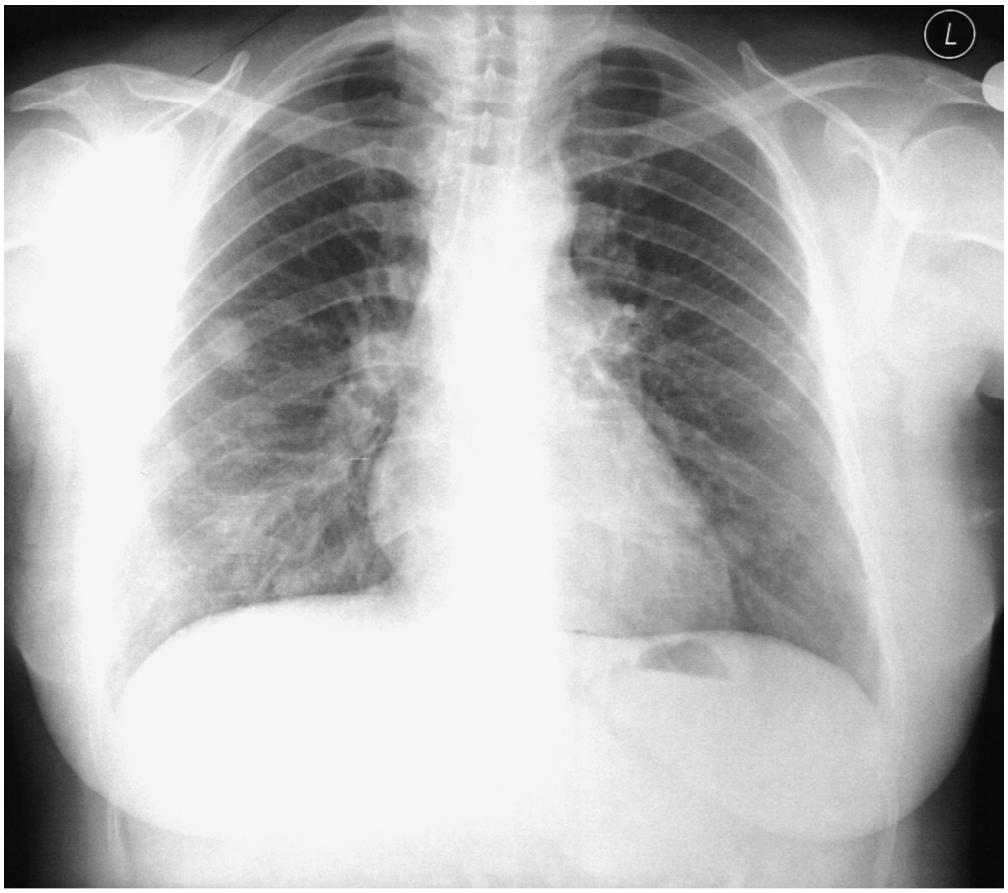

100x88mm (300 x 300 DPI)

RESPIRATORY CARE Paper in Press. Published on November 19, 2013 as DOI: 10.4187/respcare.02775

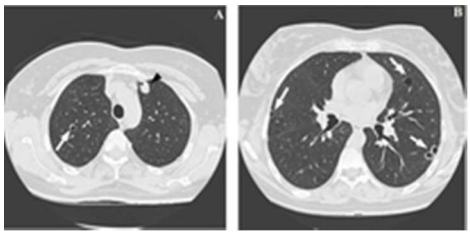

19x9mm (300 x 300 DPI)

RESPIRATORY CARE Paper in Press. Published on November 19, 2013 as DOI: 10.4187/respcare.02775

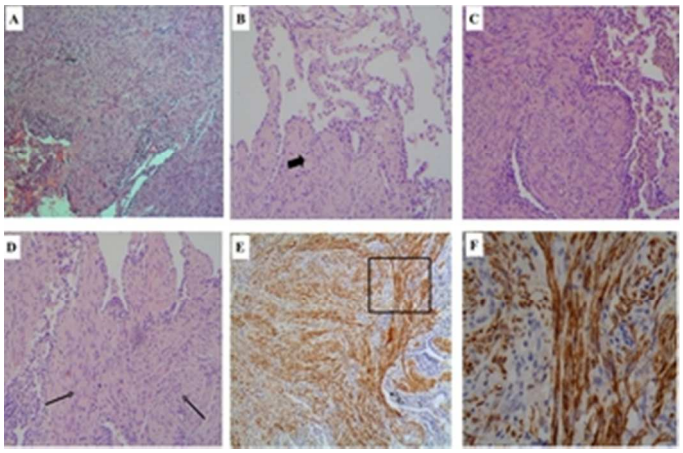

28x18mm (300 x 300 DPI)

RESPIRATORY CARE Paper in Press. Published on November 19, 2013 as DOI: 10.4187/respcare.02775

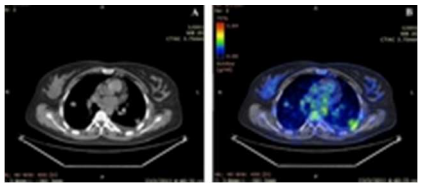

17x7mm (300 x 300 DPI)