

Pulmonary Venous Thrombosis and Infarction Complicating Pulmonary Venous Stenosis Following Radiofrequency Ablation

Jose Yataco MD and James K Stoller MD MSc FAARC

Pulmonary vein stenosis is a recently described complication of radiofrequency ablation. We report a patient who experienced thrombosis of the lingular vein and pulmonary infarction resulting from mild single-vessel pulmonary vein stenosis. This report extends available experience with complications of radiofrequency ablation, by demonstrating pulmonary venous thrombosis as a complication of relatively minor (approximately 50% luminal narrowing) stenosis of a single pulmonary vein, despite the fact that the patient was taking an anticoagulant. Key words: pulmonary vein stenosis, radiofrequency ablation, atrial fibrillation. [Respir Care 2004;49(12):1525–1527. © 2004 Daedalus Enterprises]

Introduction

Radiofrequency ablation of the pulmonary veins is a newly available treatment for chronic atrial fibrillation. As a recently appreciated and uncommon complication of radiofrequency ablation, severe pulmonary vein stenosis has been reported in 5% of a cohort of 335 individuals who underwent radiofrequency ablation.¹ The presenting symptoms have included dyspnea, cough, hemoptysis, pleuritic pain, and pulmonary consolidation in a cohort in whom the degree of stenosis exceeded 70% of the vein caliber in at least 2 pulmonary veins. The present report extends understanding of the pulmonary complications of radiofrequency ablation by describing a patient who experienced lingular vein thrombosis and infarction after mild stenosis of a single pulmonary vein.

Case Summary

A 44-year-old man was transferred to The Cleveland Clinic Hospital after experiencing hemoptysis and pleuritic chest pain for 6 days. Having experienced atrial fibrillation for 8 years, he was on longstanding warfarin

(with consistently therapeutic international normalized ratio values) and had failed treatment of his atrial fibrillation with multiple anti-arrhythmic drugs. Thus, he underwent radiofrequency ablation 3 months before the admission that led to this case report. The ablation procedure involved placement of a steerable quadripolar catheter into the pulmonary vein via a transeptal approach (quadripolar 4-mm tip and 8-mm tip catheters, Biosense Webster, Diamond Bar, California) and a cool-tipped catheter (EPT, Chilli, Sunnyvale, California). An intracardiac echocardiography catheter was used to image the transeptal puncture, to observe catheter positions, and to identify the ostia of the pulmonary veins. All 4 veins were mapped and ablated successfully.

As part of a radiofrequency ablation management protocol, the patient underwent spiral computed tomography of the pulmonary veins, with 3-dimensional reconstruction, at baseline and 3 months after the procedure. The veins were normal at baseline, but tomographic measurement of the luminal caliber of the left superior pulmonary vein showed 50% reduction 3 months following radiofrequency ablation. All 3 other pulmonary veins were of normal baseline caliber and the patient was asymptomatic.

Sixteen weeks after the radiofrequency ablation treatment, he developed hemoptysis, severe left pleuritic chest pain, and mild dyspnea, prompting concern about a possible pulmonary embolism, despite his therapeutic anticoagulation. Evaluation included a lung scan, which showed absent perfusion to the lingula, and a new computed tomogram (Fig. 1), which showed interval development of new thrombosis of the lingular branch of the vein, infarc-

Jose Yataco MD and James K Stoller MD MSc FAARC are affiliated with the Department of Pulmonary, Allergy, and Critical Care Medicine, The Cleveland Clinic Foundation, Cleveland, Ohio.

Correspondence: Jose Yataco MD, Department of Pulmonary, Allergy, and Critical Care Medicine, A90, The Cleveland Clinic Foundation, 9500 Euclid Avenue, Cleveland OH 44195. E-mail: yatacoj@ccf.org.

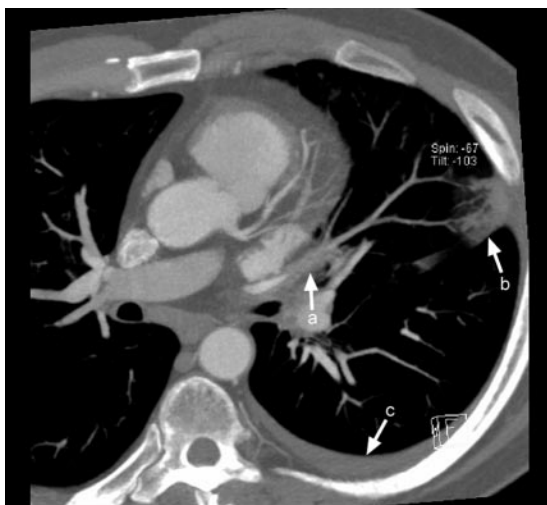

Fig. 1. This chest computed tomogram shows (a) new thrombosis of the lingular branch of the pulmonary vein, (b) pulmonary infarction, and (c) small pleural effusion.

tion of the lingula, and a stable approximately 50% stenosis of the left superior pulmonary vein. There was no evidence of filling defects in the pulmonary arteries.

Hemoptysis remitted after 3 days, with simultaneous improvement of the other associated symptoms. A chest radiograph taken 12 days after his initial presentation showed a small left pleural effusion and some streaky infiltrates in the lingula (Fig. 2). He was discharged in stable condition but with recurrence of atrial fibrillation.

Discussion

In the context that (1) atrial fibrillation is increasingly common, (2) ablation catheter procedures have evolved as a new treatment option for drug-refractory atrial fibrillation, and (3) complications of radiofrequency ablation can have important pulmonary manifestations, awareness of its consequences and complications is important for pulmonary/critical care clinicians. Indeed, known complications of radiofrequency ablation include stroke, transient ischemic attacks, pericardial effusion, and severe pulmonary vein stenosis.¹⁻³

Series to date suggest that the prevalence of pulmonary vein stenosis after radiofrequency ablation ranges from 3–42%, varying by the method of assessing venous stenosis and the ablation technique used.^{1,4} In the largest available consecutive series, Saad et al¹ described severe pulmonary vein stenosis (defined as $\geq 70\%$ luminal narrowing) in 5% of 335 patients. Fifty-six percent of those patients were symptomatic, with the commonest symptoms including dyspnea (44%), cough (39%), and hemoptysis (28%). Total occlusion of at least one pulmonary vein occurred in 2.1% of patients. In another series, Ernst et al³

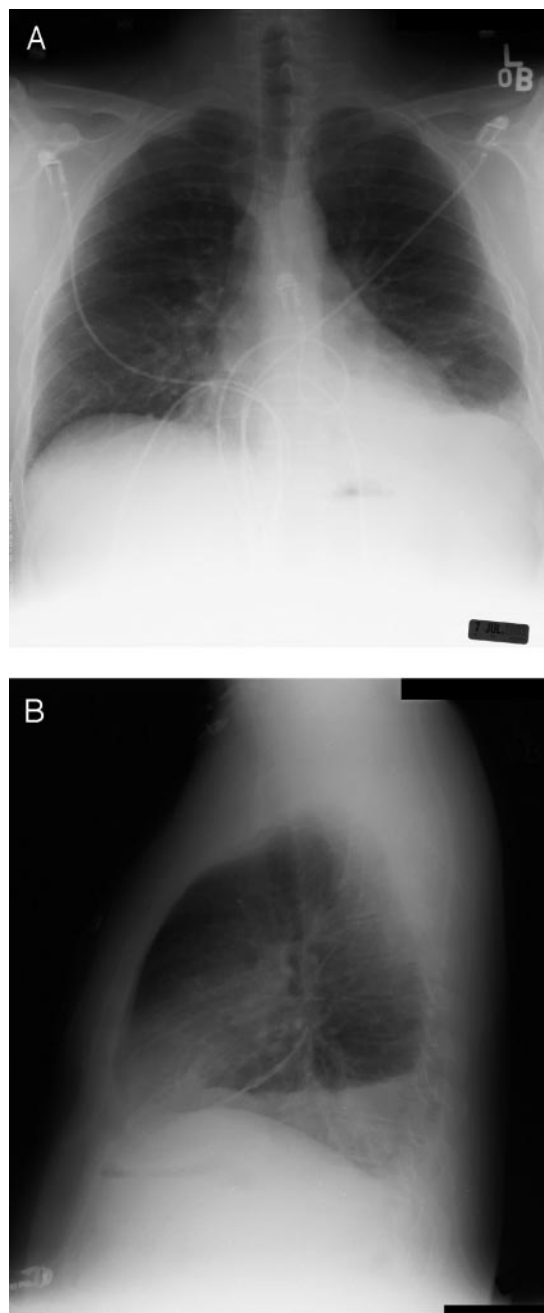


Fig. 2. These posteroanterior (A) and lateral (B) chest radiographs show a small left pleural effusion and a streaky infiltrate in the lingula.

described total pulmonary vein occlusion in 1.3% of 229 patients. Finally, Robbins et al² reported severe pulmonary hypertension in 2 patients who experienced severe narrowing of all 4 pulmonary veins near the left atrial junction 3 months after successful radiofrequency ablation.

Available experience suggests that the occurrence and severity of symptoms relate both to the degree of luminal narrowing and to the number of pulmonary veins affected,

with most patients described to date having both multiple and high-grade stenoses.⁴⁻⁶

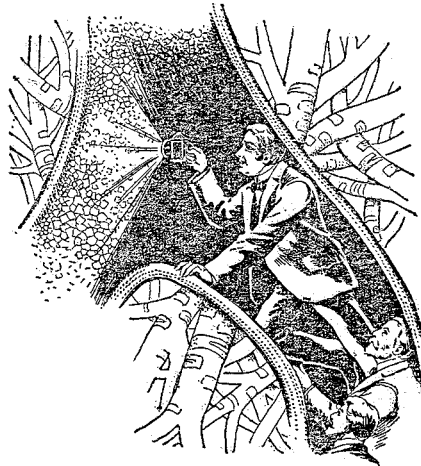
The present report extends in several ways the available experience with pulmonary vein stenosis complicating radiofrequency ablation. First, our patient developed severe symptoms (eg, dyspnea and hemoptysis) despite only relatively mild (approximately 50%) luminal narrowing of a single pulmonary vein, which challenges the belief that symptoms are confined to patients with severe and multiple stenoses. Second, in contrast to earlier reports, in which the perfusion deficit was attributed to pulmonary venous stricture, the perfusion deficit in our patient reflected a thrombus, presumably in situ, complicating a single, narrowed but incompletely occluded pulmonary vein. Third, our patient's experience suggests that therapeutic anticoagulation may not protect against this complication.

In summary, our patient experienced lingular infarction following relatively mild stenosis of a single pulmonary vein following radiofrequency ablation for atrial fibrillation. Clinicians should be vigilant for even mild degrees of

pulmonary vein stenosis in symptomatic patients following ablation therapy for atrial fibrillation.

REFERENCES

1. Saad EB, Rossillo A, Saad CP, Martin DO, Bhargava M, Erciyes D, et al. Pulmonary vein stenosis after catheter ablation of atrial fibrillation: emergence of a new clinical syndrome. *Ann Intern Med* 2003; 138(8):634-639.
2. Robbins IM, Colvin EV, Doyle TP, Kemp WE, Loyd JE, McMahon WS, et al. Pulmonary vein stenosis after catheter ablation of atrial fibrillation. *Circulation* 1998;98(17):1769-1775.
3. Ernst S, Ouyang F, Goya M, Lober F, Schneider C, Hoffmann-Riem M, et al. Total pulmonary vein occlusion as a consequence of catheter ablation for atrial fibrillation mimicking primary lung disease. *J Cardiovasc Electrophysiol* 2003;14(4):366-370.
4. Oral H. Pulmonary vein occlusion/stenosis after pulmonary vein ablation for atrial fibrillation. *J Cardiovasc Electrophysiol* 2003; 14(4):371-372.
5. Hindricks G, Kottkamp H. Potential benefits, risks and complications of catheter ablation of atrial fibrillation: more questions than answers. *J Cardiovasc Electrophysiol* 2002;13(8):768-769.
6. Chen SA. Catheter ablation of atrial fibrillation: fact and controversy. *J Cardiovasc Electrophysiol* 2002;13(11):1074-1075.



From "A Trip to the Lungs." Hartman, SB.
The Hartman Magazine of Health, Vol I, No. 1
 New York: American Lithographic; January 1903