

Teaching Case of the Month

Methemoglobinemia: Sudden Dyspnea and Oxyhemoglobin Desaturation After Esophagoduodenoscopy

Ellen Lunenfeld MD and Gregory C Kane MD

Introduction

Methemoglobinemia is a relatively common condition. Methemoglobin is formed when hemoglobin is converted to a form that cannot bind oxygen. In methemoglobin the ferrous (Fe^{+2}) irons of heme are oxidized to the ferric (Fe^{+3}) state. The ferric hemes of methemoglobin cannot bind oxygen and the remaining ferrous hemes are left-shifted on the oxygen dissociation curve. The result is markedly diminished oxygen delivery to the tissues and metabolic acidosis.^{1,2}

In the normal state approximately 1% of hemoglobin is auto-oxidized to methemoglobin. Excessive methemoglobin (methemoglobinemia) can be caused by various genetic factors and numerous substances (Table 1). Many drugs can cause methemoglobinemia as an idiosyncratic reaction, including some of the most common drugs in the hospital setting, such as lidocaine and nitroglycerin.^{1,2} Most drugs that can cause methemoglobinemia, including the topical anesthetics (such as cetacaine in the case described below), do so by oxidation, either directly or by oxidizing agents formed during their metabolism. The severity of symptoms is influenced by the rapidity of entrance of the oxidant into the body, the rate of metabolism and excretion of the compound, and the effectiveness of natural reduction systems.

Case Report

A 52-year-old man with a history of squamous cell carcinoma of the tongue and alcohol abuse presented with one episode of hematemesis and occasional bright red blood per rectum over one week. He had last noted blood in the vomitus approximately 3 days prior. Then

Table 1. Substances Associated With Generation of Methemoglobinemia

Acetanilide	Nitroethane
p-Aminosalicylic acid	Nitrofurantoin
Amyl nitrite	Nitroglycerin
Aniline	Nitroethane
Benzocaine	Nitroprusside
Cetacaine	Paraquat
Chloroquine	Phenacetin
Clofazimine	Phenazopyridine
Dapsone	Phenylhydrazine
Hydroxylamine	Prilocaine
Lidocaine	Primaquine
Menadione	Resorcinol
Metoclopramide	Silver nitrate
Naphthalene	Sodium nitrite
Naphthoquinone	Sulfanilamide
Nitric oxide	Sulfonamide antibiotics
Nitrobenzene	Trinitrotoluene

he noted dark stools during the 2 days before he presented to the emergency room. Initial physical examination revealed a thin black man in no distress, heart rate 74 beats/min, blood pressure 136/72 mm Hg, respiratory rate 18 breaths/min, temperature 37.1°C. His head and neck were normal and there was no adenopathy or jugular vein distention. His lungs were clear and his heart was normal. The abdomen was soft and nontender, without rebound. There was no edema. Admission blood laboratory values were: hemoglobin 9.3 g/dL, white blood cells 10.7 cells/ μL , hematocrit 28.0%, platelets 524,000 cells/ μL , sodium 136 mEq/L, potassium 3.4 mEq/L, chloride 101 mEq/L, bicarbonate 24 mEq/L, blood urea nitrogen 6 mg/dL, creatinine 1.0 mg/dL, glucose 136 mg/dL. Coagulation studies were normal. The patient was admitted for monitoring overnight, received a transfusion of packed red blood cells, and was started on normal saline replacement fluid. His hemoglobin remained stable throughout the night, and an endoscopy was performed the following morning.

The endoscopy began uneventfully. Pre-endoscopy medications included midazolam 5 mg, meperidine 1 mg, and topical Cetacaine spray. A large mass was found

Ellen Lunenfeld MD and Gregory C Kane MD are affiliated with the Department of Medicine, Jefferson Medical College, Philadelphia, Pennsylvania.

Correspondence: Ellen Lunenfeld MD, Department of Medicine, Jefferson Medical College, 1025 Walnut Street, #805, Philadelphia PA 19107. E-mail: ellen.lunenfeld@mail.tju.edu.

in the fundus of the stomach, with a focal area of ulceration. Near the end of the procedure the patient was noted to have rapidly dropping blood oxygen saturation (as measured via pulse oximetry [S_{pO_2}]), so the procedure was abruptly terminated. On physical examination he appeared to be in acute distress, with dyspnea and tachycardia: heart rate 107 beats/min, respiratory rate 28 breaths/min, blood pressure 106/64 mm Hg. S_{pO_2} was 54% while receiving 100% oxygen via face mask. He appeared cyanotic. His lungs were clear bilaterally, without rales, wheezes, or rhonchi. There was no cardiac abnormality or murmur. His neck veins were flat. A "code blue" was called and an arterial blood sample was obtained for blood gas measurement. The respiratory therapist noted that the blood appeared "like chocolate."

The blood gas analysis revealed a pH of 7.32, P_{aCO_2} 37 mm Hg, P_{aO_2} 117 mm Hg. Oxyhemoglobin was 22.2% and methemoglobin was 77.4%. Methylene blue (1 mg/kg) was administered and S_{pO_2} improved to approximately 75%. Approximately 5 min after the first dose, another 1 mg/kg dose of methylene blue (ie, a total of 2 mg/kg) improved S_{pO_2} to 92% while the patient breathed 100% oxygen via nonrebreather face mask. The patient recovered from this acute event and was discharged for follow-up care of his gastric tumor several days later.

Discussion

Because of its acute onset and grave consequences if not treated immediately, methemoglobinemia needs to be recognized rapidly and treatment started within minutes of diagnosis. Acute toxic methemoglobinemia should be suspected when clinical cyanosis exists despite a normal arterial P_{O_2} . One of the key features of methemoglobinemia is the discrepancy between P_{O_2} and S_{pO_2} .³ During methemoglobinemia, drawn blood will appear dark red or chocolate-colored.⁴ The diagnosis is confirmed by co-oximetry and is clinically important when methemoglobin is > 10% of the total hemoglobin. Methemoglobin absorbs light at a different frequency than does normal hemoglobin—a characteristic that can be detected by co-oximetry, which is a function of many arterial blood gas analysis machines.^{2,4} Caution should be used in settings where blood oxygen saturations are derived from the P_{O_2} value, because in that circumstance methemoglobin could mislead the clinician.

The symptoms of methemoglobinemia differ according to the percentage of methemoglobin in the blood. Mild methemoglobinemia can cause headache, fatigue, dyspnea, and lethargy, whereas more severe methemoglobinemia can cause respiratory depression, altered con-

sciousness, shock, seizure, and death.^{1,2} The condition is often fatal when the methemoglobin level exceeds 70%.²

Pathogenesis and Biochemistry

In the normal state approximately 0.5–3% of hemoglobin is converted to methemoglobin per day and methemoglobin can be formed by multiple mechanisms.¹ When oxyhemoglobin is formed from deoxyhemoglobin and oxygen, one electron is transferred from heme to oxygen, forming a ferric-superoxide anion complex. Occasionally oxygen leaves as this superoxide and the iron remains in the ferric state, thereby forming methemoglobin. It can also be formed when hemoglobin is oxidized by free radicals or other compounds naturally present in the body. For example, hydrogen peroxide, nitric oxide, or the hydroxyl radical can produce methemoglobin. Maintaining the percentage of methemoglobin at a low level therefore depends on a mechanism for reducing the methemoglobin, which is constantly produced in the body. There are 2 mechanisms that reduce methemoglobin to oxyhemoglobin (Figs. 1 and 2). The cytochrome b5 reductase pathway is the most important pathway under normal conditions. This pathway operates by nicotinamide adenine dinucleotide with high-energy hydrogen (NADH) reducing flavin adenine dinucleotide (FAD) to reduced flavin adenine dinucleotide (FADH₂), which in turn reduces the heme protein cytochrome b5. In the hexosemonophosphate shunt pathway, glucose-6-phosphate dehydrogenase (G6PD) generates reduced nicotinamide adenine dinucleotide phosphate (NADPH), which can be used as a source of electrons, but electron acceptors such as methylene blue and flavin are necessary for that pathway.^{1,2}

The most common form of methemoglobinemia is acute toxic methemoglobinemia, which can be caused by various drugs used in patient care. Genetic disorders, including NADH-cytochrome b5 reductase deficiency, cytochrome b5 deficiency, and hemoglobin M disease can also cause methemoglobinemia.¹

The primary treatment for acute toxic methemoglobinemia is methylene blue, 1–2 mg/kg over 5 min,² and that dose may be repeated in an hour if necessary.

Overdose of methylene blue can cause dyspnea, chest pain, and hemolysis, because at high doses it can act as an oxidant and cause additional conversion of hemoglobin to methemoglobin. Caution must be used with patients who have glucose-6-phosphate dehydrogenase deficiency, because methylene blue will not be effective and can cause hemolysis.¹ Instead, use ascorbic acid and exchange transfusion. In an emergency situation exchange transfusion is

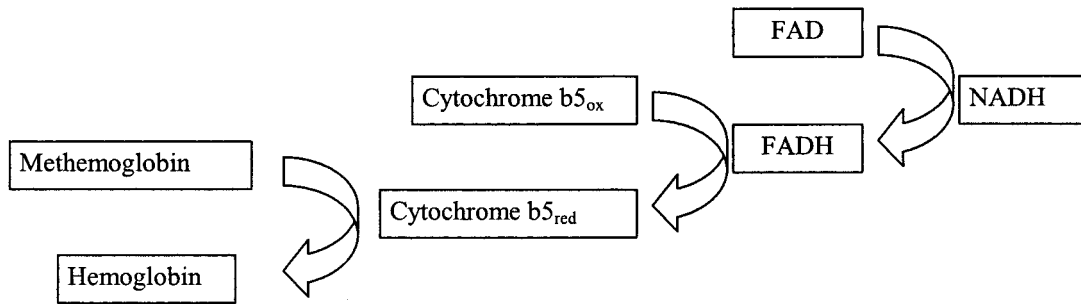


Fig. 1. Reduction of methemoglobin to hemoglobin via cytochrome b5 reductase. FAD = flavin adenine dinucleotide. FADH = reduced flavin adenine dinucleotide. NADH = nicotinamide adenine dinucleotide with high-energy hydrogen.

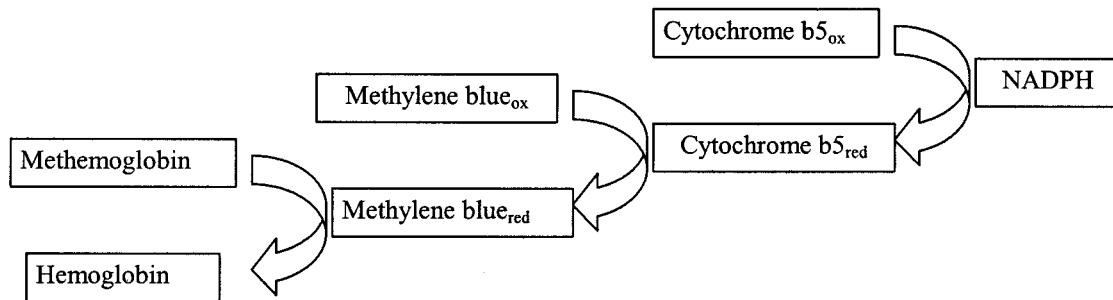


Fig. 2. Reduction of methemoglobin to hemoglobin via methylene blue. NADPH = reduced nicotinamide adenine dinucleotide phosphate.

the treatment of choice, because ascorbic acid has a delayed onset of action.⁵

Teaching Points

1. Many substances, including chemical toxins and medicines used in clinical care, can cause methemoglobinemia.
2. Methemoglobinemia should be suspected when there are symptoms of tissue hypoxemia and a discrepancy between S_{pO_2} and P_{aO_2} (ie, S_{pO_2} lower than predicted).
3. Treatment of methemoglobinemia includes intravenous methylene blue and consideration of exchange transfusion and ascorbic acid treatment for patients who have glucose-6-phosphate dehydrogenase deficiency.

REFERENCES

1. Prehal JT, Gregg XT. Red cell enzymopathies. In: Hoffman R, Benz EJ Jr, Shattil SJ, et al, editors. Hematology: basic principles and practice, 3rd edition. New York: Churchill-Livingstone; 2000:561–576.
2. Wright RO, Lewander WJ, Woolf AD. Methemoglobinemia: etiology, pharmacology, and clinical management. *Ann Emerg Med* 1999; 34(5):646–656.
3. Donnelly GB, Randlett D. Methemoglobinemia. *N Engl J Med* 2000; 343(5):337.
4. Konig MW, Dolinski SY. A 74-year-old woman with desaturation following surgery: co-oximetry is the first step in making the diagnosis of dysmethemoglobinemia. *Chest* 2003;123(2):613–616.
5. Karim A, Ahmed S, Siddiqui R, Mattana J. Methemoglobinemia complicating topical lidocaine used during endoscopic procedures. *Am J Med* 2001;111(2):150–153.