

THORACIC ULTRASOUND-ASSISTED SELECTION FOR PLEURAL BIOPSY WITH ABRAMS NEEDLE

Authors: Maribel Botana-Rial (1), Virginia Leiro-Fernández (1), Cristina Represas-Represas (1), Ana González Piñeiro (2), Amara Tilve-Gómez (3), Alberto Fernández-Villar (1)

(1) Bronchopleural Unit, Department of Pneumology, (2) Department of Pathology, (3) Department of Radiology. Complejo Hospitalario Universitario de Vigo. Vigo, Spain. Respiratory and Infectious Disease Research Group. Bio-medical Research Institute of Vigo.

Corresponding author:

Alberto Fernández-Villar. Pneumology Service. Complejo Hospitalario Universitario de Vigo. C/Pizarro, nº 22. 36204. Vigo, Spain. Telephone and FAX: 34-696826015/986816034

E-mail: alberto.fernandez.villar@sergas.es

ABSTRACT

BACKGROUND: Closed pleural biopsy (CPB) in patients with malignant pleural effusion (MPE) is less sensitive than cytology. Ultrasound-assisted CPB allows biopsies to be performed in the lower thoracic parietal pleura, where secondary spread from pleural metastases is initially more likely to be found.

OBJECTIVES: We analyzed whether choosing the point of entry for CPB with thoracic ultrasound assistance influences the diagnostic yield in MPE.

METHODS: This prospective study included patients who underwent CPB performed by an experienced pulmonologist in 2008–2010 (group A), thoracic ultrasound was used to select the biopsy site. The results were compared with a historical series of CPB performed by the same pulmonologist without the assistance of thoracic ultrasound (group B). An Abrams needle was used in all cases. We analyzed the obtaining of pleural tissue and the diagnostic yield.

RESULTS: We included 114 CPB from group A (23% TPE, 27.2% MPE) and 67 CPB from group B (24% tuberculous pleural effusion (TPE), 30% MPE) ($p=0.7$). Pleural tissue was obtained in 96.5% of group A CPB and 89.6% of group B CPB ($p=0.05$). The diagnostic yields of CPB for TPE and MPE in group A were 89.5% and 77.4%, respectively, and 91.7% and 60%, respectively, in group B ($p=0.8$, TPE and $p=0.18$, MPE).

CONCLUSIONS: Selecting the point of entry for CPB using thoracic ultrasound increases the likelihood of obtaining pleural tissue and the diagnostic yield, but without statistically significance. We recommend ultrasound-assisted CPB to investigate pleural effusion, since the diagnostic yield of a pleural biopsy with an Abrams needle increased by >17% in patients with MPE.

Keywords: Abrams pleural needle; biopsy pleural; diagnostic; malignant pleural effusion; thoracic ultrasound.

BACKGROUND

Pleural effusion (PE) can occur as a complication of more than 50 different diseases, and accurately establishing a diagnosis is an essential step in the management of these patients. After parapneumonic PE, the most frequent causes of exudative PE are malignant PE (MPE) and tuberculous PE (TPE)[1-3]. To differentiate among the various causes of exudative PE, biochemical, microbiological, and cytological analyses of the pleural liquid should be performed [1,2]. However, after an initial thoracentesis, approximately 40% of patients remain undiagnosed; thus, the next step is a pleural biopsy (PB) [1,2]. Some controversy exists about the ideal procedure that should be used to perform a PB[4]. The PB can be a closed PB (CPB), PB guided by imaging, or thoracoscopy [1,2].

The diagnostic yield of CPB with respect to MPE is lower than that of cytology, with the reported sensitivities ranging from 48%–56% for CPB [1-3]. One possible reason for the low yield might be patchy involvement of the pleura in MPE. This low yield does not occur in TPE, which has a diffuse expression throughout the pleural surfaces, and for which sensitivity can reach 85% [1,2]. Another factor that might influence the diagnostic yield of CPB is that pleural malignant deposits tend to predominate close to the midline and diaphragm, which are areas that are best avoided when performing CPB [4]. Based on its low diagnostic sensitivity, the utility of CPB in the investigation of exudative PE has been questioned [4, 5].

Thoracoscopy is the “gold standard” for the diagnosis of MPE [2,3]. Nevertheless, some studies have proposed that CPB guided by imaging can obtain a diagnostic yield similar to that of thoracoscopy [6-10]. PB guided by imaging (CT or ultrasound scan) or thoracoscopy should be performed in almost all patients with exudative PE of unknown etiology [2,11].

Ultrasound-assisted CPB allows biopsies to be performed in the lower thoracic parietal pleura, where the secondary spread from pleural metastases is more likely to be initially found, and may lead to improved diagnostic yield [3,5]. Recently, Koegelenberg et al., in a study performed with another objective, determined that an ultrasound-assisted Abrams pleural needle had a higher diagnostic yield than had been previously published [12]. The authors hypothesized that this high yield might be due to the use of ultrasound, which

enables the biopsy to be performed closer to the diaphragm [12]. Nevertheless, to the best of our knowledge, clear evidence supporting the use of ultrasound to select the lower thoracic parietal pleura as an appropriate biopsy site does not currently exist. The aim of the present study was to analyze whether selecting the point of entry of the CPB using ultrasound influences the diagnostic yield in patients with MPE independently of the presence of thickened or diseased pleura.

METHODS

Study subjects

All patients who underwent CPB for exudative PE at the Unit of Interventional Bronchopleural Pathology in the Pneumology Department of the University Hospital Complex of Vigo (CHUVI) were included in this study. All of the CPB were performed by a same pulmonologist with extensive experience in the management of pleural disease or by a fellow in training (supervised by the expert), both of whom followed the recommendations of published guidelines [1,2,13]. In all cases at least one sample of pleural specimen was obtained. Between 2008 and 2010, a biopsy site in the lower region was selected by thoracic ultrasound. The results were compared with a historical series of CPB that were performed without the assistance of thoracic ultrasound between 2005 and 2007; in this series, the entry point was chosen based on physical examination (percussion and auscultation) [13].

Approach to the patient

An initial diagnostic thoracentesis for biochemical, microbiological, and cytological studies was performed in all patients. If a diagnosis was not obtained after this test, a second cytology and a CPB with an Abrams needle were performed in patients with exudative PE. The technique used for CPB was similar, and the Abrams needle was always used. The CPB was performed with the patient sitting with his or her back vertical and with the arm of the side containing the fluid placed over the opposite shoulder. The entry point was chosen

based on physical examination (percussion and auscultation) between 2005 and 2007. In the other group the thoracic ultrasound was realized to locate the point of entry lower.

After the site was selected, the skin was cleaned and local anesthesia administered (2% mepivacaine). At least four separate biopsy specimens were obtained, placed in formalin, and taken to the pathology department; one specimen was placed in a sterile tube and sent to be cultured for mycobacteria.

A chest radiograph was obtained after the CPB to verify that no pneumothorax had occurred. In some patients, in whom the cause of PE had still not been identified with CPB, a thoracoscopy was conducted; in others a clinical and radiological follow-up of at least one year were undertaken to demonstrate no symptoms or recurrence of PE [14]. The decision to use one option or the other depended on the pulmonologist for the patient.

The etiology of the PE was determined based on accepted criteria, as described by the Society of Spanish Pneumology and Thoracic Surgery (SEPAR) [1,14].

The clinical and epidemiological characteristics were recorded. For classification of the radiological characteristics of the PE, the following criteria were used: (a) Size; classified as PE >two-thirds when it produced opacification of the entire hemithorax or the fluid reached the arch of the aorta, and as PE <two-thirds when it did not reach this threshold. (b) Distribution; classified as free PE when it was mobile in the lateral decubitus on the chest radiograph, and as loculated when it was immobile. (c) The presence or absence of pleural thickening >5 mm revealed by CT.

With respect to the results of the CPB, an adequate pleural biopsy specimen was defined as evidence of pleural tissue in the sample. TPE was diagnosed if a microbiology smear or cultures from the pleural tissue were positive for acid-fast bacilli, or if noncaseating granulomas were present in patients with lymphocytic predominant effusion who responded to anti-tuberculosis therapy and who did not have other pleural granulomatous diseases. The presence of malignant cells in the pleural tissue established cancer as the etiology. Complications of CPB were registered in both series.

The local Ethical Committee approved this study and all patients provided informed consent.

Statistical analysis

The global results are reported as percentages and absolute frequencies for the qualitative variables and as the mean value and standard deviation (SD) for the quantitative variables. Fischer's exact test was used to compare qualitative variables. The analyses were performed with the program Statistical Package for Social Sciences version 14.0 (SPSS, Chicago, IL, USA).

RESULTS

Patient characteristics

A total of 181 patients underwent CPB during the study period. Of these, 114 patients underwent ultrasound-assisted CPB between 2008 and 2010, and 67 patients CPB without ultrasound-assisted between 2005 and 2007 (control group). The mean (SD) age of the patients was 61.5 ± 19 years, and 61.9% of the patients were men. The etiologies of the PE are listed in Table 1 ($p=0.7$). Diagnostic thoracoscopies were performed in 13 (11.4%) patients who underwent ultrasound-assisted CPB and in 6 (9%) patients from the control group. Four (6%) patients in the CPB group without ultrasound and 7 (6.1%) patients in the ultrasound-assisted CPB group were followed up for a minimum of 12 months. These cases were deemed "reactive PE".

In the group of patients who underwent ultrasound-assisted CPB, 27.2% (31/114) had MPE, and 22.8% had TPE (19 with a microbiology smear or culture positive for acid-fast bacilli or the presence of noncaseating granulomas in the pleural tissue; the remainder responded to antituberculosis therapy without recurrence of PE). In the group who underwent CPB without ultrasound, 29.9% (20/67) had MPE and 23.9% (16/61) had TPE (12 patients with a definitive diagnosis, and four who were treated empirically without recurrence of PE).

In the group of CPB performed without ultrasound-assistance, in 6 patients there was no chest radiograph information and in 6 no CT. In the group of ultrasound-assisted CPB, in 5 patients there was no information of the chest radiograph and in 20 cases no information of CT. There were no differences in terms of the radiological characteristics of the PE (Table 2).

Diagnostic yield of closed pleural biopsy and complications

Adequate pleural biopsy specimens were obtained in 96.5% of the ultrasound-assisted CPB and in 89.6% of the historical control group ($p = 0.06$). The diagnostic yield of the ultrasound-assisted CPB for TPE was 91.7% (17/19), compared with 89.5% (11/12) for the group without ultrasound ($p = 0.8$). For patients with MPE, ultrasound-assisted CPB was diagnostic in 77.4% (24/31), whereas CPB without ultrasound was diagnostic in 60% (12/20) ($p = 0.18$). The diagnostic yield of the ultrasound-assisted Abrams needle increased by more than 17% for MPE. The final diagnoses established for MPE with an Abrams pleural needle in each of the groups are presented in Table 3.

No major complications (major haemorrhage, sepsis, or death) were documented. Pneumothorax was experienced by 2.5% (3/114) of the patients in the ultrasound-assisted CPB group and by 1.5% (1/67) in the control group ($p = 0.9$). Only one patient required a pleural drainage system (in the ultrasound-assisted CPB group).

DISCUSSION

This study demonstrates that choosing an entry point with the assistance of thoracic ultrasound for CPB with an Abrams needle appears to produce an increase, albeit without reaching statistical significance, in the acquisition of adequate pleural biopsy specimens, which should increase the diagnostic yield of MPE. One possible explanation for these results is that the ultrasound enables biopsies to be performed in the lower thoracic parietal pleura, where the secondary spread from pleural metastases is more likely to be initially found [12,15].

A PB can be performed by different methods: blind, image guided, or thoracoscopy guided [1,2,16-18]. The optimal method for obtaining pleural tissue and a diagnosis in patients with exudative PE and unknown etiology is controversial [4]. A significant benefit of thoracoscopy is the ability to obtain a diagnosis, drain the effusion, and perform a pleurodesis during the same procedure [17]. However, thoracoscopy is more expensive and time consuming than

other procedures. Various closed pleural biopsy needles were described, including the Abrams, Cope or Vim-Silverman needles and cutting needle biopsy (e.g Tru-cut). Several studies have revealed the importance of performing image-guided PB with CT or ultrasound. This technique (ultrasound) should be considered, given its lower costs, relatively high safety profile, and simplicity. Previous studies have demonstrated that image-guided pleural biopsy provides the highest diagnostic accuracy.[6-9] Image-guided PB with a Tru-Cut needle provides the highest sensitivity, reaching 70% when performed with ultrasound-guided pleural biopsy and 87% when performed with CT-guided cutting-needle biopsy [8,9]. Specially in the presence of pleural masses, thickening or nodularity, CT or ultrasound guided CPB with Tru-cut should be performed. The Abrams needle is specially indicated in pleural effusion without pleural thickening or nodularity [4].

Metintas et al. did not find differences in the sensitivities of medical thoracoscopy and CT scan-guided Abrams pleural needle biopsy when diagnosing patients with MPE [6]. The diagnostic sensitivities were 94% and 87%, respectively. It should be noted, however, that the majority of these studies included patients with PE and pleural thickening due to malignant mesothelioma [6-8,10].

Image-guided CPB is the technique of choice, with a high diagnostic yield, in patients with masses or diffuse, nodular pleural thickening [4,6,8,9,16]. Mesothelioma is the MPE that is included most frequently in CPB studies, but this does not reflect the patient population who took part in the present study in our institution [6-8,10]. The incidence of mesothelioma in our study was low, and image-guided pleural biopsy has been demonstrated to have the highest diagnostic accuracy for mesothelioma [10].

The role of CPB in diagnosing MPE has been questioned because its diagnostic sensitivity is less than that of image-guided and thoracoscopic pleural biopsies [4,5]. For the diagnosis of PE with apparent diffuse pleura, such as that observed in TPE, CPB should be the technique of choice [19]. Prior study indicated that ultrasound guided pleural biopsied with an Abrams needle are more likely to contain pleural samples and have a significantly higher diagnostic sensitivity for pleural tuberculosis [12]. But for those cases with partially affected pleura or

pleural thickening, such as those observed in MPE, other techniques should be performed. Another reason for the low diagnostic yield of CPB is that the pleural malignant deposits tend to be predominantly located near the midline and diaphragm, which are areas that should be avoided when performing an Abrams biopsy [2,5]. The direction of carcinomatous invasion is upward towards the costal pleura. Canto et al. reviewed 203 diagnostic thoroscopies in patients with MPE to determine the different locations of the pleural metastases; they found that 84% of the metastases were in the lower portions of the hemithorax and only 53% of the patients had costal pleural involvement [15].

In a study with 89 patients, Koegelenberg et al. found that ultrasound-assisted CPB performed with an Abrams needle had a significantly higher diagnostic sensitivity for pleural TPE than Tru-Cut needle biopsies [12]. MPE was diagnosed in 12 patients. The Abrams needle biopsies yielded histological confirmation in 83.3% of the samples [12]. One possible explanation for the high yield is that the researchers utilized low biopsy sites, as the lower thoracic parietal pleura (close to the diaphragm) is more likely to contain the secondary spread from visceral pleural metastases. Such an approach is possible with ultrasound assistance, but not with digital percussion as a guide. Unlike our study, there was a clinical suspicion of tuberculosis in the patients enrolled in Koegelenberg et al.'s study without an initial suspicion of MPE. In addition, the aim of their study was different. We believe that a thoracic ultrasound before CPB (ultrasound-assisted CPB) would allow lower (supra-diaphragmatic) biopsy sites to be selected than can be selected with auscultation or percussion; this zone is more likely to present secondary spread from visceral pleural metastases [4,12]. This site selection might improve the diagnostic yield of CPB with an Abrams needle for the diagnosis of MPE, as shown in our study (Figure 1).

The complication rates for image-guided PB range from none to 10%. The risk of complications is lower than with blind biopsy [2,4,16,20]. Although they were not the primary focus of this study, serious complications, such as hemothorax or lacerations of the spleen or kidney, did not occur in either of the groups. The percentage of pneumothorax was greater in

the group with US-assisted CPB, which might be in relation with a greater percentage of cases with PE <two-thirds in the chest radiograph.

To our knowledge, this study is the first to perform a direct comparison of the diagnostic yield of CPB and ultrasound-assisted Abrams needle biopsies in a group of patients that were not selected with exudative PE and with no differences in radiological characteristics or pleural thickening. A possible limitation of this study is that the increase in the acquisition of adequate pleural biopsy specimens should lead to a progressive increase in the experience of the operator. Nevertheless, the pleural biopsies were performed by an experienced physician who completed more than 200 procedures before 2007, and the current evidence is that the diagnostic yield of the technique does not seem to depend greatly on the experience of the operator.[18] In our study, we did not find any significant differences in the characteristics of the two groups, but the diagnostic yield of MPE increased to 17% in the group of patients who underwent ultrasound-assisted CPB.

CONCLUSIONS

In conclusion, although CPB is less sensitive than thoracoscopy or image-guided pleural biopsy in the diagnosis of MPE, selection of the place of entry in the pleural cavity by thoracic ultrasound before performing CPB with an Abrams needle may improve the acquisition of adequate pleural biopsy specimens, without reaching statistical significance compared with a physical examination using digital percussion or auscultation, independently of the existence of masses or pleural thickening. The ultrasound-assisted method has a higher diagnostic sensitivity for MPE.

REFERENCES

1. Villena Garrido V, Ferrer Sancho J, Hernández Blasco L, de Pablo Gafas A, Pérez Rodríguez E, Rodríguez Panadero F, et al; Áreas de Técnicas y Trasplantes. SEPAR. Diagnóstico y tratamiento del derrame pleural. Sociedad Española de Neumología y Cirugía Torácica. Arch Bronconeumol 2006;42 (7):349-372.
2. Hooper C, Lee YC, Maskell N. Investigation of a unilateral pleural effusion in adults: British Thoracic Society pleural disease guideline 2010. Thorax 2010; 65(suppl 2): ii4-ii17.
3. Roberts ME, Neville E, Berrisford RG, Antunes G, Ali NJ . BTS pleural disease guideline group. Management of a malignant pleural effusion: British Thoracic Society pleural disease guideline 2010. Thorax 2010; 65(suppl 2): ii32-ii40.
4. Koegelenberg CFN, Diacon AH. Pleural controversy: close needle pleural biopsy or thoracoscopy- which first?. Respirology 2011;16(1):738-746.
5. Ahrar K, Wallace M, Javadi S, Guptas S. Mediastinal, hilar, and pleural image-guided biopsy: current practice and techniques. Semin Respir Crit Care Med 2008;29 (4):350-360.
6. Metintas M, Ak G, Dundar E, Yildirim H, Ozkan R, Kurt E, et al. Medical thoracoscopy vs CT scan-guided Abrams pleural needle biopsy for diagnosis of patients with pleural effusions. Chest 2010;137(6):1362-1368.
7. Adams RF, Gleeson FV. Percutaneous image-guided cutting-needle biopsy of the pleura in the presence of a suspected malignant effusion. Radiology 2001;219(2):510-514.
8. Maskell NA, Gleeson FV, Davies RJO. Standard pleural biopsy versus CT-guided cutting-needle biopsy for diagnosis of malignant disease in pleural effusions: a randomised controlled trial. Lancet 2003;361(9366):1326-1331.
9. Chang DB, Yang PC, Luh KT, Kuo SH, Yu CJ. Ultrasound-guided pleural biopsy with tru-cut needle. Chest 1991;100(5):1328-1333.

10. Adams RF, Gray W, Davies RJ, Gleeson FV. Percutaneous image-guided cutting needle biopsy of the pleura in the diagnosis of malignant mesothelioma. *Chest* 2001;6;120:1798-1802.
11. Janssen JP. Why you do or do not need thoracoscopy. *Eur Respir Rev* 2010;19(117):213-216.
12. Koegelenberg CFN, Bollinger CT, Theron J, Walzl G, Wright CA, Louw M, Diacon AH. A direct comparison of the diagnostic yield of ultrasound-assisted Abrams and tru-cut needle biopsies for pleural tuberculosis. *Thorax* 2010;65(10):857-862.
13. Light RW, Lee YCG, editors. *Textbook of pleural diseases*. Second edition. London: Hodder Arnold; 2008.
14. Villena V, López-Encuentra A, Echave-Sustaeta J, Martín-Escribano P, Ortuño-de-Solo B, Estevez-Alfaro J. Diagnostic value of CA 549 in pleural fluid. Comparison with CEA, CA 15.3 and CA 72.4. *Lung Cancer* 2003;40(3):289-294.
15. Canto A, Rivas J, Saumench J, Morera R, Moya J. Points to consider when choosing a biopsy method in cases of pleurisy of unknown origin. *Chest* 1983;84(2):176-179.
16. Rahman NM, Gleeson FV. Image-guided pleural biopsy. *Curr Opin Pulm Med* 2008;14(4):331-336.
17. Rahman NM, Ali NJ, Brown G, Chapman SJ, Davies RJO, Downer NJ, Gleeson RV, et al. BTS pleural disease guideline group. Local anaesthetic thoracoscopy: British Thoracic Society pleural disease guideline 2010. *Thorax* 2010;65 (suppl 2):ii54-ii60.
18. Chakrabarti B, Ryland I, Sheard J, Warburton CJ, Earis JE. The role of Abrams percutaneous pleural biopsy in the investigation of exudative pleural effusions. *Chest* 2006;129(6):1549-1555.
19. Diacon AH, Van de Wal BW, Wyser C, Smedema JP, Bezuidenhout J, Bollinger CT, Walzl G. Diagnostic tools in tuberculous pleurisy: a direct comparative study. *Eur Respir J* 2003;22(4):589-591.
20. Matin TN, Gleeson FV. *Interventional radiology of pleural diseases*. *Respirology* 2011;16(3):419-429.

Figure 1. Choice of entry point in the pleural space. Ultrasound enables biopsies to be performed in the lower thoracic parietal pleura, in contrast to biopsies guided by auscultation or percussion.

Table 1. Etiology of pleural effusion in patients who underwent closed pleural biopsy or ultrasound-assisted closed pleural biopsy.

	CPB	US-assisted CPB
Tuberculous PE	16 (23.9%) [^]	26 (22.8%) ^{^^}
Malignant PE	20 (29.9%)	31 (27.2%)
Parapneumonic PE	2 (3%)	1 (0.9%)
Non-malignant PE ⁺		
Idiopathic PE	6 (9%)	13 (11.4%)
Reactive PE	4 (6%)	7 (6.1%)
Transudative	1 (1.5%)	3 (2.7%)
Miscellaneous	5 (7.5%)*	6 (5.2%)**
Not diagnostic	13 (19.4%)	27 (23.7%)

CPB, closed pleural biopsy; PE, pleural effusion; US, ultrasound

⁺Nonmalignant PE of unknown origin in patients with any of the following criteria: (1) nonspecific pleuritis observed at thoracoscopy, thoracotomy, or autopsy (idiopathic PE); (2) absence of symptoms or recurrence of PE during the 1-year follow-up period (reactive PE).

[^]Twelve patients had a positive stain or culture for *Mycobacterium tuberculosis* or typical caseating granulomas in the pleural biopsy. The remainder were treated empirically for pleural tuberculosis without recurrence of the effusion.

^{^^}Nineteen patients had a definitive diagnosis. The remainder were treated empirically without recurrence of the effusion.

*One patient (1.5%) with pericardial disease, two (3%) with collagen vascular disease, one (1.5%) with subphrenic abscess, and one (1.5%) with amyloidosis.

**One patient (0.9%) with pericardial disease, one (0.9%) with PE due to drug reactions, one (0.9%) with iatrogenic PE, two (1.8%) with uremic pleuritis, and one (0.9%) with PE due to collagen vascular disease.

Table 2. Radiological characteristics of pleural effusion.

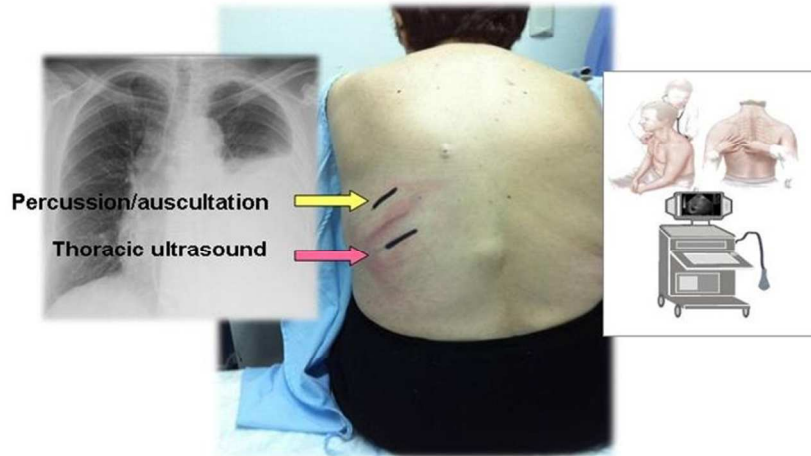
Radiology	CPB, <i>n</i> (%)	US-assisted CPB, <i>n</i> (%)	<i>p</i>
Extent of PE			
≥2/3	17 (25.4%)	30 (26.3%)	0.9
<2/3	46 (68.7%)	81 (71.1%)	
Distribution			
Free	55 (82.1%)	106 (93%)	0.07
Loculation	6 (9%)	3 (2.6%)	
Pleural thickening on CT			
Yes	7 (10.4%)	15 (13.2%)	0.4
No	54 (80.6%)	79 (69.3%)	

CPB, closed pleural biopsy; PE, pleural effusion; US, ultrasound; CT, computed tomography

Table 3. Final diagnosis established for malignant pleural effusions using an Abrams pleural needle in each of the groups.

CPB (<i>n</i> = 12)		US-assisted CPB (<i>n</i> = 24)	
Malignant pleural effusion	<i>n</i> (%)	Malignant pleural effusion	<i>n</i> (%)
Lung adenocarcinoma	4 (33.3%)	Lung adenocarcinoma	10 (41.4%)
T cell lymphoma	2 (16.6%)	Breast carcinoma	5 (20.8%)
Mesothelioma	1 (8.3%)	Metastatic adenocarcinoma	2 (8.3%)
Gastrointestinal carcinoma	1 (8.3%)	Other lung carcinomas	2 (8.3%)
Metastatic adenocarcinoma	1 (8.3%)	Mesothelioma	1 (4.2%)
Lung squamous cell carcinoma	1 (8.3%)	T-cell lymphoma	1 (4.2%)
Leukaemia	1 (8.3%)	Lung squamous cell carcinoma	1 (4.2%)
		Ovarian carcinoma	1 (4.2%)
		Colon carcinoma	1 (4.2%)

CPB, closed pleural biopsy; US, ultrasound



Choice of entry point in the pleural space. Ultrasound enables biopsies to be performed in the lower thoracic parietal pleura, in contrast to biopsies guided by auscultation or percussion.
254x190mm (96 x 96 DPI)