RESPIRATORY CARE Paper in Press. Published on May 31, 2016 as DOI: 10.4187/respcare.04662

Obstructive Fibrinous Tracheal Pseudomembrane After Endotracheal Intubation

Inderpaul Singh Sehgal MD DM, Sahajal Dhooria MD DM, Amanjit Bal MD, Ashutosh N Aggarwal MD DM, Digambar Behera MD, and Ritesh Agarwal MD DM

Obstructive fibrinous tracheal pseudomembrane (OFTP) is an uncommon complication that results after tracheal intubation. Herein, we perform a systematic review of the PubMed and EmBase databases for all the cases describing OFTP. The systematic search yielded 28 citations describing 53 subjects with OFTP. The study population (61.1% females) comprised of both adults and pediatric subjects with a median (IQR) age of 40.5 (14.8–60.5) years. The median (IQR) size of endotracheal tube was 7.5 (6–9.3) mm with a median (IQR) duration of intubation of 36 (14–96) hours. The median (IQR) time to onset of symptoms after extubation was 24 (6–96) hours. Stridor was the most common symptom. The average delay in correctly identifying the OFTP was 26 hours. The diagnosis of tracheal pseudomembrane was confirmed by flexible bronchoscopy in 38 (70.4%) instances while rigid bronchoscopy was used in 46.3% subjects for removing the pseudomembrane. There were two deaths, one each in an adult and a pediatric subject. OFTP is a complication of tracheal intubation and presents with respiratory failure. The diagnosis can be confirmed by flexible bronchoscopy. Treatment involves removal of the obstructing membrane with either flexible or rigid bronchoscopy. *Key words: endotracheal intubation; tracheal membrane; post intubation stenosis; tracheal pseudomembrane; rigid bronchoscopy; upper airway obstruction.* [Respir Care 0;0(0):1–•. © 0 Daedalus Enterprises]

Introduction

Endotracheal intubation is a procedure performed for a myriad of indications, including administration of general anesthesia, airway protection, management of acute respiratory failure, and others.[1,2] Endotracheal intubation is associated with several complications, including injury to vocal cords, tracheal ulceration, laryngeal edema, post-intubation tracheal stenosis, and tracheomalacia.[3] Obstructive fibrinous tracheal pseudomembrane (OFTP) is an uncommon complication of endotracheal intubation that can result in failure of extubation.[4-7] The symptoms are nonspecific (cough, hoarseness of voice, stridor, and respiratory distress) and can mimic a plethora of conditions, such as laryngeal spasm, laryngeal edema, vocal cord palsy, vocal cord dysfunction, heart failure, and retention of tracheobronchial secretions.[5-7] A delay in making the correct diagnosis has been reported to result in respiratory failure that requires re-intubation and may occasionally lead to death.[5-7] Treatment involves confirmation by flexible bronchoscopy and removal of the membrane using either rigid or flexible bronchoscopy.[6-8] Herein, we present an illustrative case and perform a systematic review of literature on obstructive tracheal pseudomembrane that complicates tracheal intubation.

A 5-y-old male child was intubated and mechanically ventilated for 3 d for acute viral meningitis. After extubation, the patient complained of difficulty in breathing and was re-intubated. He was then managed with inhaled and systemic corticosteroids. Three days after the second in-

Drs Sehgal, Dhooria, Aggarwal, Behera, and Agarwal are affiliated with the Department of Pulmonary Medicine and Dr Bal is affiliated with the Department of Histopathology, Postgraduate Institute of Medical Education and Research, Chandigarh, India.

Supplementary material related to this paper is available at http://www.rcjournal.com.

The authors have disclosed no conflicts of interest.

Correspondence: Ritesh Agarwal MD DM, Department of Pulmonary Medicine, Postgraduate Institute of Medical Education and Research, Sector-12, Chandigarh-160012, India. E-mail: agarwal.ritesh@outlook.in.

DOI: 10.4187/respcare.04662

Copyright (C) 2016 Daedalus Enterprises ePub ahead of print papers have been peer-reviewed, accepted for publication, copy edited and proofread. However, this version may differ from the final published version in the online and print editions of RESPIRATORY CARE

RESPIRATORY CARE Paper in Press. Published on May 31, 2016 as DOI: 10.4187/respcare.04662

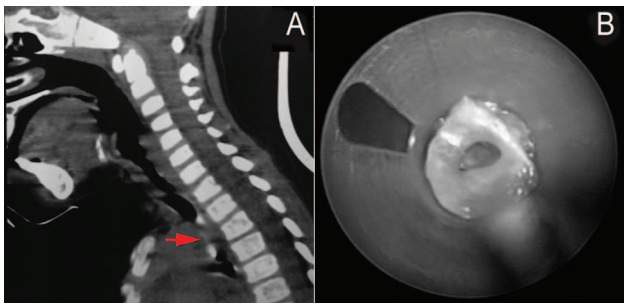

Fig. 1. A: Contrast-enhanced computed tomography of the neck revealing narrowing of the tracheal lumen by a soft tissue swelling in the subglottic region. B: Tracheal pseudomembrane visualized during rigid bronchoscopy causing 80% occlusion of the tracheal lumen.

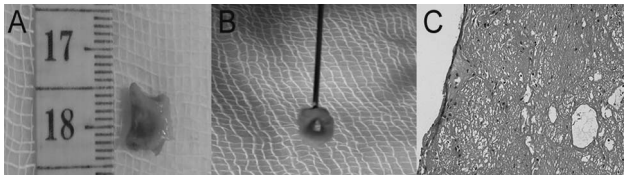

Fig. 2. A and B: Fleshy membrane with a narrow lumen after removal. C: Photomicrograph showing the ulcerated tracheal lining epithelium with subepithelium demonstrating fibrinous exudate without significant inflammatory infiltrate (hematoxylin and eosin stain, ×200).

tubation, he was extubated and was discharged the subsequent day. The next day, he again developed respiratory distress. Computed tomography of the neck revealed diffuse circumferential edema and narrowing of the airway at the level of T3 spine (Fig. 1). He was treated with inhaled epinephrine along with inhaled budesonide (0.5 mg) and intravenous dexamethasone (4 mg). However, his condition deteriorated, and he was referred to our center for further management. On admission, the child was tachypneic and had stridor. Arterial blood gas analysis revealed hypoxemia (pH 7.45; P_{aO_2} = 78 mm Hg; P_{aCO_2} = 34.2 mm Hg) on room air. A provisional diagnosis of post-intubation tracheal stenosis was considered, and an urgent rigid bronchoscopy was performed. After general anesthesia with sevoflurane and propofol, the child was intubated with a rigid tracheobronchoscope (size 4.5; Karl Storz, Berlin, Germany) with an internal diameter of 6.6 mm and an outer diameter of 7.3 mm. A membranous structure was identified around 2 cm from the vocal cords occluding the tracheal lumen by 80–90% (see Fig. 1). The rigid barrel was advanced further, and the membrane was gently dislodged with the barrel of the rigid scope and was pushed into the right main bronchus. The membrane was subsequently removed using the optical grasping forceps. The membrane was fleshy in nature and had a length of around 8–9 mm with a narrow lumen (Fig. 2). Flexible bronchoscopy performed the next day revealed remnant inflammation in the posterolateral wall of the trachea with no evidence of a membrane or luminal occlusion. Histopathological examination of the membrane showed a pseudomembrane composed of fibrin, necrotic material, and leukocytes (see Fig. 2). The child was discharged and is doing well at follow-up.

Methods

Search Strategy

We searched the PubMed and EmBase databases for articles published until October 15, 2015, describing OFTP using the free text terms: tracheal intubation complications AND membrane OR pseudomembrane OR obstructive fibrinous tracheal pseudomembrane OR tracheal membrane following endotracheal intubation OR membranous tracheitis OR pseudomembranous tracheal stenosis OR bridge-like subglottic stenosis. We reviewed the reference lists of all of the included articles and previous review articles. In addition, we searched our personal files.

Inclusion Criteria

We included full-text, peer-reviewed, cross-sectional studies, cohort studies, case reports, and abstracts that described the entity of OFTP. We excluded the following studies: (1) comments, editorials, and reviews; (2) studies published in non-English languages; (3) animal studies; and (4) studies describing tracheal pseudomembrane due to infection. For the current analysis, the pediatric age group was defined as subjects <18 y old.

Initial Review of Studies

The database thus created from the electronic searches was assimilated in the reference manager package Endnote X7.4 (Thomson Reuters, New York), and all duplicate citations were discarded. Two authors (ISS and RA) then screened these citations by review of the title and abstract to identify the relevant studies. Any disagreement was resolved by discussion between the authors. This database was then scrutinized again to include only primary articles. The full text of each of these studies was obtained and reviewed in detail.

Study Selection and Data Abstraction

Two authors (ISS and RA) independently assessed all of the articles for inclusion in the systematic review and extracted the data; the data were entered into a standard data extraction form. The following items were extracted: (1) publication details (authors, year of publication); (2) study design (prospective, retrospective, or case report); (3) number of subjects (including the demographic profile) and

Copyright (C) 2016 Daedalus Enterprises ePub ahead of print papers have been peer-reviewed, accepted for publication, copy edited and proofread. However, this version may differ from the final published version in the online and print editions of RESPIRATORY CARE

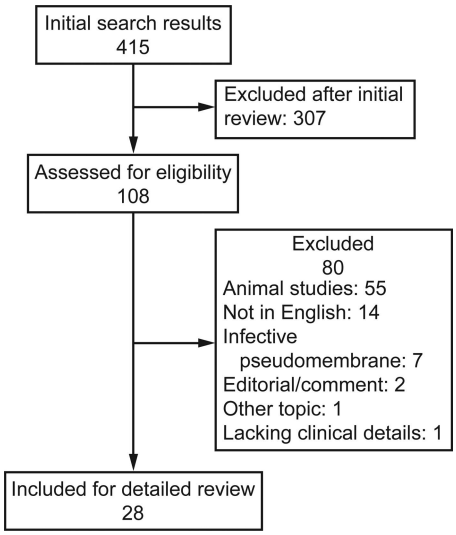

Fig. 3. Flow chart.

inclusion criteria; (4) details about sex, age, indication for intubation, and the type of endotracheal tube (ETT) used; (5) duration of intubation, cuff pressure; (6) time of onset of symptoms after extubation and the symptoms reported; (7) treatment given before the identification of correct diagnosis; (8) method of confirming the diagnosis of tracheal pseudomembrane and time delay in making the correct diagnosis; (9) details of the management of tracheal pseudomembrane; and (10) the final outcome. Any differences in the study selection and data extraction process between the 2 authors were resolved by discussion.

Statistical Analysis

Data from all individual subjects (case reports or case series) were entered into a spreadsheet (Excel 2016, Microsoft Corp, Redmond, Washington). Data were analyzed using the commercial statistical package SPSS 22 (IBM Corp, Armonk, New York) and are presented in a descriptive fashion as proportions, mean (95% CI), or median (interquartile range [IQR]). A subgroup analysis of pediatric and adult subjects was also performed. Chi-square and Mann-Whitney U tests were used to compare the categorical and numerical data, respectively. A P value of $\leq$.05 was considered significant. An institutional ethics committee approval was not required because this was a systematic review of published data.

Results

The initial database search yielded 415 studies, of which 307 studies were excluded after initial review (Fig. 3). One hundred eight studies were assessed for eligibility, and finally 28 studies were included in the current systematic review (see the supplementary materials at http://www.rcjournal.com).[4-31]

Demographic Characteristics

A total of 54 subjects (including the illustrative case), both adult (n = 39) and pediatric (n = 15), with an age range of 2 months to 85 y were identified. The median age of the study population (61.1% females) was 40.5 (IQR 14.8–60.5). The most common indication for endotracheal intubation was induction of general anesthesia for surgical procedures followed by acute hypoxemic respiratory failure (Table 1). In the pediatric age group, the most common indication was administration of general anesthesia for surgical interventions, whereas in adults, acute hypoxemic respiratory failure formed the most frequent indication (Table 2).

ETT Attributes

Various types of ETTs were used for intubation, including cuffed rubber tubes, cuffed silicone tubes, and uncuffed silicone tubes. Cuffed ETTs were used in 37.7%, whereas cuffed high volume, low pressure, and uncuffed endotracheal tubes were used in 22.6 and 20.8% of the study population, respectively. An uncuffed ETT was used in all pediatric subjects. Intubation was traumatic in 9 subjects. The median (IQR) size of the ETT was 7.5 (6–9.3) mm. The information regarding ETT cuff pressure was available for 12 subjects, and the pressure was maintained at $<$25 cm H_2O in 11 of these subjects. In 3 other subjects, the ETT cuff was not inflated. The median (IQR) duration of intubation was 36 (14–96) h. Ten subjects had an ETT dwelling time of $\leq$5 h. There was no difference in the duration of intubation in the pediatric and the adult age group (see Table 2).

Presentation of OFTP

The median (IQR) time to onset of symptoms after extubation was 24 (6–96) h. The median time to onset of symptoms was significantly shorter in pediatric subjects (6 h vs 30 h in pediatric vs adult subjects, respectively, P = .002). In 5 subjects (including the index case), the symptoms manifested immediately after extubation. Stridor was the most common symptom, and unrelenting cough and hoarseness of voice were the other symptoms reported by the subjects. In 17 subjects, the tracheal pseudomembrane resulted in respiratory failure, resulting either in re-intubation or definitive treatment. In most of the subjects, the symptoms were attributed to laryngeal edema. Respiratory failure at presentation was more frequently present in pediatric than in adult subjects (53.3% vs 23.1%, P = .032). The information regarding treatment received

Copyright (C) 2016 Daedalus Enterprises ePub ahead of print papers have been peer-reviewed, accepted for publication, copy edited and proofread. However, this version may differ from the final published version in the online and print editions of RESPIRATORY CARE

RESPIRATORY CARE Paper in Press. Published on May 31, 2016 as DOI: 10.4187/respcare.04662

Table 1. Pooled Analysis of Cases Included in the Systematic Review

Parameters	Values
Age, median (IQR) y	40.5 (14.8–60.5)
Female sex, *n* (%)	33 (61.1)
Indication of intubation, *n* (%)	
Post-surgery	21 (38.9)
Acute hypoxemic respiratory failure	19 (35.2)
Acute type II respiratory failure	4 (7.4)
Acute febrile illness	3 (5.6)
Community-acquired pneumonia	3 (5.6)
Trauma	4 (7.4)
Type of endotracheal tube, *n* (%)	
Magill rubber	3 (5.7)
Cuffed	20 (37.7)
High-volume low-pressure	12 (22.6)
Uncuffed	11 (20.8)
Double lumen	1 (1.9)
Tracheostomy	1 (1.9)
Traumatic intubation, *n* (%)	9 (16.7)
Size of endotracheal tube, median (IQR) mm	7.5 (6–9.3)
Cuff pressure, *n* (%)	
<25 cm H_2O	11 (20.8)
>25 cm H_2O	1 (1.9)
Duration of intubation, median (IQR) h	36 (14–96)
Time to onset of symptoms after extubation, median (IQR) h	24 (6–96)
Symptomatic after extubation, *n* (%)	52 (96.3)
Hoarseness	5 (9.3)
Stridor	40 (74.1)
Cough	7 (13)
Respiratory failure, *n* (%)	17 (31.5)
Treatment received before diagnosis of OFTP, *n* (%)	
Combined nebulization with bronchodilator and steroids (systemic or nebulized)	21 (38.9)
Re-intubation	11 (20.4)
No treatment	3 (5.6)
Identification of membrane on CT, *n* (%)	11 (20.4)
Time delay in identification of OFTP, median (IQR) h	26 (6–72)
Confirmation of OFTP, *n* (%)	
Flexible bronchoscopy	38 (70.4)
Rigid bronchoscopy	9 (16.7)
Spontaneous expulsion	6 (11.1)
Autopsy	1 (1.9)
Percentage occlusion of tracheal lumen during bronchoscopy, median (IQR) %	80 (70–90)
Treatment given for OFTP, *n* (%)	
Rigid bronchoscopy	25 (46.3)
Flexible bronchoscopy	17 (31.5)
Re-intubation	2 (3.7)
Spontaneous expulsion	6 (11.1)
Tracheostomy/surgical extraction	1 (1.9)
Others (cautery and snaring)	1 (1.9)
No treatment	2 (3.7)
Recurrence of OFTP, *n* (%)	2 (3.7)
Mortality, *n* (%)	2 (3.7)

IQR = interquartile range
OFTP = obstructive fibrinous tracheal pseudomembrane
CT = computed tomography

before the correct diagnosis was available for 35 subjects. Nebulization with bronchodilator (salbutamol), epinephrine, and corticosteroids and/or re-intubation were the treatments provided to subjects before identifying tracheal pseudomembrane as a cause of symptoms.

Diagnosis of OFTP

Computed tomography of the neck and/or thorax was done in 11 subjects (20.4%) and could correctly identify tracheal membrane or mass as a cause of symptoms. In 3 subjects (5.5%), lateral radiograph of the neck revealed abnormality of the trachea and led to confirmation by bronchoscopy. The diagnosis of tracheal pseudomembrane was confirmed by flexible bronchoscopy in 70.4% of the subjects, whereas a rigid bronchoscopy was performed in 16.7% of the subjects to confirm the diagnosis. In 6 subjects, the tracheal pseudomembrane was identified ex vivo after it was spontaneously expulsed, whereas in one subject, it was identified during autopsy. There was a delay in correctly identifying OFTP by a median of 26 h. The tracheal pseudomembrane caused a median (IQR) obstruction of 80% (70–90%) of the tracheal lumen.

Management of OFTP

Rigid bronchoscopy was used in the management of OFTP in 46.3%, whereas a flexible bronchoscopy was used in 31.5% of subjects. In one subject each, tracheostomy and electrocautery with snaring was performed during rigid bronchoscopy to relieve the symptoms.[9,23] Rigid bronchoscopy was used more frequently to relieve the airway obstruction in adults (56.4%), whereas flexible bronchoscopy was used more often in pediatric subjects (60%). Spontaneous expectoration of the membrane was seen in 6 subjects (5 adults, one child).[9,21,26,28,31] Recurrence of symptoms and repeated formation of the tracheal membrane was encountered in 2 subjects (both adults).[4] There were 2 deaths (one each in adult and pediatric subjects): One was due to progression of sepsis, and in another subject, tracheal pseudomembrane was not identified premortem.[5,6]

Copyright (C) 2016 Daedalus Enterprises ePub ahead of print papers have been peer-reviewed, accepted for publication, copy edited and proofread. However, this version may differ from the final published version in the online and print editions of RESPIRATORY CARE

RESPIRATORY CARE Paper in Press. Published on May 31, 2016 as DOI: 10.4187/respcare.04662

Table 2. Comparison of Clinical Characteristics Between Pediatric and Adult Population

Parameters	Pediatric group (n = 15)	Adult group (n = 39)	P
Female sex, n (%)	6 (40)	27 (69.2)	.048
Indication of intubation, n (%)			.001
Surgery	7 (46.7)	14 (35.9)	
Acute hypoxemic respiratory failure	2 (13.3)	17 (43.6)	
Acute febrile illness	3 (20)	0	
Type II respiratory failure	0	4 (10.3)	
Community-acquired pneumonia	3 (20)	0	
Trauma	0	4 (10.3)	
Duration of intubation, median (IQR) h	35 (14–72)	48 (15–132)	.51
Time to onset of symptoms, median (IQR) h	6 (2–18)	30 (18–120)	.002
Tracheal lumen obstruction, median (IQR) %	80 (70–85)	95 (75–100)	.053
Delay in recognition of pseudomembrane, median (IQR) h	24 (4.75–72)	29 (14.8–66)	.82
Respiratory failure, n (%)	8 (53.3)	9 (23.1)	.032
Treatment received before correct diagnosis, n (%)			.034
Supportive care	12 (57.1)	9 (42.9)	
Re-intubation	2 (18.2)	9 (42.9)	
Treatment for management of OFTP, n (%)			.10
Flexible bronchoscopy	9 (60)	8 (20.5)	
Rigid bronchoscopy	3 (20)	22 (56.4)	
Surgery/tracheostomy	0	1 (2.6)	
Re-intubation	1 (6.7)	1 (2.6)	
Spontaneous expulsion	1 (6.7)	5 (12.8)	
No treatment	1 (6.7)	1 (2.6)	

IQR = interquartile range
OFTP = obstructive fibrinous tracheal pseudomembrane

Discussion

The results of the systematic review suggest that OFTP is an uncommon but potentially fatal complication following tracheal intubation. Respiratory failure may be encountered in almost one third of the patients at presentation, which requires urgent intervention. There is usually a delay in correctly diagnosing OFTP due to nonspecific symptoms. The confirmation requires direct visualization of the membrane with either flexible or rigid bronchoscopy. Definitive treatment requires relieving the airway obstruction with bronchoscopic removal of the membrane. A previous systematic review on the same topic was composed of only 24 subjects with only one pediatric subject. The present review has twice the number of subjects with 15 pediatric subjects.

Etsten and Mahler[4] first described OFTP in 3 adult subjects who were intubated with a Magill low pressure rubber endotracheal tube for induction of general anesthesia while surgical interventions were performed. Subsequently, OFTP was described in adults and children who were intubated for a variety of indications, including acute respiratory failure, airway protection, and others.[5,6,10,31] The most common symptoms consist of hoarseness of voice, stridor, or respiratory failure that can occur either immediately or after a few hours to days. Most of these symptoms are nonspecific and can also be seen in laryngeal edema and/or cord paralysis.[4-7,22] Due to missed diagnosis, patients generally receive supportive care in the form of nebulized bronchodilators (salbutamol, adrenaline) and corticosteroids (both systemic and inhaled) or re-intubation before correct diagnosis.[4-8,21,31] There is considerable delay in the diagnosis, which can have unfavorable outcomes, including mortality reported in a case with missed diagnosis.[5] In a systematic review comprising 24 subjects, 96.3% of the subjects were symptomatic; the symptoms generally appeared immediately after extubation but could be delayed as long as 70 d after extubation.[8,18] In the illustrative case presented in the current study, the child developed stridor immediately after extubation and required re-intubation; there was a delay in making the correct diagnosis by 10 d.

The exact etiopathogenesis of OFTP remains unknown, and various hypotheses have been postulated. The subglottic area is the narrowest part of the larynx that is completely surrounded by the cricoid cartilage that forms a rigid circle. Due to this, the subglottic mucosa is vulnerable to injury that may occur during intubation. Initial injury results in accumulation of the desquamated epithelial cells that subsequently form the subglottic membrane.[4]

Copyright (C) 2016 Daedalus Enterprises ePub ahead of print papers have been peer-reviewed, accepted for publication, copy edited and proofread. However, this version may differ from the final published version in the online and print editions of RESPIRATORY CARE

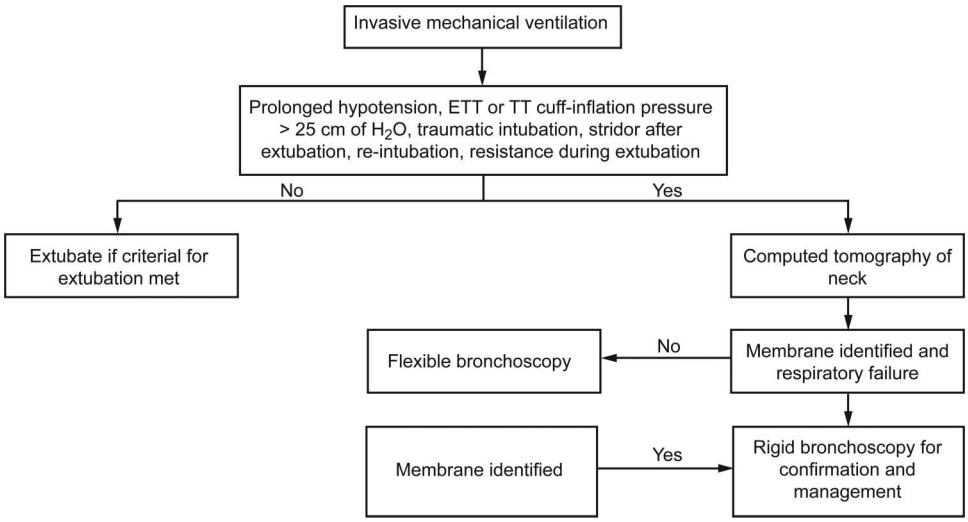

Fig. 4. A proposed algorithm for the diagnosis of obstructive fibrinous tracheal pseudomembrane in the ICU. ETT = endotracheal tube; TT = tracheostomy tube.

This theory is supported by the fact that the most common location of the tracheal pseudomembrane is the subglottic region.[4,10-13] However, in a few other cases, the membrane was located in the mid-trachea, the distal trachea, or the entire length of the trachea.[6,8,14,24] Another theory suggests OFTP to be the first step in the development of tracheal stenosis resulting from ischemic necrosis of tracheal mucosa and submucosa due to inflated endotracheal cuff.[5] However, this logic cannot explain the development of OFTP in subjects where uncuffed endotracheal tubes or high-volume low pressure tubes were used.[4-7,12,13,17,18,22] Further, OFTP has also been reported in subjects where the cuff pressure was maintained below 25 cm H_2O[6,19,22] and in subjects who were intubated for as little as half an hour.[6,13] Aspiration of gastric contents leading to caustic injury has also been proposed as a contributing factor. It is likely that a combination of these factors results in the formation of OFTP after the initial trauma to the tracheal mucosa followed by an aberrant healing process.

The presence of OFTP is confirmed by direct visualization of the membrane during flexible bronchoscopy (Fig. 4). However, flexible bronchoscopy cannot be performed in patients who have severe respiratory distress or respiratory failure. In such cases, computed tomography of the neck and the thorax can provide clues to the cause of the respiratory symptoms. Rigid bronchoscopy is the modality of choice, both for confirming and relieving the upper airway obstruction due to OFTP in patients with respiratory failure, as was done in the illustrative case.

In our opinion, the safest treatment modality for OFTP is rigid bronchoscopy, which should be preferred over flexible bronchoscopy. Rigid bronchoscopy offers several advantages over flexible bronchoscopy. Rigid bronchoscopy allows ventilation during diagnosis and removal of OFTP, thus maintaining airway control at all times. This is important because OFTP causes significant luminal compromise (70–90%), and the introduction of the flexible bronchoscope may further obstruct the airway. Also, in a tachypneic patient, flexible bronchoscopy may worsen the dynamic tracheal obstruction due to a floppy membrane. If the tracheal membrane is large, thick, and adherent, removal and manipulation may not be possible using the flexible bronchoscope.

Conclusions

OFTP can complicate tracheal intubation and can cause respiratory failure. The diagnosis is confirmed by flexible bronchoscopy, whereas mechanical debridement using a rigid bronchoscope should be preferred, wherever available. A high index of clinical suspicion should be maintained for OFTP irrespective of the duration of intubation, type of endotracheal tube used, and the time to onset of symptoms after extubation. This is important because failure to recognize OFTP may be associated with a fatal outcome.

REFERENCES

1. Bickel FG, Freiheit HJ. Indications for endotracheal intubation and a practical technique. Anesth Prog 1966;13(1):7-9.
2. Pierson DJ. Indications for mechanical ventilation in adults with acute respiratory failure. Respir Care 2002;47(3):249-262, discussion 262-245.
3. Stauffer JL, Olson DE, Petty TL. Complications and consequences of endotracheal intubation and tracheotomy: a prospective study of 150 critically ill adult patients. Am J Med 1981;70(1):65-76.
4. Etsten B, Mahler D. Subglottic membrane; a complication of endotracheal intubation. N Engl J Med 1951;245(25):959-960.
5. Deslée G, Brichet A, Lebuffe G, Copin MC, Ramon P, Marquette CH. Obstructive fibrinous tracheal pseudomembrane: a potentially

Copyright (C) 2016 Daedalus Enterprises ePub ahead of print papers have been peer-reviewed, accepted for publication, copy edited and proofread. However, this version may differ from the final published version in the online and print editions of RESPIRATORY CARE

fatal complication of tracheal intubation. Am J Respir Crit Care Med 2000;162(3 Pt 1):1169-1171.
6. Lins M, Dobbeleir I, Germonpré P, Waelput W, Pauwels P, Jorens PG. Postextubation obstructive pseudomembranes: a case series and review of a rare complication after endotracheal intubation. Lung 2011;189(1):81-86.
7. Soong WJ, Jeng MJ, Lee YS, Tsao PC, Yang CF, Soong YH. Pediatric obstructive fibrinous tracheal pseudomembrane: characteristics and management with flexible bronchoscopy. Int J Pediatr Otorhinolaryngol 2011;75(8):1005-1009.
8. Talwar A, Patel N, Omonuwa K, Lisker G. Postintubation obstructive pseudomembrane. J Bronchology Interv Pulmonol 2008;15(2):110-112.
9. Harada Y, Sugimoto Y, Sasaki H. Membranous tracheitis following endotracheal intubation. J Laryngol Otol 1977;91(2):119-126.
10. Harbison J, Collins D, Lynch V, McNicholas WT. Acute stridor due to an upper tracheal membrane following endotracheal intubation. Eur Respir J 1999;14(5):1238.
11. Takanami I. Life-threatening stridor due to membranous tracheitis as a rare complication of endotracheal intubation: report of a case. Surg Today 2003;33(4):285-286.
12. Berger TM, Jöhr M. Subglottic fibrinous cast. Paediatr Anaesth 2005;15(7):622-623.
13. Birch CW, Salkeld LJ. A rare tracheal lesion. Paediatr Anaesth 2005;15(1):73-76.
14. Farr MJ, Cyna AM. Subacute airway obstruction from a tracheal mucosal flap. Anaesthesia 2006;61(3):285-290.
15. Gershman AJ, Githaiga A, Mehta AC. Pseudomembranous tracheal stenosis. J Bronchology Interv Pulmonol 2006;13(2):82-83.
16. Carron KO, Violon D. Postintubation tracheal pseudomembrane. J Bronchology Interv Pulmonol 2007;14(3):210-211.
17. Casoni GL, Coffa A, Gurioli C, Terzitta M, Gambale G, Poletti V. A severe complication of short-term tracheal intubation. Anesth Analg 2007;104(1):232-233.
18. van Dinther JJ, Boudewyns AN, Jorens PG, Van Marck V, Claes J, Van de Heyning PH. Stridor due to a bridge-like subglottic stenosis in a 10-week-old male infant. Int J Pediatr Otorhinolaryngol 2009;73(1):159-162.
19. Kang HH, Kim JW, Kang JY, Kim JS, Kim MS, Kim SS, et al. Obstructive fibrinous tracheal pseudomembrane after tracheal intubation: a case report. J Korean Med Sci 2010;25(9):1384-1386.
20. Rice BL, Culver DA, Lazar CA, Santacruz JF, McCarthy K, Gildea TR. An unusual case of stridor: obstructive fibrinous tracheal pseudomembrane. Chest 2010;138(4):49A.
21. Fiorelli A, Vicidomini G, Messina G, Santini M. Spontaneous expectoration of an obstructive fibrinous tracheal pseudomembrane after tracheal intubation. Eur J Cardiothorac Surg 2011;40(1):261-263.
22. Kim JS, Yu JH, Kim YS, Kim I, Ahn JH. Obstructive fibrinous tracheal pseudomembrane mimicking tracheal stents. Tuberc Respir Dis 2011;71(1):59-61.
23. Rice BL, Culver DA, Santacruz JF, Lazar CA, McCarthy K, Gildea TR. Obstructive fibrinous tracheal pseudomembrane. Ann Thorac Surg 2011;92(6):e115-e117.
24. Vanderheyde K, Pieters T, Rodenstein D. A 19-year-old man with dyspnea and stridor after surgery. Respiration 2011;81(1):63-66.
25. Fiorelli A, Accardo M, D'Elia A, Santini M, Ferraro F. Acute life-threatening airway obstruction with pseudomembrane formation after percutaneous dilational tracheostomy. Anaesth Intensive Care 2012;40(5):904-905.
26. Manassero A, Ugues S, Bertolaccini L, Bossolasco M, Terzi A, Coletta G. A very early stage of obstructive fibrinous tracheal pseudo-membrane formation. J Thorac Dis 2012;4(3):320-322.
27. Yildirim BB, Karalezli A, Hasanoglu HC, Kandemir O. Obstructive fibrinous tracheal pseudomembrane. J Bronchology Interv Pulmonol 2012;19(2):129-131.
28. Crespo-Lessmann A, Torrego-Fernández A. Obstructive inflammatory tracheal pseudomembrane. Arch Bronconeumol 2013;49(9):402-404.
29. Patolia S, Enriquez D, Schmidt F, Quist J. Obstructive fibrinous tracheal pseudomembrane. J Bronchology Interv Pulmonol 2013;20(1):63-65.
30. Trisolini R, Coniglio C, Patelli M. Life-threatening postextubation obstructive fibrinous tracheal pseudomembrane. Ann Thorac Surg 2013;95(4):e103.
31. Nakwan N. Obstructive fibrinous tracheal pseudomembrane: a rare condition in postextubation stridor. Respir Care 2014;59(7):e91-e93.

Copyright (C) 2016 Daedalus Enterprises ePub ahead of print papers have been peer-reviewed, accepted for publication, copy edited and proofread. However, this version may differ from the final published version in the online and print editions of RESPIRATORY CARE