

## Trichoptysis Due to an Intrapulmonary Teratoma

Ritesh Agarwal MD DM, Rajagopala Srinivas MD, and Akshay K Saxena MD

### Introduction

Benign and malignant germ cell tumors are the fourth most common mediastinal tumor in adults. Benign teratomas constitute about 80% of these lesions in adults.<sup>1</sup> By contrast, pulmonary teratomas are extremely rare; 44 cases have been reported in the English-language literature. The classic symptom that suggests an intrapulmonary teratoma is trichoptysis (expectoration of hair),<sup>2</sup> which, though pathognomonic, is seen in only 13% of cases.

### Case Report

A 28-year-old male presented to our clinic with complaints of cough with expectoration, hemoptysis, and worsening breathlessness of 3 months duration. The expectoration was persistent, mucopurulent, had no diurnal or postural variation, and included hairs (trichoptysis). He did not report any history of fever, chest pain, wheeze, anorexia, or weight loss. The patient denied any history of smoking, alcohol, or substance abuse. There was no history of seizures, loss of consciousness, aspiration, or recent surgery.

On evaluation the patient was afebrile, with a respiratory rate of 24 breaths/min, a pulse of 90 beats/min, and blood pressure of 116/80 mm Hg. Auscultation revealed reduced breath sounds in the entire left lung. There were no bronchial breath sounds or adventitious sounds. The rest of the physical examination, including the genital examination, was unremarkable. Chest radiograph showed evidence of a heterogeneous opacity in the left upper and mid-lung zone, with areas of calcification. Computed to-

mography (CT) showed a heterogeneous mass lesion in the left upper lobe and lingula, with solid and cystic components with attenuation values that correspond to calcium and fat (Fig. 1). The mass appeared to be adherent to the mediastinal pleura, but showed no adenopathy, collapse, or effusion.

Ultrasonography of the testis did not reveal any abnormality. Blood, urine, and sputum cultures were sterile. Complete blood count revealed normocytic normochromic anemia, with hemoglobin of 10 g/dL. Serum biochemistry and urine microscopy were normal. The levels of human chorionic gonadotropin (hCG) and alpha fetoprotein were normal.

Fiberoptic bronchoscopy revealed an endobronchial growth in the left main bronchus, with hair-like strands (Figs. 2 and 3). A diagnosis of a benign intrapulmonary teratoma was made, parenteral antibiotics were discontinued, and a cardiothoracic consultation was sought. In view of the characteristic symptomatology and radiologic findings, preoperative biopsy was deemed unnecessary. Intraoperatively, a large 8×7 cm encapsulated cystic mass was found replacing the left upper lobe, lingula, and posterior segment of the left lower lobe. The patient underwent left pneumonectomy with complete resection of the tumor.

The postoperative excised specimen was a mature teratoma, with mature elements that represented all 3 germ cell layers, but with no thymic tissue or evidence of malignancy. The postoperative course was uneventful, and the patient was asymptomatic 11 months after surgery, with no symptomatic or radiologic recurrence.

### Discussion

Compared to testicular tumors, extra-gonadal germ cell tumors are uncommon. Only 3% of all germ cell tumors in adults are extra-gonadal. A smaller percentage (< 2%) are mediastinal. Though it is axiomatic to rule out a gonadal tumor in the presence of a mediastinal germ cell mass, such an occurrence is unusual.<sup>1</sup> Germ cell tumors are thought to arise from pluripotent embryonal cells, and contain derivatives of all 3 germinal layers. They are usually diagnosed in the second to fourth decades of life, and have

---

Ritesh Agarwal MD DM and Rajagopala Srinivas MD are affiliated with the Department of Pulmonary Medicine, and Akshay K Saxena MD is affiliated with the Department of Radiodiagnosis, Postgraduate Institute of Medical Education and Research, Chandigarh, India.

The authors report no conflicts of interest related to the content of this paper.

Correspondence: Ritesh Agarwal MD DM, Department of Pulmonary Medicine, Postgraduate Institute of Medical Education and Research, Sector 12, Chandigarh 160012 India. E-mail: ritesh@indiachest.org; riteshpgi@gmail.com.

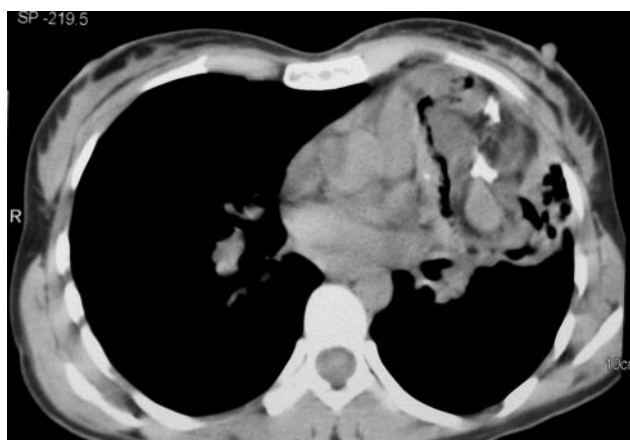

Fig. 1. Computed tomogram showing a heterogeneous mass lesion in the left upper lobe, with calcification, fatty tissue, and solid and cystic components.

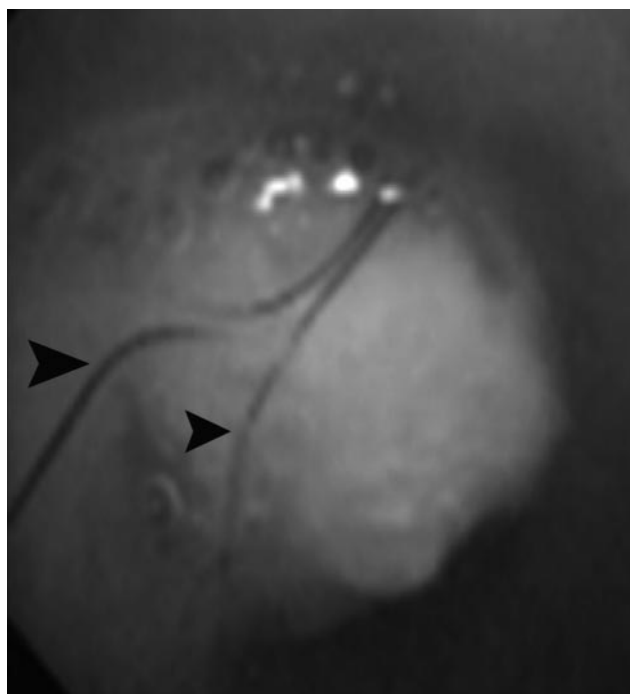


Fig. 2. Fiberoptic bronchoscopy showing an endobronchial growth in the left main bronchus with strands of hair (arrow heads).

no sex predilection. Though germ cell tumors may occur anywhere in the body, in order of decreasing frequency, they occur in the ovary, testis, sacrococcygeal region, and mediastinum.<sup>3</sup> The most common site of origin of an extra-gonadal germ cell tumor in children is the sacrococcygeal area (59.0–64.8%). The most common site of an extra-gonadal germ cell tumor in adults is in the anterior mediastinum. Aberrant migration of the third pharyngeal pouch derivatives can lead to teratomas of the pericardium and the lung.

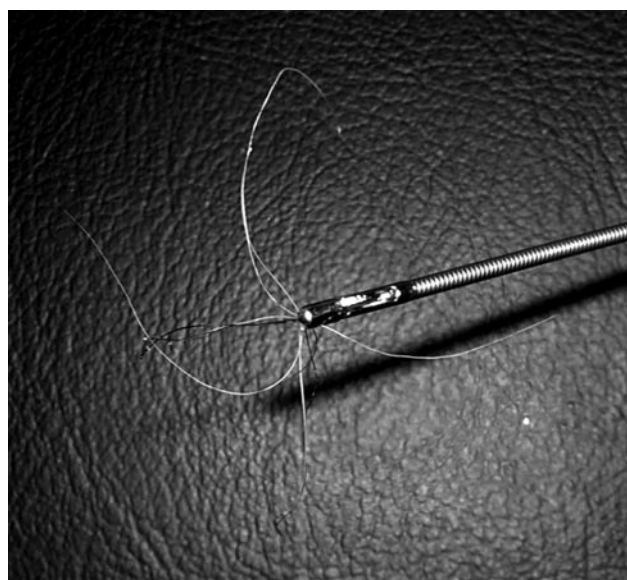


Fig. 3. Endobronchial biopsy forceps with the hair strands extracted from the endobronchial growth.

Mediastinal germ cell tumors can be benign or malignant. The most common of these is the mature cystic teratoma, which accounts for 80% of mediastinal germ cell tumors and 8% of all mediastinal tumors.<sup>1</sup> Malignant germ cell tumors may be seminomas, yolk sac tumors, embryonal cell carcinoma, choriocarcinoma, or malignant teratomas. The anterior mediastinum is the most common site of a benign teratoma, and there have been rare reports of occurrence in the posterior mediastinum and multiple sites. Most patients are asymptomatic at diagnosis. Symptoms occur due to erosion of surrounding structures, and bronchial erosion leads to hemoptysis, trichoptysis, and expectoration of sebaceous material. Rupture into the pericardium may cause tamponade. Rupture into the chest wall or pleura is rare. Release of its fatty component into the bronchial tree may lead to lipoid pneumonia, and rupture into the mediastinum may lead to granulomatous mediastinitis.

As opposed to mediastinal teratomas, primary teratomas of lung parenchyma are very rare.<sup>4</sup> A systematic review reported only 30 cases in the English-language literature up until 1996.<sup>2</sup> Our MEDLINE search with the terms “teratoma,” “lung,” “intrapulmonary teratoma,” and “trichoptysis” yielded an additional 14 English-language reports up until January 2007.<sup>4–18</sup>

These tumors are usually 2.8–5 cm in size, but can be as large as 15 cm. Most arise from the left upper lobe<sup>12</sup> and are reported in patients from age 10 months to 68 years, with no sex predilection. Clinically, patients with intrapulmonary teratomas present with chest pain (52%), hemoptysis (42%), and cough (39%).<sup>5</sup> Trichoptysis is very specific for an intrapulmonary teratoma but trichoptysis is

seen in only 13% of cases.<sup>12</sup> Bronchiectasis and post-obstructive pneumonia occur in 16% of cases and may delay the recognition of the pulmonary tumor.<sup>19</sup>

Benign teratomas may include cystic or solid components. The typical CT feature is an encapsulated mass with a smooth wall and that contains soft tissue, fluid (88%), fat (76%), calcification (53%) or any combination of these.<sup>20</sup> These pathognomonic features are also seen in intrapulmonary teratomas,<sup>3,4</sup> and were observed in our patient. CT is also useful to predict rupture of a mediastinal teratoma. Most unruptured teratomas exhibit homogenous internal density. If rupture occurs, the internal density becomes heterogeneous, with change in margins from smooth to irregular, and the fat component assumes a burst configuration.<sup>21</sup> Magnetic resonance imaging may delineate the anatomic relationships with mediastinal structures and help in planning surgery.

The differential diagnosis of an intrathoracic mass lesion is based on its location. Bronchogenic cysts, lung hamartomas, cystic adenomatoid malformation, and cystic lymphangiomas are differential diagnoses of intrapulmonary masses in children. In adults, teratomas may resemble cavitating bronchogenic carcinoma,<sup>6</sup> especially when hair, teeth, and fat are not visualized radiologically. Tissue diagnosis is obtained when the possibility of teratocarcinoma needs to be excluded.

The treatment of choice for mediastinal teratoma is total excision, as surgical excision achieves total cure. Surgery is necessitated by the symptoms, risk of rupture, need to exclude teratocarcinoma, and the theoretical risk of malignant change. Dense adhesions may be present due to leakage of fat into the mediastinum or the presence of functioning endodermal pancreatic tissue. Though encapsulated, the presence of adhesions may render excision difficult. Lobectomy or pneumonectomy may be required when a teratobronchial communication is present or in the rare instance of an intrapulmonary teratoma.

#### REFERENCES

1. Roberts JR, Kaiser LR. Acquired lesions of the mediastinum: benign and malignant. In: Fishman AF, editor. *Fishman's pulmonary diseases and disorders*. 3 ed. New York: McGraw-Hill;1998:1511–1537.
2. Ustun MO, Demircan A, Paksoy N, Ozkaynak C, Tuzuner S. A case of intrapulmonary teratoma presenting with hair expectoration. *Thorac Cardiovasc Surg* 1996;44(5):271–273.
3. Morgan DE, Sanders C, McElvein RB, Nath H, Alexander CB. Intrapulmonary teratoma: a case report and review of the literature. *J Thorac Imaging* 1992;7(3):70–77.
4. Alper F, Kaynar H, Kantarci M, Onbas O, Polat P, Erdogan F, et al. Trichoptysis caused by intrapulmonary teratoma: computed tomography and magnetic resonance imaging findings. *Australas Radiol* 2005;49(1):53–56.
5. Saini ML, Krishnamurthy S, Kumar RV. Intrapulmonary mature teratoma. *Diagn Pathol* 2006;1:38.
6. Fatimi SH, Sheikh S. Benign intrapulmonary teratoma. *Mayo Clin Proc* 2006;81(10):1284.
7. Groeger AM, Baldi A, Caputi M, Esposito V, Russo P, Severino A, et al. Intrapulmonary teratoma associated with thymic tissue. *Anticancer Res* 2000;20(5C):3919–3922.
8. Asano S, Hoshikawa Y, Yamane Y, Ikeda M, Wakasa H. An intrapulmonary teratoma associated with bronchiectasia containing various kinds of primordium: a case report and review of the literature. *Virchows Arch* 2000;436(4):384–388.
9. Joo M, Kang YK, Lee HK, Lee HS, Yum HK, Bang SW, et al. Intrapulmonary and gastric teratoma: report of two cases. *J Korean Med Sci* 1999;14(3):330–334.
10. Khan JA, Aslam F, Fatimi SH, Ahmed R. Cough, fever and a cavitary lung lesion—an intrapulmonary teratoma. *J Postgrad Med* 2005; 51(4):330–331.
11. Zisis C, Rontogianni D, Stratakis G, Voutetakis K, Skevis K, Argiriou M, et al. Teratoma occupying the left hemithorax. *World J Surg Oncol* 2005;3:76.
12. Zenker D, Aleksic I. Intrapulmonary cystic benign teratoma: a case report and review of the literature. *Ann Thorac Cardiovasc Surg* 2004;10(5):290–292.
13. Iwasaki T, Iuchi K, Matsumura A, Sueki H, Yamamoto S, Mori T. Intrapulmonary mature teratoma. *Jpn J Thorac Cardiovasc Surg* 2000; 48(7):468–472.
14. Tangthantham A, Wongsangiem M, Koanantakool T, Ponglertnapagorn P, Subhannachart P, Charupatanapongse U. Intrapulmonary teratoma: a report of three cases. *J Med Assoc Thai* 1998; 81(12):1028–1033.
15. Okamura M, Nishikawa M, Kenmotsu H, Kakemizu N, Takagi S, Suzuki Y, et al. [A case of intrapulmonary teratoma presenting with expectoration of white hair and cheese-like material]. *Nihon Kokyuki Gakkai Zasshi* 2003;41(3):191–195 (*article in Japanese*).
16. Ichikawa S, Ishimoto N, Sawaki K, Asai Y, Hirate Y, Miyata Y. [A case of teratoma in both the mediastinum and the intrapulmonary system]. *Kyobu Geka* 2000;53(2):163–166 (*article in Japanese*).
17. Tandon S, Kant S, Singh AK, Sinha KN, Chandra T, Agarwal PK. Primary intrapulmonary teratoma presenting as pyothorax. *Indian J Chest Dis Allied Sci* 1999;41(1):51–55.
18. Rana SS, Swami N, Mehta S, Singh J, Biswal S. Intrapulmonary teratoma: an exceptional disease. *Ann Thorac Surg* 2007;83(3):1194–1196.
19. Collier FC, Dowling EA, Plot D, Schneider H. Teratoma of the lung. *AMA Arch Pathol* 1959;68(2):138–142.
20. Drevelegas A, Palladas P, Scordalaki A. Mediastinal germ cell tumors: a radiologic-pathologic review. *Eur Radiol* 2001;11(10):1925–1932.
21. Cheung Y-C, Ng S-H, Wan Y-L, Pan K-T. Ruptured mediastinal cystic teratoma with intrapulmonary bronchial invasion: CT demonstration. *Br J Radiol* 2001;74(888):1148–1149.