

# The Role of Transbronchial Needle Aspiration in the Diagnosis of Bronchogenic Carcinoma

Thida Win MB BS, Susan Stewart MB BChir, Ashley M Groves MB BS,  
Jonna Pepke-Zaba PhD, and Clare M Laroche MB BS

**BACKGROUND:** For many years in the United States transbronchial needle aspiration (TBNA) has been used with flexible bronchoscopy to diagnosis bronchogenic carcinoma, but very few data are available from the United Kingdom. **METHODS:** All bronchoscopies performed for suspected bronchial carcinoma at Papworth Hospital, Cambridge, United Kingdom, over the last 3 years were reviewed retrospectively. Patients with peribronchial disease, as evidenced by submucosal infiltration or extrinsic compression on bronchoscopy, were selected for TBNA. Patients with computed tomography evidence of subcarinal lymphadenopathy were also included. In total we identified 78 patients: 67 with peribronchial disease and 21 with subcarinal lymphadenopathy. All 78 patients underwent TBNA, and in 8 of these TBNA was performed in 2 sites. **RESULTS:** Malignancy was confirmed in 66 of the 78 patients. TBNA was positive in 31/66 (47%) of the patients who had proven bronchogenic carcinoma. Additional staging information was obtained in 9/21 patients (42.8%) who underwent subcarinal lymph node aspiration. We also found that TBNA was diagnostic in 1 patient with tuberculosis and 1 with sarcoidosis. There was only 1 important TBNA complication, which was a small pneumothorax. **CONCLUSION:** In our preliminary experience with selected patients suspected to have bronchogenic carcinoma (based on peribronchial disease or subcarinal lymphadenopathy), we found TBNA a safe and useful tool. *Key words: transbronchial needle aspiration, TBNA, bronchoscopy, bronchogenic carcinoma, diagnosis.* [Respir Care 2003;48(6):602–605. © 2003 Daedalus Enterprises]

## Introduction

Flexible bronchoscopy is the most common modality used to diagnose bronchogenic carcinoma. Conventionally, bronchoscopy has been combined with forceps biopsy in the diagnosis of suspicious lesions. However, in the early 1980s flexible bronchoscopy used in combination with a dedicated transbronchial aspiration needle was investigated.<sup>1–6</sup> Since then multiple roles for transbronchial needle aspiration (TBNA) via flexible bronchoscopy have been demonstrated with respect to the diagnosis of bronchogenic carcinoma.

Dasgupta et al used flexible bronchoscopy and TBNA to diagnose carcinoma of the bronchus in endobronchial lesions, which may manifest as exophytic masses.<sup>7</sup> They concluded that the diagnostic yield appeared to be further enhanced when this technique was combined with other conventional methods. These findings were also confirmed by Govert et al.<sup>8</sup>

Horsley et al<sup>9</sup> suggested that TBNA was very useful in submucosal lesions, especially those covered with intact mucosa, which is not readily accessible to other sampling techniques. Shure and Fedullo used TBNA to sample peribronchial disease in which there was demonstrable submucosal infiltration or extrinsic compression.<sup>10</sup> They showed that the yield from the aspiration needle was higher than from conventional forceps biopsy for peribronchial lesions. Shure and Fedullo<sup>11</sup> also investigated TBNA for mediastinal and subcarinal lymphadenopathy, getting simultaneous diagnostic and staging information, with a lower complication rate than mediastinoscopy. The usefulness of TBNA in staging has also been confirmed in

---

Drs Thida Win, Susan Stewart, Jonna Pepke-Zaba, and Clare M Laroche are affiliated with the Thoracic Oncology Unit, Papworth Hospital, Papworth Everard, Cambridge, United Kingdom. Dr Ashley M Groves is affiliated with the Department of Radiology, Addenbrooke's Hospital, Cambridge, United Kingdom.

Correspondence: Thida Win MB BS, Thoracic Oncology Unit, Papworth Hospital, Papworth Everard, Cambridge, CB3 8RE, United Kingdom. E-mail: thida.win@papworth-tr.anglox.nhs.uk.

other studies.<sup>12,13</sup> There is also evidence to suggest TBNA can outperform transbronchial biopsy within peripheral lung lesions.<sup>14,15</sup>

Although other transatlantic studies<sup>16–18</sup> have confirmed the usefulness of TBNA, there are few data from the United Kingdom. We report our experience with TBNA in the diagnosis of bronchogenic carcinoma. In particular we examined peribronchial disease and subcarinal lymphadenopathy due to nodal involvement.

**Methods**

We reviewed all bronchoscopies performed for suspected carcinoma in the last 3 years at Papworth Hospital. In that period 548 flexible bronchoscopies were performed on lesions suspicious for bronchogenic carcinoma. All these patients underwent computed tomography scanning prior to bronchoscopy. Patients found to have peribronchial disease on bronchoscopy or subcarinal lymphadenopathy on computed tomography were entered into the study. During the study period 78 such patients had TBNA as part of their workup.

We performed TBNA in only 2 specific groups: patients with signs of peribronchial disease, and patients with subcarinal lymphadenopathy. We originally decided to perform TBNA on patients with peribronchial disease, as our own experience using conventional techniques suggested that diagnostic yield was low with this disease pattern. Additionally we employed TBNA for subcarinal nodes, as TBNA is relatively easy to perform, whereas subcarinal nodes are difficult to sample by other techniques. By sampling subcarinal nodes we gained useful staging information, which helped to determine the surgical resectability of the disease. Endobronchial lesions were not aspirated, as we already have a high forceps biopsy success rate. We did not employ TBNA on paratracheal nodes, as this is technically difficult.<sup>13</sup> Hilar nodes were also not aspirated, because disease of the hilar nodes does not alter patient management.

Bronchoscopy was usually performed without premedication. However, patients with known obstructive airways disease received nebulized bronchodilators 30 min prior to the procedure. During the procedure, sedation with midazolam titration was frequently used, along with lidocaine spray.

Bronchoscopy was performed with a standard flexible bronchoscope (Types 1 T 40, T20 D, P30, T240, and T10, Olympus, Melville, New York). During the procedure the TBNA was performed with a MW-319 histology needle (Mill-Rose Laboratories, Mentor, Ohio) that consists of an outer sheath (140 cm long and 1.9 mm in diameter) that contains a 15-mm, 19-gauge retractable needle, within which is a 21-gauge needle.

During bronchoscopy the catheter was passed through the biopsy channel with the needle retracted. Under direct vision the needle was advanced into the tissue perpendic-

ularly for lymph node biopsy, or at 45 degrees for submucosal lesions. Once the needle was appropriately placed within the lesion, it was minimally advanced, so that the entire length of the needle was in the tissue. Then the inner 21-gauge needle was retracted and locked in position. The needle was moved to and fro, under applied suction from a 20-mL syringe that had been pre-filled with 3 mL of saline. The pressure was released before the needle was taken out from the tissue, to avoid false-positive aspirates. This process was repeated up to 3 times to obtain multiple samples at each site of interest. If a good core was obtained, it was sent for histology. The remaining saline and any tissue fragments were sent immediately for cytology.

Other sampling techniques were also performed during bronchoscopy, including endobronchial biopsy and bronchial brushings and washings. All the study patients underwent TBNA, but it was at the bronchoscopist's discretion which additional sampling methods were performed. TBNA was always performed prior to other sampling methods to avoid the false positives. The diagnostic yield from each sampling technique was then compared. The success of each sampling technique was judged according to whether a firm diagnosis could be made on the specimen. Equivocal pathology was treated as a negative result. If the specimen was reported as highly suspicious, the case was reviewed at our multidisciplinary meeting. If radiological, clinical, and bronchoscopic findings supported the diagnosis, the specimen was regarded as positive, with the combined cytopathologist's and histopathologist's agreement.

In patients with false negative bronchoscopic findings the diagnosis of bronchogenic carcinoma was made from biopsies obtained via video-assisted thoracoscopy, computed-tomography-guided needle biopsy, or mediastinoscopy.

We documented the difference in detection rates for different cell types and for each operator. All complications were recorded.

**Results**

There were a total of 78 patients in our study group (Table 1), of which 66 had histologically confirmed bron-

Table 1. Results of Bronchoscopy in Study Patients

Result	n
Histologically confirmed bronchogenic carcinoma	66
False negative (radiologically suspicious carcinoma)	8
True negative for malignancy	2
Sarcoidosis	1
Tuberculosis	1
Total	78

# TRANSBRONCHIAL NEEDLE ASPIRATION IN THE DIAGNOSIS OF BRONCHOGENIC CARCINOMA

Table 2. Results of Transbronchial Needle Aspiration in Study Patients

Transbronchial needle aspiration	Total	Positive	Negative
Submucosal/peribronchial lesion	65 (100%)	27 (41.5%)	38 (58.5%)
Subcarinal lymph node lesion	21 (100%)	9 (42.8%)	12 (57.2%)
Total	86 (100%)	36 (41.9%)	50 (58.1%)

chogenic carcinoma. That number included 5 patients with histology highly suspicious for bronchogenic carcinoma. The histology was confirmed via bronchoscopy in 57 cases, computed-tomography-guided needle biopsy in 4 cases, video-assisted thoracoscopy biopsy in 3 cases, and mediastinoscopy in 2 cases. Among the remaining 12 patients, 8 had clinical and radiologic evidence of malignancy, 1 had sarcoidosis, and 1 had tuberculosis. The remaining 2 patients were presumed to be true negatives for malignancy, since no evidence of malignancy has been detected, despite prolonged follow-up and extensive investigation.

TBNA successfully detected 31 of the 66 (47%) histologically proven bronchial carcinomas. In 4 of these patients the diagnosis was made solely via aspiration (5.4%). Furthermore, additional staging information was gained in 9 of 21 patients (42.8%) who had mediastinal lymph node biopsy via TBNA (Table 2). Of these 21 patients only 3 had confirmatory mediastinoscopy. Two of the positive TBNA samples were confirmed via mediastinoscopy, but one of the negative TBNA was positive on mediastinoscopy. Among the 47 TBNA-negative patients 31 had inadequate samples.

In 8 of the 78 patients we performed TBNA at 2 different sites, making a total of 86 TBNA performed. Figure 1 shows the efficacy of TBNA in relation to the site of the lesion. Of those 86 TBNA samples, 36 (41.9%) were positive. In comparison, 43 of 70 (61.4%) endobronchial biopsies, 12 of 44 (27%) bronchial brushings, and 33 of 73 (45%) bronchial washings were positive (Table 3). The

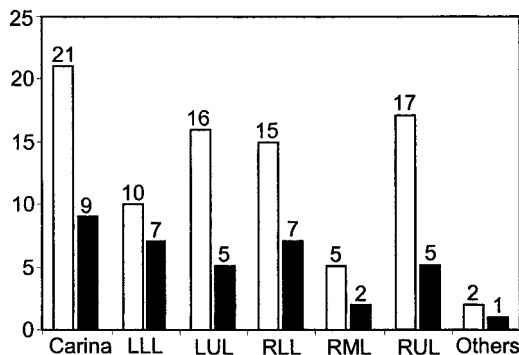


Fig. 1. Efficacy of transbronchial needle aspiration in relation to the site of the lesion. Clear bars represent totals. Black bars represent positive efficacy. LLL = left lower lobe. LUL = left upper lobe. RLL = right lower lobe. RML = right middle lobe.

Table 3. Efficacy of Transbronchial Needle Aspiration Related to Conventional Diagnostic Procedure

	TBNA	Endobronchial Biopsy	Bronchial Washing	Bronchial Brushing
Total Positive (%)	41.9	61.4	45	27
Positive (n)	36	43	33	12
Negative (n)	50	27	40	32
Total (n)	86	70	73	44

TBNA = transbronchial needle aspiration.

Table 4. Sole Positive Rates for 4 Bronchoscopic Sampling Techniques

Technique	Sole Positive Rate (%)
TBNA	5.4
Endobronchial biopsy	12.1
Bronchial washing	4.0
Bronchial brushing	0

TBNA = transbronchial needle aspiration.

pickup rates were statistically significant across the 4 sampling techniques ( $p = 0.004$  by Pearson's chi-square test). Of note, bronchial brushings did not provide the sole positive specimen in any patient (Table 4).

The individual operator TBNA success rates were 34.7%, 60%, and 17.7% for operators A, B, and C, respectively. Figure 2 shows the different carcinoma cell types diagnosed using TBNA. Only 1 important complication was reported: a small pneumothorax.

## Discussion

Despite increasing recognition of the usefulness of TBNA for diagnosing and staging bronchogenic carcinoma, only small numbers of United Kingdom bronchoscopists are employing the technique. This may be due to lack of practice

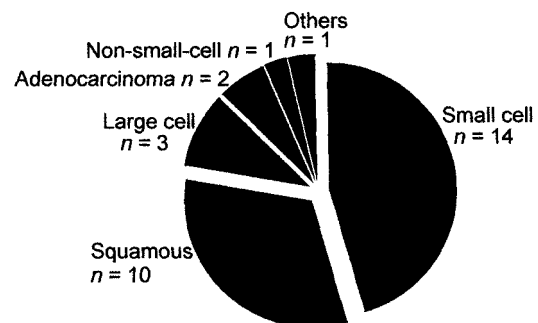


Fig. 2. Histology of positive transbronchial needle aspiration samples.

and knowledge regarding TBNA, or simply because conventional techniques are believed to be adequate.

At our institution TBNA was first introduced in 1999. Since then we have used TBNA routinely in the diagnosis of lung cancer, when indicated. Although the results presented in this report are from our preliminary experience with 78 patients, the overall diagnostic yield increased from 83% to 89% by adding TBNA to conventional techniques.

For peribronchial disease, when we compared our TBNA yield to that of conventional endobronchial forceps biopsy, we found the conventional technique superior. This is contradictory to the results published previously by Dasgupta et al<sup>7</sup> and Shure and Fedullo.<sup>10</sup> We also found that bronchial washings were more useful than other studies had shown.<sup>7</sup> However, we concluded that bronchial brushings are unhelpful, because they failed to yield any additional information. Our results suggest that TBNA is best for detecting small cell carcinoma, compared to other cell types, which is consistent with other reports.<sup>7,18</sup> This may reflect that in our study small cell tumors tended to be more diffuse and present with peribronchial disease or metastasis to mediastinal lymph nodes.

Regarding staging we found TBNA more useful than some of the previous investigations,<sup>11,19,20</sup> whereas our complication rate was similar to others' experience.<sup>21</sup> Our data showed that optimal performance of TBNA requires substantial practice—a finding that has been noted before<sup>22,23</sup> and that may have contributed to the unpopularity of the technique. The highest diagnostic yield was obtained by the operator with a special interest in the technique and was not related to years of training.

### Conclusions

Our preliminary experience indicates that TBNA is a useful technique, especially as an adjunct to other sampling methods and when performed by operators who have the required education and practice. The procedure is quick and safe and should not substantially increase the cost of diagnosis. We would recommend TBNA in the workup of bronchial carcinoma when there is evidence of peribronchial disease or mediastinal lymphadenopathy. We find TBNA to be a safe and useful tool in the diagnosis and staging of bronchogenic carcinoma.

### REFERENCES

1. Wang KP, Terry PB. Transbronchial needle aspiration in the diagnosis and staging of bronchogenic carcinoma. *Am Rev Respir Dis* 1983;127(3):344–347.
2. Wang KP, Brower R, Haponik EF, Siegelman S. Flexible transbronchial needle aspiration for staging of bronchogenic carcinoma. *Chest* 1983;84(5):571–576.
3. Buirski G, Calverley PM, Douglas NJ, Lamb D, McIntyre M, Sudlow MF, White H. Bronchial needle aspiration in the diagnosis of bronchial carcinoma. *Thorax* 1981;36(7):508–511.
4. Lundgren R. A flexible thin needle for transbronchial aspiration biopsy through the flexible fiberoptic bronchoscope. *Endoscopy* 1980;12(4):180–182.
5. Lundgren R, Bergman F, Angstrom T. Comparison of transbronchial fine needle aspiration biopsy, aspiration of bronchial secretion, bronchial washing, brush biopsy and forceps biopsy in the diagnosis of lung cancer. *Eur J Respir Dis* 1983;64(5):378–385.
6. Wang KP, Haponik EF, Gupta PK, Erozan YS. Flexible transbronchial needle aspiration: technical considerations. *Ann Otol Rhinol Laryngol* 1984;93(3 Pt 1):233–236.
7. Dasgupta A, Jain P, Minai OA, Sandur S, Meli Y, Arroliga AC, Mehta AC. Utility of transbronchial needle aspiration in the diagnosis of endobronchial lesions. *Chest* 1999;115(5):1237–1241.
8. Govert JA, Dodd LG, Kussin PS, Samuelson WM. A prospective comparison of fiberoptic transbronchial needle aspiration and bronchial biopsy for bronchoscopically visible lung carcinoma. *Cancer* 1999;87(3):129–134.
9. Horsley JR, Miller RE, Amy RW, King EG. Bronchial submucosal needle aspiration performed through the fiberoptic bronchoscope. *Acta Cytol* 1984;28(3):211–217.
10. Shure D, Fedullo PF. Transbronchial needle aspiration in the diagnosis of submucosal and peribronchial bronchogenic carcinoma. *Chest* 1985;88(1):49–51.
11. Shure D, Fedullo PF. The role of transcarinal needle aspiration in the staging of bronchogenic carcinoma. *Chest* 1984;86(5):693–696.
12. Schenk DA, Bower JH, Bryan CL, Currie RB, Spence TH, Duncan CA, et al. Transbronchial needle aspiration staging of bronchogenic carcinoma. *Am Rev Respir Dis* 1986;134(1):146–148.
13. Patelli M, Agli LL, Poletti V, Trisolini R, Cancellieri A, Lacava N, et al. Role of fiberoptic transbronchial needle aspiration in the staging of N2 disease due to non-small cell lung cancer. *Ann Thorac Surg* 2002;73(2):407–411.
14. Reichenberger F, Weber J, Tamm M, Bolliger CT, Dalquen P, Perruchoud AP, Soler M. The value of transbronchial needle aspiration in the diagnosis of peripheral pulmonary lesions. *Chest* 1999;116(3):704–708.
15. Shure D, Fedullo PF. Transbronchial needle aspiration of peripheral masses. *Am Rev Respir Dis* 1983;128(6):1090–1092.
16. Harrow EM, Oldenburg FA, Smith AM. Transbronchial needle aspiration in clinical practice. *Thorax* 1985;40(10):756–759.
17. Harrow EM, Wang KP. The staging of lung cancer by bronchoscopic transbronchial needle aspiration. *Chest Surg Clin N Am* 1996;6(2):223–235.
18. Harrow EM, Abi-Saleh W, Blum J, Harkin T, Gasparini S, Addrizzo-Harris DJ, et al. The utility of transbronchial needle aspiration in the staging of bronchogenic carcinoma. *Am J Respir Crit Care Med* 2000;161(2 Pt 1):601–607.
19. Blainey AD, Curling M, Green M. Transbronchial aspiration of subcarinal lymph nodes. *Br J Dis Chest* 1988;82(2):149–154.
20. Salathe M, Soler M, Bolliger CT, Dalquen P, Perruchoud AP. Transbronchial needle aspiration in routine fiberoptic bronchoscopy. *Respiration* 1992;59(1):5–8.
21. Wang KP, Haponik EF, Britt EJ, Khouri N, Erozan Y. Transbronchial needle aspiration of peripheral pulmonary nodules. *Chest* 1984;86(6):819–823.
22. Haponik EF, Cappellari JO, Chin R, Adair NE, Lykens M, Alford PT, Bowton DL. Education and experience improve transbronchial needle aspiration performance. *Am J Respir Crit Care Med* 1995;151(6):1998–2002.
23. Haponik EF, Shure D. Underutilization of transbronchial needle aspiration: experiences of current pulmonary fellows. *Chest* 1997;112(1):251–253.