

Changing Ventilator Graphics in a Patient with Massive Cerebral Hemorrhage

Jeffrey M Haynes RRT RPFT

Case Summary

A 56-year-old woman with poorly controlled hypertension presented to the emergency department with aphasia, right-sided weakness, and an arterial blood pressure of 250/130 mm Hg. A computed tomography scan revealed a large left-sided cerebral hemorrhage. The patient's neurologic condition worsened and she was intubated and mechanically ventilated (7200 ventilator, Puritan-Bennett, Pleasanton, California). On hospital day 3 her ventilator settings were: continuous mandatory ventilation mode, frequency 12 breaths/min, tidal volume 600 mL, fraction of inspired oxygen ($F_{I_{O_2}}$) 0.35, peak inspiratory flow 70 L/min with a decelerating flow pattern. During a routine ventilator check the peak inspiratory pressure was 15 cm H_2O and the total respiratory frequency was 18 breaths/min. The pressure/time and flow/time curves from the ventilator's graphic monitor were unremarkable (not recorded). A few minutes later the low inspiratory pressure limit (set at 10 cm H_2O) alarmed; a quick inspection revealed no circuit leaks or disconnection. Figure 1 shows the ventilator's pressure/time and flow/time curves during that situation. The curves in Figure 2 were recorded 5 minutes after those in Figure 1.

Questions

1. What ventilation abnormalities are illustrated by the pressure/time and flow/time curves in Figure 1?
2. What is the cause of these ventilation abnormalities?

Jeffrey M Haynes RRT RPFT is affiliated with the Department of Respiratory Therapy, St Joseph Hospital, Nashua, New Hampshire.

Correspondence: Jeffrey M Haynes RRT RPFT, Department of Respiratory Therapy, St Joseph Hospital, 172 Kinsley Street, Nashua NH 03060. E-mail: jhaynes@sjh-nh.org.

Answers

1. The Figure 1 curves are shown again in Figure 3 with labels to help identify key points. The curves in Figure 1 show slightly positive pressure late in the expiratory phase (identified by downward arrows in Fig. 3) and a very low expiratory flow early in the expiratory phase (identified by upward arrows in Fig. 3), which is quite unusual, since this is when elastic recoil should be greatest. Expiratory flow increases later in the expiratory phase, coinciding with positive airway pressure. These expiratory pressure and flow patterns are caused by breath-holding. As shown in Figure 4, this pattern can be produced by temporarily clamping closed a test lung at end-inspiration. Based on physical examination the patient's peak inspiratory pressure appeared to decrease because of increased inspiratory efforts during fixed-volume controlled breaths (volume starvation). Figure 2 shows a return of the previously observed pressure/time and flow/time curves. Ventilation during the recording of Figure 2 was passive, and the patient never regained any spontaneous ventilatory activity.
2. The curves in Figure 1 represent an apneustic breathing pattern caused by brainstem injury related to the patient's cerebral hemorrhage.

Discussion

Apneustic breathing is a rarely observed ventilatory pattern characterized by end-inspiratory breath holds, which are sometimes followed by forced exhalations (see Fig. 5). Marckwald is credited with the first description of apneustic breathing, which he observed in rabbits that underwent vagotomy and brainstem transection.^{1,2} Though a derangement in the brainstem's ability to terminate the inspiratory cycle would seem obvious, the exact mechanisms that create apneustic breathing are not clear. The classic theory that apneustic breathing was exclusively due to failure of the pneumotaxic center in the upper pons to

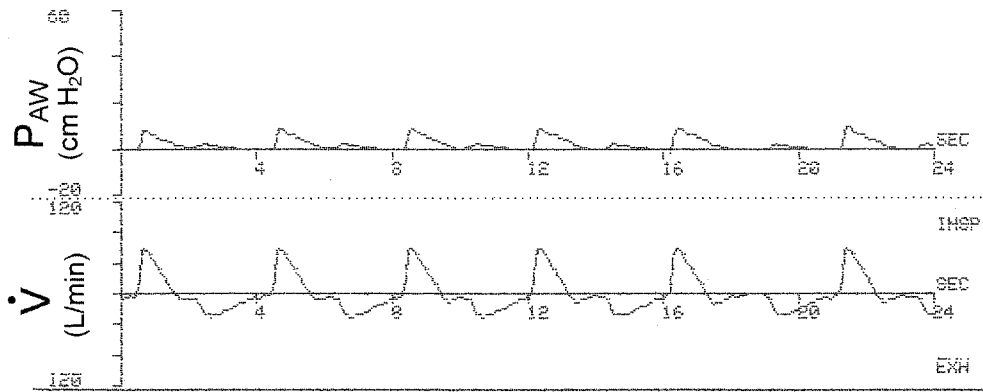


Fig. 1. Pressure/time and flow/time curves from the ventilator's graphic monitor, recorded after a decrease in peak inspiratory pressure was detected. P_{aw} = peak airway pressure. \dot{V} = flow.

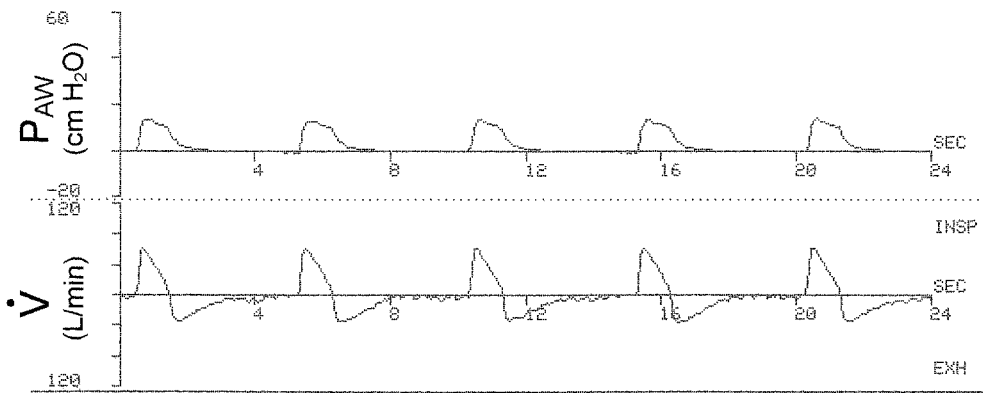


Fig. 2. Pressure/time and flow/time ventilator curves recorded 5 minutes after Figure 1 was recorded. Ventilation during the recording of Figure 2 was completely passive, and the patient never regained any spontaneous ventilatory activity. Note the faint cardiogenic oscillations on the expiratory flow/time tracings. P_{aw} = peak airway pressure. \dot{V} = flow.

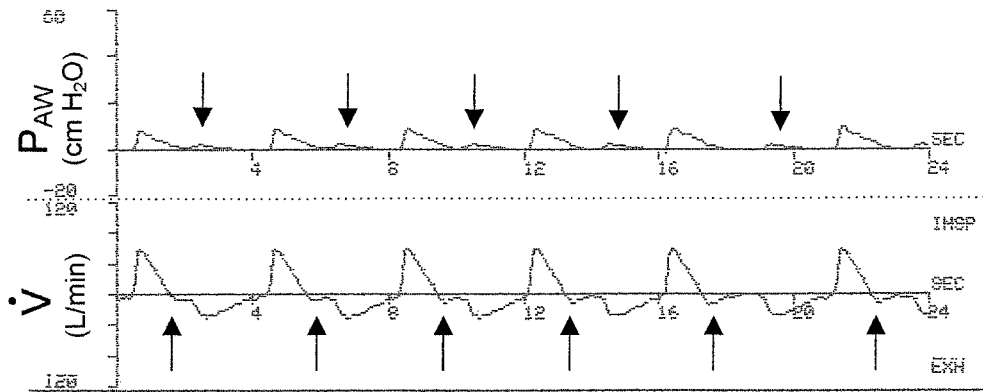


Fig. 3. Pressure/time and flow/time curves reproduced from Figure 1 with labels added to help identify key points. The pressure/time curve shows slightly positive pressure late in the expiratory phase, indicated by downward arrows. The flow/time curve shows very low expiratory flows early in the expiratory phase, indicated by upward arrows. P_{aw} = peak airway pressure. \dot{V} = flow.

inhibit the inspiratory-producing apneustic center in the lower pons has been effectively refuted.² In fact, apneustic breathing has been reported in patients with various conditions, including foramen magnum stenosis,² brainstem

injury,^{3,4} multiple sclerosis,⁵ Rett syndrome,⁶ and of unknown etiology.⁷ In this patient with massive cerebral hemorrhage it is reasonable to suspect that a pontine infarction was the cause of apneusis. Stewart et al⁴ reported a case of

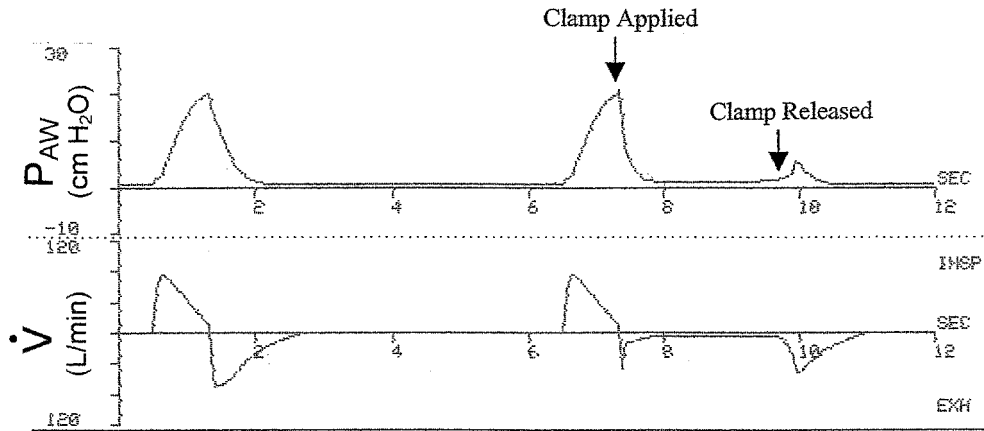


Fig. 4. Simulated breath-holding by temporarily clamping closed a test lung at end-inspiration. The first ventilation cycle had no clamp applied. The second ventilation cycle had a clamp applied at end-inspiration; once the clamp is released, expiratory flow produces positive airway pressure. P_{aw} = peak airway pressure. \dot{V} = flow.

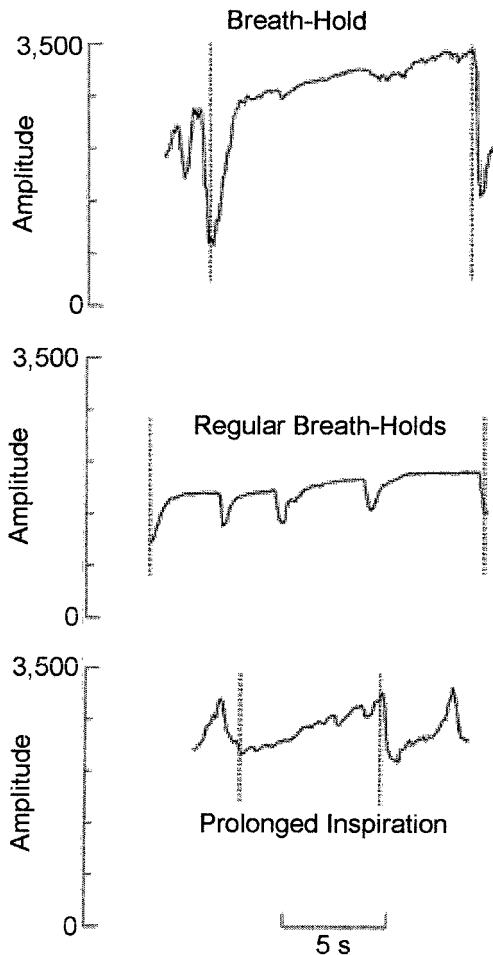


Fig. 5. Examples of apneustic breathing patterns. Time is represented on the horizontal axis and amplitude (in arbitrary units) is represented on the vertical axis. Top: Prolonged breath-hold followed by a rapid exhalation. Middle: Regular breath-holds. Bottom: Prolonged inspiration followed by rapid exhalation. (Adapted from Reference 6, with permission.)

apneustic breathing in a patient who had suffered a stroke; an autopsy of the patient did reveal a pontine infarction. After this episode of apneustic breathing, our patient never regained any spontaneous respiratory activity, which would suggest loss of brainstem function.

REFERENCES

1. Marckwald M. The movements of respiration and their innervation in the rabbit. Haig TA, trans. London: Blackie and Son, 1888.
2. Mador MJ, Tobin MJ. Apneustic breathing: a characteristic feature of brainstem compression in achondroplasia? *Chest* 1990;97(4):877-883.
3. Saito Y, Hashimoto T, Iwata H, Takahashi K, Fukumizu M, Sasaki M, et al. Apneustic breathing in children with brainstem damage due to hypoxic-ischemic encephalopathy. *Dev Med Child Neurol* 1999; 41(8):560-567.
4. Stewart J, Howard RS, Rudd AG, Woolf C, Russell RW. Apneustic breathing provoked by limbic influences. *Postgrad Med J* 1996; 72(851):559-561.
5. Howard RS, Wiles CM, Hirsch NP, Loh L, Spencer GT, Newsom-Davis J. Respiratory involvement in multiple sclerosis. *Brain* 1992; 115(Pt 2):479-494.
6. Julu POO, Kerr AM, Apartopoulos F, Al-Rawas S, Witt Engerström I, Engerström L, et al. Characterisation of breathing and associated central autonomic dysfunction in the Rett disorder. *Arch Dis Child* 2001;85(1):29-37.
7. Saito Y, Ito M, Ozawa Y, Obonai T, Kobayashi Y, Washizawa K, et al. Changes of neurotransmitters in the brainstem of patients with respiratory-pattern disorders during childhood. *Neuropediatrics* 1999; 30(3):133-140.