

# Acute Inhalation Injury With Evidence of Diffuse Bronchiolitis Following Chlorine Gas Exposure at a Swimming Pool

Tanyalak Parimon MD, Jeffrey P Kanne MD, and David J Pierson MD FAARC

**A previously healthy 23-year-old man with nonproductive cough and sore throat presented to the hospital a few hours after chlorine gas exposure at a fitness center swimming pool. Initial physical examination and chest radiograph were normal. Thirty-six hours later he developed worsening dyspnea and cough, with development of blood-tinged sputum. Arterial blood gas analysis showed mild hypoxemia and a subsequent chest radiograph demonstrated diffuse tiny nodular opacities. Findings on a thin-section computed tomogram of the chest were consistent with diffuse bronchiolitis. Pulmonary function tests showed a mild obstructive abnormality and he demonstrated substantial bronchodilator response. The patient was treated with oral corticosteroids and an inhaled  $\beta_2$  agonist, to which he responded well, with full clinical recovery occurring over 5 months. This manifestation of chlorine gas exposure at a swimming pool is unusual.** *Key words: bronchiolitis, chlorine.* [Respir Care 2004;49(3):291–294. © 2004 Daedalus Enterprises]

## Introduction

Chlorine is one of the most common substances involved in toxic inhalation. The first toxic effects were described in Belgium in 1915, as a result of chemical warfare. In the 1920s chlorine was introduced as a bleaching agent and became more widely used in other industrial processes, household products such as bleach powder, and in water purification. Since then several accidental exposures have been reported.<sup>1–3</sup> Most cases, and those with the most serious outcomes, occur in the industrial setting. However, because of an increasing number of municipal and private swimming pools, cases of non-industrial accidental exposure have occurred, some with substantial morbidity.

Decker and Koch reported the first case of acute chlorine gas exposure in a swimming pool in 1978.<sup>4</sup> That patient had no sequelae. Decker reported another 2 episodes in 1986 and 1988.<sup>5</sup> Subsequently, inhalation injury

occurring at swimming pools has been reported several times. In one series 38% of exposed individuals required hospitalization.<sup>6</sup> The severity of illness ranges from acute respiratory failure (in the setting of acute respiratory distress syndrome) to mild mucosal irritation such as lacrimation and nasopharyngeal edema, depending on the concentration and duration of exposure.<sup>7</sup> Late sequelae such as occupational asthma have also been described from nitrogen trichloride, a product of chlorinated water in air surrounding swimming pools.<sup>8</sup> To our knowledge this is the first reported case of diffuse bronchiolitis as a result of chlorine gas exposure at a swimming pool.

## Case Summary

A nonsmoking, previously healthy 23-year-old man, a college student, presented to the emergency department together with 7 other people several hours after an accidental chlorine gas exposure at a community swimming pool. The patient was exposed to chlorine gas for about 5 minutes while exercising in the fitness center adjacent to the swimming pool. The fitness center's manager reported that the chlorine monitor on the center's swimming pool failed to recognize that the water level was lower than usual. As a result, air was sucked into the water purification pipe that contained a 10–16% liquid sodium hypochlorite (NaOCl), leading to chlorine gas formation. Chlorine gas of unknown concentration then spread throughout the building.

---

Tanyalak Parimon MD and David J Pierson MD FAARC are affiliated with the Division of Pulmonary and Critical Care Medicine, and Jeffrey P Kanne MD is affiliated with the Department of Radiology, Harborview Medical Center, University of Washington, Seattle, Washington.

Correspondence: David J Pierson MD FAARC, Division of Pulmonary and Critical Care Medicine, Harborview Medical Center, Box 359762, 325 Ninth Avenue, Seattle WA 98104. E-mail: djp@u.washington.edu.

On presentation the patient reported throat irritation and a dry cough. He denied any history of recent travel or any symptoms of illness prior to this presentation. Physical examination and the initial chest radiograph were normal. Arterial blood gases on room air were pH 7.34,  $P_{aCO_2}$  47 mm Hg, and  $P_{aO_2}$  74 mm Hg. He was discharged home without treatment. Overnight his cough and sore throat worsened and he developed chest discomfort on deep inspiration. The next morning he returned to the emergency department with complaints of fatigue and dyspnea. On examination, he was afebrile, tachypneic (respiratory rate 28 breaths/min), and had bilateral end-expiratory wheezes. A chest radiograph obtained at that time (36 h after exposure) showed diffuse small nodular opacities (Fig. 1). Arterial blood gas values while the patient breathed ambient air were pH 7.40,  $P_{aCO_2}$  43 mm Hg, and  $P_{aO_2}$  63 mm Hg. A complete blood count showed hemoglobin 14.9 g/dL, hematocrit 43%, leukocyte count  $10.3 \times 10^9/L$  (polymorphonuclear leukocytes 80%, lymphocytes 11%, monocytes 7%, and eosinophils 2%). The patient was admitted to the hospital for further evaluation and treatment.

Over the next few hours the patient's cough became productive of scant blood-tinged sputum. He was treated with supplemental oxygen and inhaled albuterol. A thin-section computed tomogram of the chest demonstrated ill-defined centrilobular nodules along the peribronchovascular structure, particularly in the dependent portions of the lungs, as well as mild air trapping, without bronchial wall thickening or bronchiectasis—findings consistent with diffuse bronchiolitis (Fig. 2). Pulmonary function tests performed 96 hours after the chlorine gas exposure revealed a mild obstructive defect, with substantial bronchodilator response, air trapping, and a moderately decreased diffusing capacity (Table 1). The

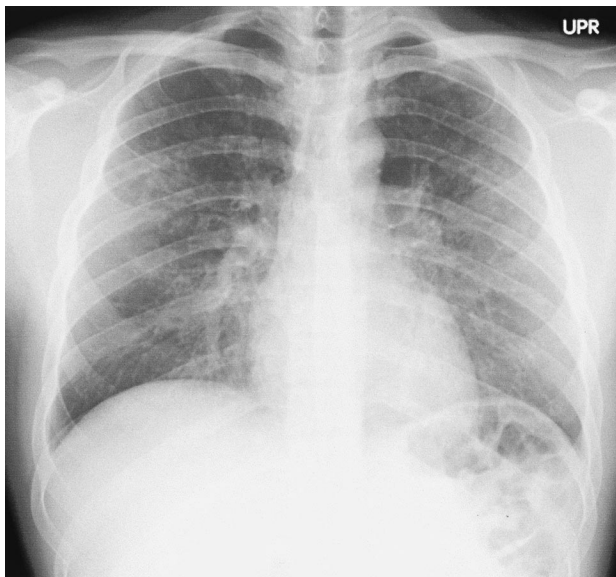


Fig. 1. Chest radiograph obtained 36 hours after chlorine inhalation shows diffuse nodular opacities in both lungs.

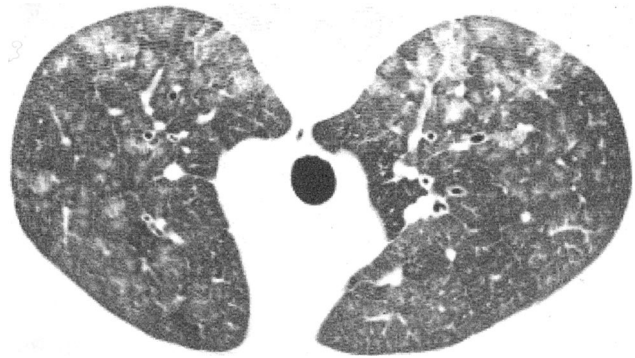


Fig. 2. Unenhanced thin-section computed tomogram (W 1,200, L 700, 1.25 mm) shows diffuse ill-defined centrilobular nodules and prominent peribronchovascular structures. Mild air trapping was apparent on expiratory images (not shown).

patient's symptoms gradually improved, with resolution of hemoptysis. On the third hospital day his oxyhemoglobin saturation (measured via pulse oximetry) was 95% while breathing room air.

He was discharged on albuterol (via metered-dose inhaler, every 6 h) and prednisone (1 mg/kg/d, for a 4-week course). Four weeks after the exposure the patient continued to have mild dyspnea on strenuous exertion but otherwise felt well. Repeat pulmonary function tests obtained 12 weeks after the exposure showed substantial improvement, with resolution of airflow obstruction. Although vital capacity and total lung capacity had been within normal limits on the first test, their increase to supranormal values on follow-up suggests the presence of an initial restrictive process as well as airflow obstruction and air trapping during the first evaluation. The diffusing capacity had improved but remained mildly reduced at 12 weeks. A methacholine challenge test performed at 12 weeks was normal. Five months after the accident the patient was asymptomatic and reported that his exercise capacity had returned to its pre-exposure level.

### Discussion

With appropriate clinical correlation this patient's computed tomogram findings are consistent with diffuse bronchiolitis. Causes of bronchiolitis include infection by organisms, such as virus or *Mycoplasma*, and noninfectious inflammation such as aspiration or inhalation of toxic fumes or vapor. Bronchiolitis may be found in underlying chronic bronchial diseases such as asthma or can be related to smoking. Lung biopsy would be required for certain confirmation of this diagnosis but was thought not to be clinically justifiable in this case, in view of the patient's prompt improvement with the treatment given. Given the clinical presentation and imaging findings, and the absence of known acute or chronic illness prior to the chlorine gas

## DIFFUSE BRONCHIOLITIS FROM CHLORINE GAS INHALATION AT A SWIMMING POOL

Table 1. Pulmonary Function Test Results 96 Hours and 12 Weeks Following Chlorine Gas Exposure

	Predicted Value	96 Hours After Exposure		12 Weeks After Exposure	
		Before Bronchodilator (% of Predicted)	After Bronchodilator (% of Predicted)	Before Bronchodilator (% of Predicted)	After Bronchodilator (% of Predicted)
FVC (L)	3.79	3.22 (85)	3.54 (93)	4.55 (120)	4.42 (117)
FEV <sub>1</sub> (L)	3.29	2.36 (72)	2.94 (89)	3.65 (111)	3.54 (108)
FEV <sub>1</sub> /FVC (%)	87	73	83	80	80
FEF <sub>25-75%</sub> (L/s)	3.33	1.68 (50)	3.98 (120)	3.37 (88)	3.04 (79)
SVC (L)	3.71	3.13 (84)	NT	4.63 (125)	NT
IC (L)	2.54	2.10 (83)	NT	3.13 (123)	NT
ERV (L)	1.17	1.03 (88)	NT	1.50 (128)	NT
FRC (N <sub>2</sub> ) (L)	2.10	2.34 (111)	NT	2.94 (140)	NT
RV (N <sub>2</sub> ) (L)	0.93	1.31 (141)	NT	1.44 (155)	NT
TLC (N <sub>2</sub> ) (L)	4.64	4.44 (96)	NT	6.07 (131)	NT
RV/TLC (N <sub>2</sub> ) (%)	21	29	NT	24	NT
TGV (L)	2.10	2.91 (139)	NT	3.05 (145)	NT
RV (Pleth) (L)	0.93	1.88 (202)	NT	1.55 (167)	NT
TLC (Pleth) (L)	4.64	5.01 (108)	NT	6.18 (133)	NT
RV/TLC (Pleth) (%)	21	38	NT	25	NT
D <sub>1,CO</sub> uncorrected (mL/min/mm Hg)	29.91	15.40 (51)	NT	20.35 (68)	NT

FVC = forced vital capacity.

FEV<sub>1</sub> = forced expiratory volume in the first.

FEF<sub>25-75%</sub> = forced expiratory flow in the middle half of the forced vital capacity.

SVC = slow vital capacity.

NT = measurement not taken.

IC = inspiratory capacity.

ERV = expiratory reserve volume.

FRC = functional residual capacity.

N<sub>2</sub> = values from nitrogen washout technique.

RV = residual volume.

TLC = total lung capacity.

TGV = thoracic gas volume.

Pleth = values from body plethysmography.

D<sub>1,CO</sub> = single-breath diffusing capacity for carbon monoxide.

exposure, our diagnosis was acute inhalation injury with diffuse bronchiolitis resulting from chlorine gas exposure.

To our knowledge this is the first reported case of diffuse bronchiolitis resulting from chlorine gas exposure at a swimming pool. The most common manifestations of such exposure in previous series (Table 2)<sup>4-6,9-11</sup> have been those of mucosal and airway irritation, and almost all exposed individuals have survived without sequelae. In the series reported by Martinez et al<sup>9</sup> one patient died from acute respiratory distress syndrome and cardiovascular failure. Otherwise, symptoms usually resolved within several weeks.<sup>12</sup>

Chlorine is a heavy, greenish-yellow gas or boiling yellow liquid with a characteristic pungent, irritating odor. Chlorine-releasing agents (calcium or sodium hypochlorite and chlorinated isocyanuric acids) are frequently used for water purification in swimming pools. Swimming pool chlorine exposure may result from explosions, leaks, or malfunction of chlorine-disinfection installation systems. Other sources include related compounds such as chloramine in the atmosphere of an indoor swimming pool.<sup>7</sup>

Of all organ systems, the respiratory system is the most adversely affected by chlorine gas exposure. Effects are related to the concentration of chlorine in the air and to the duration of exposure. With considerable consistency around the world, chlorine has a time-weighted average exposure standard of 0.5–1 ppm. However, one recent study showed that at the level of 0.5 ppm chlorine exposure could result in nasal irritation in individuals with seasonal allergic rhinitis.<sup>13</sup> The fatal dose ranges from 50 to 2,000 ppm. One study with pigs demonstrated that after exposure of 100–140 ppm for 10 min, 5 of 6 animals died within 6 hours.<sup>14</sup>

The basic mechanism of toxicity is related to the solubility of chlorine in water, with chlorine forming hydrochloric and hypochlorous acids, which subsequently undergo ionization. This reaction occurs in moist environments such as the eyes, nasal mucosa, and respiratory epithelium.<sup>15</sup> The severity of clinical syndromes of acute exposure range from fatal asphyxia or severe acute respiratory distress syndrome to mild injury such as simple irritation of the conjunctivae or nasal mucosa. Reported respiratory injuries following acute chlo-

## DIFFUSE BRONCHIOLITIS FROM CHLORINE GAS INHALATION AT A SWIMMING POOL

Table 2. Reported Series of Chlorine Gas Exposures at Swimming Pools

Author	Year	Patients (n)	Manifestations
Decker and Koch <sup>4</sup>	1978	1	Chest tightness, throat irritation
Decker <sup>5</sup>	1988	41	Chest discomfort, nasal/throat irritation
Martinez et al <sup>9</sup>	1995	2	Acute respiratory distress syndrome*
Sexton and Pronchik <sup>6</sup>	1998	13	Mucosal irritation, dyspnea, and wheezing
Kilburn et al <sup>11</sup>	2000	4	Unspecified
Agabiti et al <sup>10</sup>	2001	282	Mucosal irritation, dyspnea, and wheezing

\*One patient died after several hours of exposure. ARDS, acute respiratory distress syndrome.

rine exposure include rhinitis, tracheobronchitis, pneumonitis, and pulmonary edema.<sup>16</sup> Most exposed individuals have complete resolution of their symptoms without late sequelae. However, late complications such as occupational asthma caused by chloramines,<sup>8</sup> increased airway responsiveness, the reactive airways dysfunction syndrome, and decreased residual volume<sup>11,17-19</sup> have been described.

The management of chlorine poisoning follows conventional approaches to poisoning.<sup>15</sup> First, render the situation safe and then remove the affected individual(s) from further risk (if necessary, using suitable personal and respiratory protection). The current standard treatment is symptomatic, including supplemental oxygen, bronchodilators, and rest. There have been no randomized, controlled trials or large series that establish specific treatment.

A few studies have used animal models, which involved treatment with systemic or inhaled corticosteroids administered immediately following high-level exposure, and those studies showed improved pulmonary and cardiovascular function but no effect on mortality.<sup>20-22</sup> Oral corticosteroids have been suggested to be effective in some human case series.<sup>23</sup> Another case series showed possible benefit from nebulized sodium bicarbonate.<sup>24</sup>

In conclusion, mortality and morbidity from swimming-pool chlorine gas exposure are minimal, and serious injuries have rarely been reported in healthy individuals. However, the wide use of chlorine in industrial settings, household products, and water purification provides opportunity for inhalation injury, as has been described in several reports. Our case demonstrates that such inhalation injury may include diffuse bronchiolitis, which may take many weeks to resolve.

### REFERENCES

1. Toren K, Blanc PD. The history of pulp and paper bleaching: respiratory-health effects. *Lancet* 1997;349(9061):1316-1318.

2. Beach FXM, Jones ES, Scarrow GD. Respiratory effects of chlorine gas. *Br J Ind Med* 1969;26(3):231-236.
3. Guloglu C, Kara IH, Erten PG. Acute accidental exposure to chlorine gas in the Southeast of Turkey: a study of 106 cases. *Environ Res* 2002;88(2):89-93.
4. Decker WJ, Koch HF. Chlorine poisoning at the swimming pool: an overlooked hazard. *Clin Toxicol* 1978;13(3):377-381.
5. Decker WJ. Chlorine poisoning at the swimming pool revisited: anatomy of two minidisasters. *Vet Hum Toxicol* 1988;30(6):584-585.
6. Sexton JD, Pronchik DJ. Chlorine inhalation: the big picture. *J Toxicol Clin Toxicol* 1998;36(1-2):87-93.
7. Nemery B, Hoet PHM, Nowak D. Indoor swimming pools, water chlorination and respiratory health (editorial). *Eur Respir J* 2002;19(5):790-793.
8. Thickett KM, McCoach JS, Gerber JM, Sadhra S, Burge PS. Occupational asthma caused by chloramines in indoor swimming-pool air. *Eur Respir J* 2002;19(5):827-832.
9. Martinez TT, Long C. Explosion risk from swimming pool chlorinators and review of chlorine toxicity. *J Toxicol Clin Toxicol* 1995;33(4):349-354.
10. Agabiti N, Ancona C, Forastiere F, Di Napoli A, Lo Presti E, Corbo GM, et al. Short term respiratory effects of acute exposure to chlorine due to a swimming pool accident. *Occup Environ Med* 2001;58(6):399-404.
11. Kilburn KH. Chlorine-induced damage documented by neurophysiological, neuropsychological, and pulmonary testing. *Arch Environ Health* 2000;55(1):31-37.
12. Leroyer C, Malo JL, Infante-Rivard C, Dufour JG, Gauthrin D. Changes in airway function and bronchial responsiveness after acute occupational exposure to chlorine leading to treatment in a first aid unit. *Occup Environ Med* 1998;55(5):356-359.
13. Shusterman DJ, Murphy MA, Balmes JR. Subjects with seasonal allergic rhinitis and nonrhinitic subjects react differentially to nasal provocation with chlorine gas. *J Allergy Clin Immunol* 1998;101(6 Pt 1):732-740.
14. Gunnarsson M, Walther SM, Seidal T, Bloom GD, Lennquist S. Exposure to chlorine gas: effects on pulmonary function and morphology in anaesthetized and mechanically ventilated pigs. *J Appl Toxicol* 1998;18(4):249-255.
15. Winder C. The toxicology of chlorine. *Environ Res* 2001;85(2):105-114.
16. Rabinowitz PM, Siegel MD. Acute inhalation injury. *Clin Chest Med* 2002;23(4):707-715.
17. Gauthrin D, Leroyer C, Infante-Rivard C, Ghezzi H, Dufour JG, Girard D, Malo JL. Longitudinal assessment of airway caliber and responsiveness in workers exposed to chlorine. *Am J Respir Crit Care Med* 1999;160(4):1232-1237.
18. Schwartz DA, Smith DD, Lakshminarayan S. The pulmonary sequelae associated with accidental inhalation of chlorine gas. *Chest* 1990;97(4):820-825.
19. Donnelly SC, FitzGerald MX. Reactive airways dysfunction syndrome (RADS) due to chlorine gas exposure. *Ir J Med Sci* 1990;159(9-12):275-276; discussion 276-277.
20. Demnati R, Fraser R, Martin JG, Plaa G, Malo JL. Effects of dexamethasone on functional and pathological changes in rat bronchi caused by high acute exposure to chlorine. *Toxicol Sci* 1998;45(2):242-246.
21. Gunnarsson M, Walther SM, Seidal T, Lennquist S. Effect of inhalation of corticosteroids immediately after experimental chlorine gas lung injury. *J Trauma* 2000;48(1):101-107.
22. Wang J, Zhang L, Walther SM. Inhaled budesonide in experimental chlorine gas lung injury: influence of time interval between injury and treatment. *Intensive Care Med* 2002;28(3):352-357.
23. Chester EH, Kaimal J, Payne CB Jr, Kohn PM. Pulmonary injury following exposure to chlorine gas: possible beneficial effects of steroid treatment. *Chest* 1977;72(2):247-250.
24. Bosse GM. Nebulized sodium bicarbonate in the treatment of chlorine gas inhalation. *J Toxicol Clin Toxicol* 1994;32(3):233-241.