

# Case Reports

---

## Pneumonia Due to *Cryptococcus neoformans* in a Patient Receiving Infliximab: Possible Zoonotic Transmission From a Pet Cockatiel

Rabin K Shrestha MD, James K Stoller MD MSc FAARC, Golar Honari MD, Gary W Procop MD, and Steven M Gordon MD

**The use of humanized antibody against tumor necrosis factor alpha (TNF- $\alpha$ ) may increase the risk of various opportunistic infections, including tuberculosis and fungal infections. We report a case of cryptococcal pneumonia in a patient who was taking infliximab for rheumatoid arthritis. A temporally related exposure history raised the possibility that our patient acquired the infection from his pet cockatiel. It seems prudent to advise patients receiving infliximab to avoid exposure to pet avian excreta.**

*Key words:* cryptococcosis, *Cryptococcus*, infliximab, pneumonia, tumor necrosis factor, zoonosis, immunocompromised host. [Respir Care 2004;49(6):606–608. © 2004 Daedalus Enterprises]

### Introduction

Since the Food and Drug Administration approved the use of tumor necrosis factor alpha (TNF- $\alpha$ ) antagonists for inflammatory conditions such as Crohn disease and rheumatoid arthritis, drugs such as infliximab have found widespread use. TNF- $\alpha$  has been found to play a role in conferring immunity against cryptococcal infection in animal models, and the use of infliximab has been associated with fungal and mycobacterial infection; several patients receiving infliximab have developed cryptococcal infections. We report a patient who developed cryptococcal pneumonia soon after the initiation of infliximab. Because our patient tended to a pet cockatiel prior to becoming ill, we speculate that our patient's cryptococcal infection was a zoonotic infection. This case report therefore extends experience with infliximab as a drug that may predispose to fungal infection and should prompt clinicians to consider

potential sources of zoonotic transmission in patients using infliximab and similar drugs.

### Case Report

A 65-year-old nonsmoking man was admitted to a tertiary care hospital for left-lower-lobe pneumonia and fever despite oral antibiotics. He had a pet cockatiel at home, and though the bird was usually tended by his wife, he had cleaned the cockatiel's cage 1 week before onset of his symptoms.

He had a longstanding history of rheumatoid arthritis, for which he had been taking methotrexate (15 mg/wk) and hydroxychloroquine (200 mg/d) for years. Though never on systemic corticosteroids, he was initiated on infliximab 10 weeks before admission, for persisting knee pain, and had received a total of three 200-mg doses, the most recent of which was administered 4 weeks before his initial presentation (and 6 weeks before admission).

He initially presented 2 weeks before admission, when he experienced fever to 39.5°C, a nonproductive cough, and a left-lower-lobe infiltrate identified by chest radiograph. After failure to defervesce with 1 week of oral levofloxacin and a second week of oral clarithromycin, he was admitted to the hospital, where intravenous ceftriaxone and azithromycin were initiated and pulmonary consultation was sought.

Physical examination on admission showed a fever of 38.1°C, a respiratory rate of 18 breaths/min, no evidence of acute distress, and evidence of consolidation at the left lung base. A chest radiograph and computed tomogram

---

Rabin K Shrestha MD and Gary W Procop MD are affiliated with the Section of Clinical Microbiology, Department of Clinical Pathology; James K Stoller MD MSc FAARC is affiliated with the Division of Medicine and the Section of Respiratory Therapy, Department of Pulmonary, Allergy, and Critical Care Medicine; Golar Honari MD is affiliated with the Department of General Internal Medicine; Steven M Gordon MD is affiliated with the Department of Infectious Diseases—The Cleveland Clinic Foundation, Cleveland, Ohio.

Correspondence: Rabin K Shrestha MD, L4, Division of Microbiology, The Cleveland Clinic Foundation, 9500 Euclid Avenue, Cleveland OH 44195. E-mail: shrestr@ccf.org.

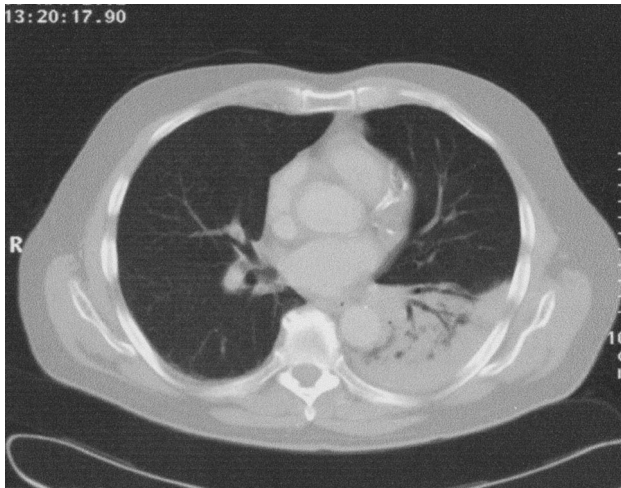


Fig. 1. Computed tomogram showing left-lower lobe consolidation with air bronchograms.

(Fig. 1) confirmed a lower-lobe infiltrate with air bronchograms.

Because of persisting fever and his immunocompromised state, bronchoscopy was recommended and performed. The endobronchial examination was normal and lavage of the left lower lobe showed no organisms on stains but grew *Cryptococcus neoformans*. Infection with *Cryptococcus* was confirmed by transbronchial biopsy, which showed granulomatous inflammation and fungal organisms on Grocott-Gomori methenamine-silver stain (Fig. 2). Blood cultures and cerebrospinal fluid cultures were sterile and both tested negative for cryptococcal antigen. A test for human immunodeficiency virus was negative, and his CD4<sup>+</sup> count was 1,323 cells/mL. Notably, cultures of the pet cockatiel's feces and cloaca did not grow *Cryptococcus*.

Treatment with fluconazole (200 mg/d for 28 d) was undertaken and his symptoms and the infiltrate resolved. Infliximab was discontinued; the patient has not had recurrence of cryptococcosis after 1 year of follow-up.

### Discussion

In presenting a patient who contracted cryptococcal pneumonia soon after receiving infliximab (a humanized antibody to TNF- $\alpha$ ) and after direct exposure to the family's pet cockatiel, the current report raises suspicion of possible fungal zoonotic transmission to a patient immunocompromised by infliximab.

Our belief that infliximab predisposed to fungal infection is supported by prior reports of opportunistic infections in patients receiving anti-TNF therapy, often with intracellular organisms such as *Mycobacterium*, *Histoplasma*, *Listeria*, and *Pneumocystis*.<sup>1</sup> The most convinc-

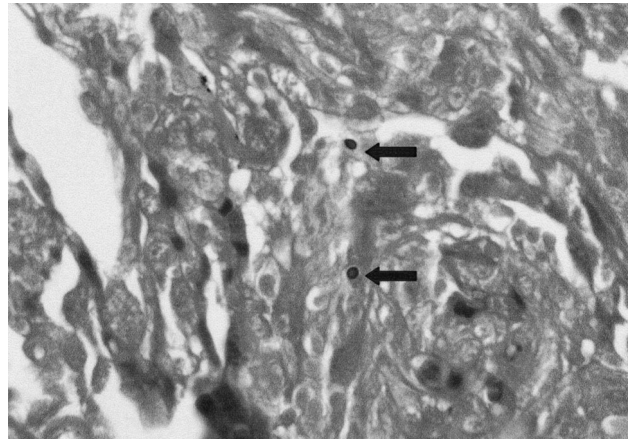


Fig. 2. Transbronchial biopsy specimen stained with Grocott-Gomori methenamine-silver stain and showing *Cryptococcus neoformans* (indicated by arrows).

ing example is a recent report in which the incidence of tuberculosis was found to be several-fold higher in persons receiving infliximab than in the general population, with a higher proportion having disseminated disease.<sup>2</sup> Furthermore, experiments with mice have shown that TNF- $\alpha$  antagonists predispose to severe infection with *Cryptococcus* if the TNF- $\alpha$  antagonists are given at the time of exposure to the organism.<sup>3</sup>

We are aware of several previous reports of cryptococcosis in patients receiving infliximab. One participant in a blinded trial developed cryptococcal pneumonia<sup>4</sup> and was later found to have received 2 doses of infliximab (personal communication, data on file, Centocor Inc, Malvern PA, 2003). In a second case, True et al reported a 69-year-old man with longstanding rheumatoid arthritis and type 2 diabetes who developed pancytopenia, chest radiograph infiltrates, and fever 8 weeks after his fifth infliximab infusion. Blood cultures and biopsy of a lung lesion revealed *Cryptococcus*. Cerebrospinal fluid was normal.<sup>5</sup> Third, Starrett et al reported a 44-year-old man with rheumatoid arthritis who was on methotrexate, leflunomide, and low-dose prednisone. He received infliximab monthly and after his third dose developed a cryptococcal pneumonia.<sup>6</sup> Fourth, Hage et al reported a 61-year-old man with rheumatoid arthritis who was on low-dose prednisone, methotrexate, and leflunomide and who had a right-lower-lobe parenchymal lung lesion 3 weeks after his third dose of infliximab. Biopsy of the lesion showed fungal organisms that grew *Cryptococcus*.<sup>7</sup> Finally, in searching for granulomatous infections reported to the Food and Drug Administration's adverse event reporting system,<sup>8</sup> Ruderman and Markenson found 5 cases of cryptococcosis associated with etanercept therapy and 4 cases associated with infliximab.

Although our failure to identify *Cryptococcus* in the cockatiel's feces precludes establishing zoonotic transmission in our patient, 2 lines of reasoning justify this suspicion. First, prior reports demonstrate the presence of *Cryptococcus* in various avian species' feces, including chickens, parrots, sparrows, starlings, turtledoves, canaries, and sky-larks.<sup>9</sup> Second, zoonotic transmission of *Cryptococcus neoformans* to humans from birds has been previously documented.<sup>10</sup> Specifically, intense exposure to pigeon excreta has been associated with development of cryptococcal meningitis in patients suffering acquired immunodeficiency syndrome.<sup>11</sup> At the same time, it must be noted that *Cryptococcus neoformans* has been found in many other environmental sources (eg, house dust, air, air conditioners, soils, and sawdust),<sup>12</sup> so other sources for our patient's infection cannot be excluded. Similarly, the possibility of reactivation of latent cryptococcal infection cannot be excluded.<sup>12</sup> Still, the reasonable concern that our patient may have acquired cryptococcal infection from aerosolized excreta while he was cleaning his cockatiel's cage should prompt clinicians caring for patients receiving TNF- $\alpha$  antagonists to suspect domestic birds as potential infection sources and to advise patients to avoid such exposures.

Noninfectious and potentially serious adverse effects have been associated with TNF- $\alpha$  antagonists, including infusion reactions, congestive heart failure, drug-induced lupus, and central nervous system demyelination.<sup>13</sup> Infliximab is currently approved for rheumatoid arthritis and Crohn disease, and it has shown encouraging results in the treatment of other illnesses, including sarcoidosis, uveitis, ankylosing spondylitis, and Sjögren's syndrome.<sup>1</sup> As indications for infliximab and related drugs expand, awareness of those drugs' potential infectious and noninfectious adverse effects should be emphasized.

### Conclusion

Our report contributes to the list of opportunistic infections associated with TNF- $\alpha$  neutralizing agents and suggests the possibility of zoonotic transmission from a pet cockatiel. On this basis, it seems prudent to advise patients

receiving infliximab to avoid exposure to pet avian excreta.

### ACKNOWLEDGMENT

We acknowledge the kind assistance of Steven J Shaw DVM, who helped us obtain specimens from the cockatiel.

### REFERENCES

1. Shanahan JC, St Clair W. Tumor necrosis factor- $\alpha$  blockade: a novel therapy for rheumatic disease. *Clin Immunol* 2002;103(3 Pt 1):231–242.
2. Keane J, Gershon S, Wise RP, Mirabile-Levens E, Kaszinca J, Schwieterman WD, et al. Tuberculosis associated with infliximab, a tumor necrosis factor  $\alpha$ -neutralizing agent. *N Engl J Med* 2001;345(15):1098–1104.
3. Huffnagle GB, Toews GB, Burdick MD, Boyd MB, McAllister KS, McDonald RA, et al. Afferent phase production of TNF- $\alpha$  is required for the development of protective T cell immunity to *Cryptococcus neoformans*. *J Immunol* 1996;157(10):4529–4536.
4. Warris A, Bjorneklett A, Gaustad P. Invasive pulmonary aspergillosis associated with infliximab therapy (letter). *N Engl J Med* 2001;344(14):1099–1100.
5. True DG, Penmetcha M, Peckham SJ. Disseminated cryptococcal infection in rheumatoid arthritis treated with methotrexate and infliximab. *J Rheumatol* 2002;29(7):1561–1563.
6. Starrett WG, Czachor J, Dallal M, Drehmer T. Cryptococcal pneumonia following treatment with infliximab for rheumatoid arthritis (abstract). Program and abstracts of the 40th annual meeting of the Infectious Diseases Society of America; 2002 October 24–27; Chicago, USA. Abstract no. 374.
7. Hage CA, Wood KL, Winer-Muram HT, Wilson SJ, Sarosi G, Knox KS. Pulmonary cryptococcosis after initiation of anti-tumor necrosis factor- $\alpha$  therapy. *Chest* 2003;124(6):2395–2397.
8. Ruderman EM, Markenson JA. Granulomatous infections and tumor necrosis factor antagonist therapies (abstract). Proceedings of the Annual European Congress of Rheumatology EULAR; 2003 June 18–21; Lisbon, Portugal. Abstract no. THU0209.
9. Levitz SM. The ecology of *Cryptococcus neoformans* and the epidemiology of cryptococcosis. *Rev Infect Dis* 1991;13(6):1163–1169.
10. Nosanchuk JD, Shoham S, Fries BC, Shapiro DS, Levitz SM, Casadevall A. Evidence of zoonotic transmission of *Cryptococcus neoformans* from a pet cockatoo to an immunocompromised patient. *Ann Intern Med* 2000;132(3):205–208.
11. Fessel WJ. Cryptococcal meningitis after unusual exposure to birds (letter). *N Engl J Med* 1993;328(18):1354–1355.
12. Casadevall A, Perfect JR. *Cryptococcus neoformans*. Washington DC: ASM Press; 1998:47–55.
13. Mikuls TR, Moreland LW. Benefit-risk assessment of infliximab in the treatment of rheumatoid arthritis. *Drug Saf* 2003;26(1):23–32.