

Capnographic Waveforms in the Mechanically Ventilated Patient

John E Thompson RRT FAARC and Michael B Jaffe PhD

Introduction
History of the Capnogram
The Normal Capnogram
Airway Management
Cardiopulmonary Resuscitation
Mechanical Ventilation
Neonatal Applications
The Volumetric Capnogram
Summary

A focus on patient safety has heightened the awareness of patient monitoring. The importance of clinical applications of capnography continues to grow, as reflected by the increasing number of medical societies recommending its use. Recognition of changes in the capnogram assists in clinical decision making and treatment and can increase patient safety by alerting the clinician to important situations and changes. This article describes the interpretation of capnograms and how capnogram interpretation influences airway management. Key words: capnography, capnogram, volumetric capnography, carbon dioxide rebreathing, mechanical ventilation. [Respir Care 2005;50(1):100–108. © 2005 Daedalus Enterprises]

Introduction

Carbon dioxide (CO₂) is the most abundant gas produced by the human body. The removal of CO₂ is the primary drive to breathe and a primary motivation for mechanically ventilating a patient. Monitoring the CO₂ level during respiration (capnography) is noninvasive, easy to do, relatively inexpensive, and has been studied extensively. Medical societies, representing anesthesiology,^{1,2}

cardiology,³ critical care,⁴ pediatrics,⁵ respiratory care,⁶ and emergency medicine⁷ mandate or recommend capnography. The capnogram is a graphical representation of the level of exhaled CO₂, and it reflects both physiologic and anatomical changes. This article reviews the clinical utility of time-based and volume-based capnograms.

History of the Capnogram

Physiologists recognized early on that continuous analysis of CO₂ is important to the measurement and understanding of intrapulmonary gas mixing and ventilation/perfusion relationships. The importance of continuous analysis of CO₂ has been further “enhanced by simultaneous analysis of gas volumes.”⁸ However, those instruments “are rather complex and . . . not generally available.”⁸

Elam et al, researching the problem of CO₂ elimination from closed-circuit anesthesia systems, were among the first to report on simultaneously recorded capnography and flow profiles of human respiration.^{9,10} Their seminal

John E Thompson RRT FAARC is affiliated with the Respiratory Care Department, Children’s Hospital, Boston, Massachusetts. Michael B Jaffe PhD is with Respirionics-Novametrix, Wallingford, Connecticut.

John E Thompson RRT FAARC presented a version of this article at the 34th RESPIRATORY CARE Journal Conference, Applied Respiratory Physiology: Use of Ventilator Waveforms and Mechanics in the Management of Critically Ill Patients, held April 16–19, 2004, in Cancún, Mexico.

Correspondence: John E Thompson RRT FAARC, Respiratory Care Department, Children’s Hospital, 300 Longwood Avenue, Boston MA 02115. E-mail: john.thompson@childrens.harvard.edu.

work on CO₂ homeostasis was published in a series of 4 papers.^{11–14} That research included both normal and abnormal characteristics of the capnographic profile and measurements of dead space and alveolar ventilation.

In 1957, Smalhout, who is considered by many the father of clinical capnography, began using capnographs while working in the Central Military Hospital of Utrecht, The Netherlands.¹⁵ During a 7-year period leading up to the publication of his doctoral thesis in 1967,¹⁶ Smalhout collected approximately 6,000 capnograms, which documented numerous shape variations.¹⁵ Smalhout and Kalenda¹⁷ later published an atlas of strip-chart capnograms that illustrated many of the applications of capnography. However they noted that their research represented “little more than the surface of a deep pool.”¹⁷ That atlas and Smalhout’s frequent lectures on capnography helped popularize the use of the terms “capnography,” “capnograph,” and “capnogram.” Weingarten¹⁸ summarized Smalhout and Kalenda’s contributions:

Under their direction, capnography survived a stormy gestation period as it reached maturity in The Netherlands. It was introduced in the United States at a small private meeting sponsored by a major instrument manufacturer, held in conjunction with the World Congress on Intensive Care Medicine in Washington DC, in May 1978. Five anesthesiologists attended the meeting, 2 of whom concluded that capnography would prove to be of very little value.

The earliest description in the literature of the volumetric capnogram and a method to determine “airway” dead space was from Aiken and Clark-Kennedy, in 1928.¹⁹ In 1948, Fowler,²⁰ described the *single-breath test for nitrogen curve*, in seeking to use uniform terminology to clarify the “meaning of dead space.” He thus divided the volumetric capnogram curve into 4 phases (I, II, III, and IV).

The term “infrared CO₂ meter” was used from the 1950s and to the early 1970s, when the term “capnograph” was derived from the Godart Capnograph.

Single-breath CO₂ curves appeared in the literature as early as 1961.²¹ The concepts of dead space and CO₂ elimination were not presented in a unified framework, however, until Fletcher published his 1980 doctoral thesis²² and later publications.²³ His method became widely known as the *single-breath test* or *single-breath CO₂ curve*.

The Normal Capnogram

The normal capnogram has multiple features that allow for clinical interpretation (Fig. 1). There are no widely accepted standards for labeling of the normal capnogram.^{17,24,25} A capnogram is a time-tracing of CO₂ concentration. A capnograph has 2 recording speeds. The fast

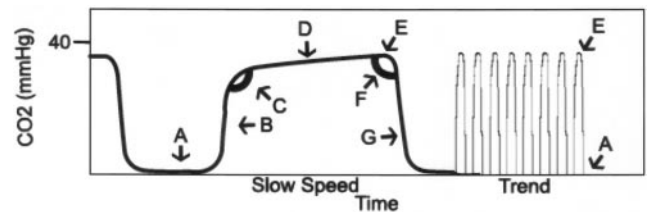


Fig. 1. Normal features of a capnogram. A: *Baseline*, represents the beginning of expiration and should start at zero. B: The *transitional* part of the curve represents mixing of dead space and alveolar gas. C: The *alpha angle* represents the change to alveolar gas. D: The *alveolar* part of the curve represents the plateau average alveolar gas concentration. E: The *end-tidal carbon dioxide* value. F: The *beta angle* represents the change to the inspiratory part of the cycle. G: The *inspiration* part of the curve shows a rapid decrease in carbon dioxide concentration.

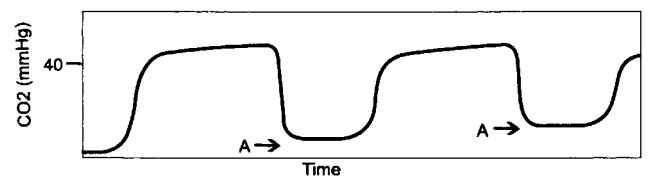


Fig. 2. Capnogram with a rising baseline (A).

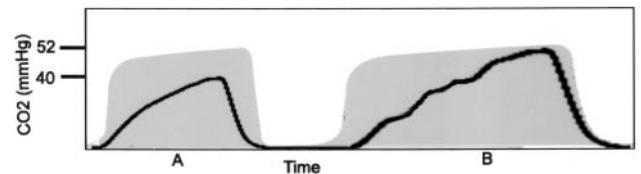


Fig. 3. Capnogram from a patient with chronic respiratory disease shows (A) transition phase is longer than normal (shaded area). B: A large tidal volume with a prolonged expiratory phase reflects P_{aO₂}.

speed is approximately 12.5 mm/s, which allows interpretation of short-term changes. The slow speed is approximately 25 mm/min, which allows for identifying long-term trends. Changes in the capnogram suggest changes in the patient’s condition. Proper interpretation of the capnogram can alert a clinician to important changes and should include at least the examination of 3 key features: baseline starting at zero; sharp increase in CO₂ concentration; and steady alveolar plateau.

An elevation of the baseline (Fig. 2) indicates clinically important rebreathing of CO₂, which may be due to mechanical problems^{26–28} or therapeutic use of mechanical dead space.

Chronic disease of the lungs and airways prolongs the transitional portion of the capnogram (Fig. 3). Slow-time-constant alveolar units continue to mix alveolar gas with dead-space gas. Prolonging the expiratory phase allows the end-tidal CO₂ (P_{ETCO₂}) to be more reflective of P_{aCO₂}.

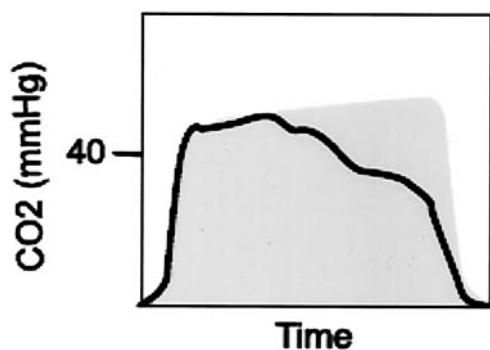


Fig. 4. A capnogram with a loss of the alveolar phase during expiration suggests pneumothorax. The shaded area represents a normal capnogram.

That decrease in the P_{ETCO_2} -to- P_{aCO_2} difference represents a decrease in dead space, and that decrease in dead space is helpful when contrasting a spontaneous breath to that of a breath delivered by a ventilator.

Inability to maintain a plateau phase may be indicative of a pneumothorax. Figure 4 illustrates the “melting away” of the alveolar plateau (ie, a dramatic change in the mean alveolar CO_2 concentration). After observing a falling blood-oxygen saturation, the clinician ordered a chest radiograph for this patient, who had a chest tube in place. On observation of this “melting away” of the capnogram, the chest tube was stripped. The capnogram then returned to normal and the patient’s oxygen saturation was again stable by the time the portable radiograph arrived at the bedside, so the radiograph procedure was canceled.

Airway Management

Capnography can help confirm the placement of an endotracheal tube (ETT) into the trachea (or misplacement into the esophagus), and can be used in various clinical environments, including in the field (by emergency medical services workers), and in the emergency department, intensive care unit, neonatal intensive care unit, and delivery room.^{29–33} During ETT placement the capnogram can rapidly alert the clinician to ETT misplacement in the esophagus. A capnogram from an esophageally-placed ETT is usually a different shape and size than a normal tracheal capnogram. Additionally, capnographic waveforms from the esophagus will generally be present only for a few breaths. The shape difference between tracheal and esophageal placement is clearly visible in adults (Fig. 5)³¹ and neonates (Fig. 6),³⁴ with rare exceptions.³⁵ CO_2 in the esophagus, which is usually present from CO_2 in the stomach due to exhaled gas, is removed in seconds. In neonates with low pulmonary perfusion and intracardiac shunt, the capnogram waveform may be diminished in amplitude (Fig. 7). After the initial placement and securing of the ETT,

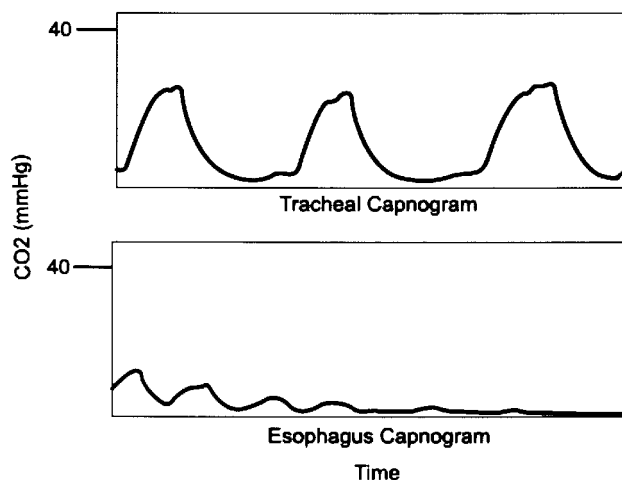


Fig. 5. Adult capnograms of tracheal intubation (above) and esophageal capnogram (below). (Adapted from Reference 31, with permission.)

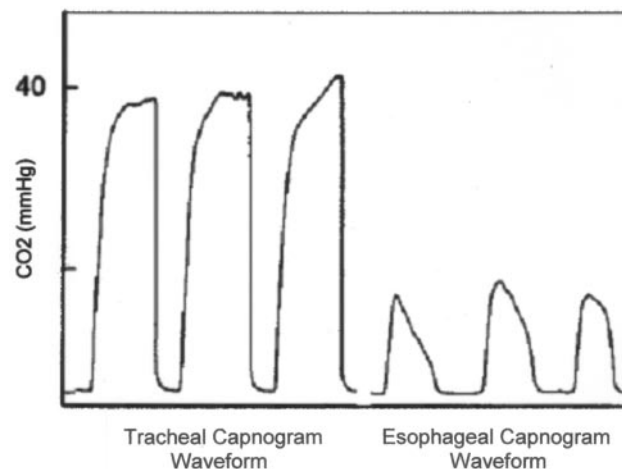


Fig. 6. Neonatal capnograms of tracheal intubation (left) and esophageal intubation (right). (Adapted from Reference 34, with permission.)

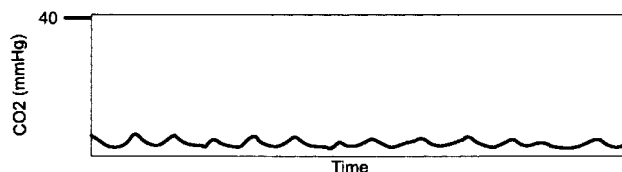


Fig. 7. Capnogram from a neonate with congenital intracardiac shunt. (Adapted from Reference 31, with permission.)

changes in ETT position can cause abrupt changes in the capnogram (Fig. 8). For example, the procedure of turning and flexing a patient to position him for a spinal tap resulted in a right main-bronchus migration of the ETT that was first indicated by a change in the capnogram. This alerted the clinician, who repositioned the ETT and com-

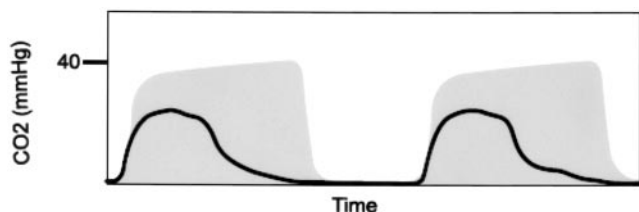


Fig. 8. Acute change in capnogram from normal (shaded area). The endotracheal tube was in the right main bronchus.

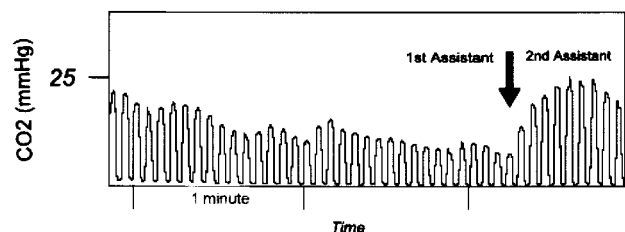


Fig. 9. Capnogram from a patient undergoing chest compressions. Note that the capnogram curve changes at the point at which a "fresh" (less tired) clinician (assistant) took over the chest compressions. (Adapted from Reference 42, with permission.)

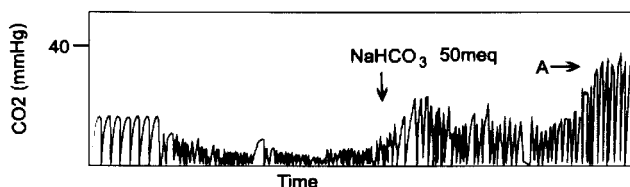


Fig. 10. Capnogram during successive stages of cardiopulmonary resuscitation, with (A) return of spontaneous circulation. The arrow labeled NaHCO₃ indicates the point at which sodium bicarbonate was administered. (Adapted from Reference 43, with permission.)

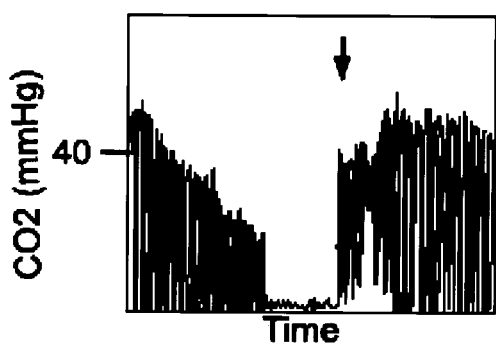


Fig. 11. Capnogram during cardiac arrest with rebreathing.

pleted the procedure. Rapid recognition of changes in ETT placement can also avoid other problems, such as desaturation. However, though the presence of CO₂ in the ETT increases confidence that the ETT is properly placed, it does not assure that it is properly placed. Endobronchial intubation can have a normal-appearing capnogram. Proper

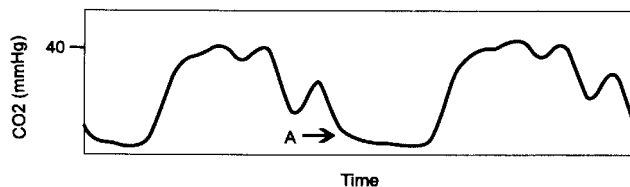


Fig. 12. Capnogram indicating a fluttering expiratory valve with rebreathing (A). (Adapted from Reference 44, with permission.)

ETT placement should be confirmed with multiple techniques.³⁶

As the lack of CO₂ is used to determine improper ETT placement, the presence of CO₂ is increasingly being used to identify improper nasogastric or oral feeding-tube placement.³⁷⁻⁴¹

Cardiopulmonary Resuscitation

Capnography has long been used for rapid evaluation of the effectiveness of chest compressions.⁴² CO₂ removal is more effective when a less fatigued person performs the cardiopulmonary resuscitation (Fig. 9). Falk et al⁴³ found changes in CO₂ removal during successive stages of cardiopulmonary resuscitation (Fig. 10). This included the administration of sodium bicarbonate, resulting in the by-product of CO₂ and the successful return to spontaneous circulation, shown as a dramatic increase in CO₂ removal. A mechanical problem during cardiopulmonary resuscitation can be quickly recognized with the aid of a capnogram. Figure 11 illustrates a clinical situation in which the flow to a non-self-inflating resuscitation bag was set too low, so the CO₂ was not being adequately washed out of the bag and there was excessive rebreathing of CO₂, which was identified via the capnogram. The flow was increased and CO₂ returned to baseline.

Mechanical Ventilation

A paper by Carlon et al included a wide range of capnographic waveforms from mechanically ventilated patients,⁴⁴ which supported the view that capnography assists in quickly identifying and resolving clinical and technical problems. We will discuss several of the capnograms from that paper.

Figure 12 illustrates the capnogram pattern from a fluttering expiratory valve, which can be caused by water condensation or pressure compensation by the ventilator. Note that some rebreathing is present.

Figure 13 illustrates conflict between mandatory breaths (ie, delivered by the ventilator) and spontaneous breaths (ie, there was patient-ventilator asynchrony during intermittent mandatory ventilation).




Fig. 13. Capnogram indicating patient-ventilator asynchrony during intermittent mandatory ventilation. The arrows indicate spontaneous breaths. (Adapted from Reference 44, with permission.)

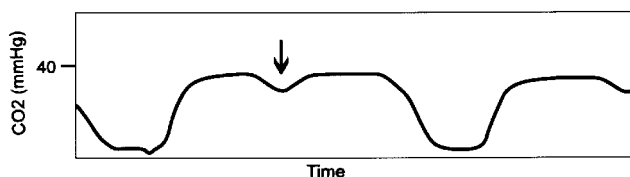


Fig. 14. Capnogram in which the arrow points to a small spontaneous inspiratory effort that did not trigger the ventilator. (Adapted from Reference 44, with permission.)

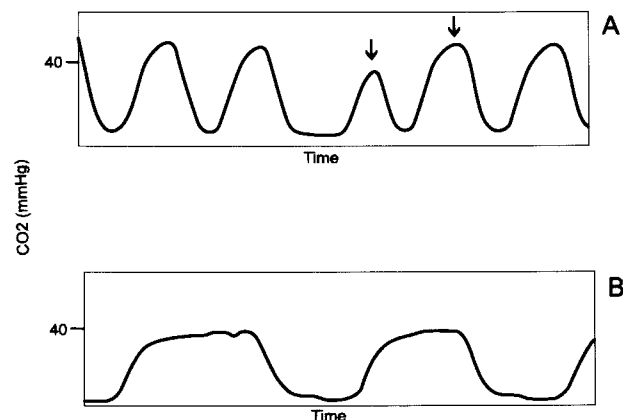


Fig. 15. Erect-posture breathing patterns with rebreathing. A: Arrows indicate changing end-tidal carbon dioxide without pressure support. B: Normalized capnogram from the same patient after applying pressure support of 20 cm H₂O. (Adapted from Reference 44, with permission.)

Figure 14 illustrates a situation in which a small respiratory effort was not detected by the ventilator during the expiratory phase. In that situation the triggering sensitivity may need to be adjusted.

Figure 15A illustrates an erratic pattern and varying P_{ETCO_2} . The figure shows no alveolar plateau and some rebreathing. Figure 15B shows that the breathing pattern and capnogram were normalized with pressure support of 20 cm H₂O.

Figure 16 illustrates a chaotic, rapid respiratory pattern, with spontaneous breaths during mandatory (ventilator-delivered) breaths, and rebreathing, which can indicate failure of a weaning trial.

Frequent alteration of a mechanically ventilated patient's position is common practice. Figure 17 illustrates how

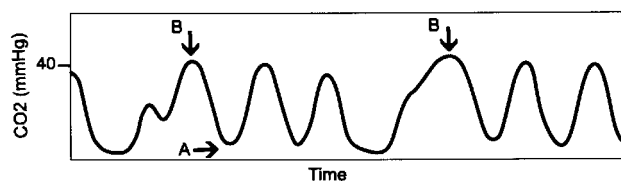


Fig. 16. Capnogram indicating weaning failure. There is chaotic, rapid breathing, with rebreathing (A). Spontaneous breaths (B) during mandatory (ventilator-delivered) breaths. (Adapted from Reference 44, with permission.)

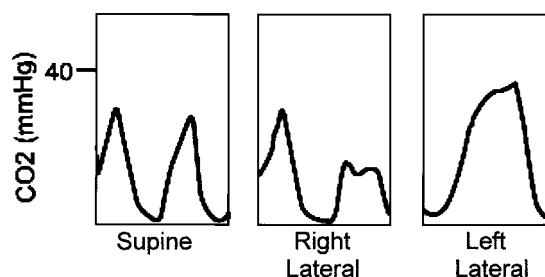


Fig. 17. Changes in capnogram with changes in patient position.

changing the patient's position can affect the capnogram. While supine, the patient had a high P_{aCO_2} and an abnormal capnogram. In the right-lateral position the capnogram deteriorated even more. In the left-lateral position the capnogram showed a normal waveform, with an alveolar plateau and a much lower P_{aCO_2} . That change in ventilation/perfusion matching allowed ventilator adjustment.

Neonatal Applications

The use of capnography during mechanical ventilation of neonates is less documented in the literature. The additional dead space, weight, mechanical problems,⁴⁵ phase delay,⁴⁶ and the use of uncuffed ETTs may limit the clinical value of capnography with neonates.

Arsowa et al⁴⁷ presented a series of capnograms that illustrate that the physiologic changes revealed by neonatal capnograms are consistent with the physiologic changes in adults. However, the shape of the normal neonatal capnogram is different (Fig. 18). Because of the smaller dead space and higher respiratory rate, the normal neonatal capnogram has a shorter time at baseline, a sharper rise in CO₂ concentration, and little if any alveolar plateau.

Administration of surfactant alters respiratory mechanics and changes the rate of alveolar emptying, which is reflected on the capnogram (Fig. 19). Before the administration of surfactant, the capnogram has an elevated baseline, the transitional phase has a prolonged slope, and there is no alveolar plateau. After the administration of surfactant the capnogram returns to a normal shape.

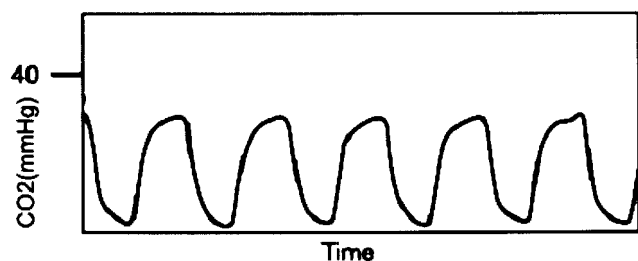


Fig. 18. Normal neonatal capnogram. (Adapted from Reference 47, with permission.)

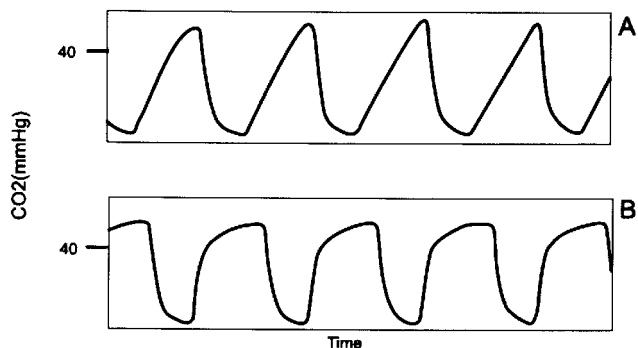


Fig. 19. Capnogram (A) before surfactant (B) after surfactant. (Adapted from Reference 47, with permission.)

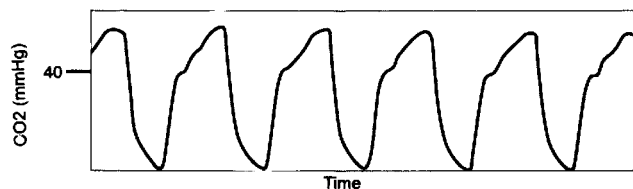


Fig. 20. Capnogram from a neonate with pneumonia. (Adapted from Reference 47, with permission.)

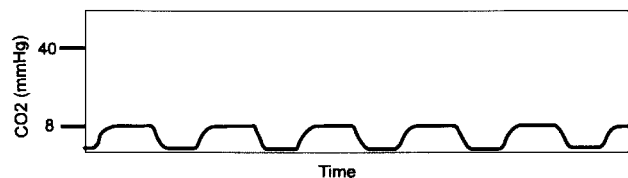


Fig. 21. Capnogram from a neonate with transposition of the great vessels. (Adapted from Reference 47, with permission.)

The capnogram of a neonate with pneumonia shows biphasic emptying of the lung (Fig. 20). Different time constants cause a varying rate of CO₂ removal.

A normal capnogram with a large difference between P_{ETCO₂} and P_{aCO₂} indicates substantial physiologic dead space (Fig. 21). Right-to-left cardiac shunt diverts blood away from the lung. Cardiac shunt reflects an increase in pulmonary dead space.

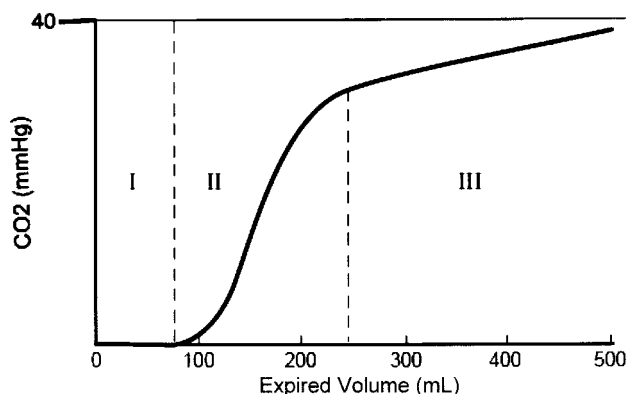


Fig. 22. The 3 phases of a volumetric capnogram. Phase I: The volume of carbon-dioxide-free gas. Phase II: Transition from carbon-dioxide-free gas with the volume of early-emptying alveoli. Phase III: Alveolar plateau with a positive slope that indicates a slowly rising volume of carbon dioxide. (Adapted from Reference 49, with permission.)

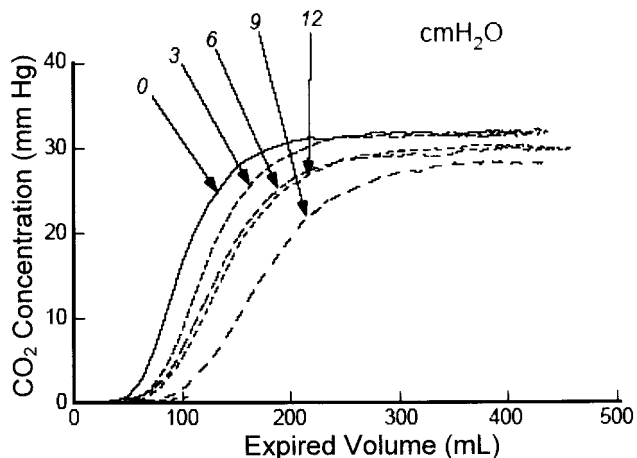


Fig. 23. Changes in the slope of phase II (see Fig. 22) with changes in positive end-expiratory pressure (0, 3, 6, 9, and 12 cm H₂O).

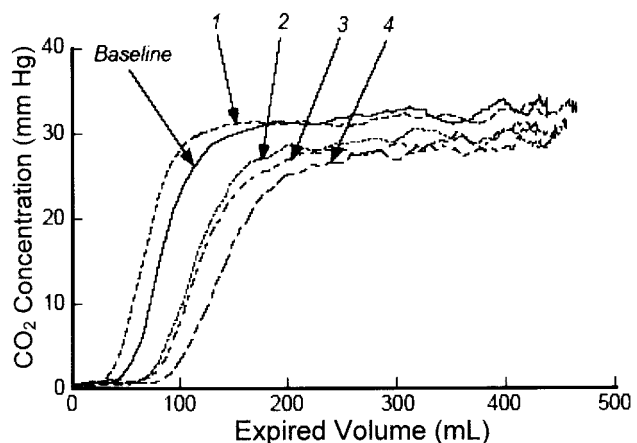


Fig. 24. Changes in the slope of phase II (see Fig. 22) with changes in pulmonary perfusion. Increasing numbers (by arrows) represent decreasing pulmonary blood flow.

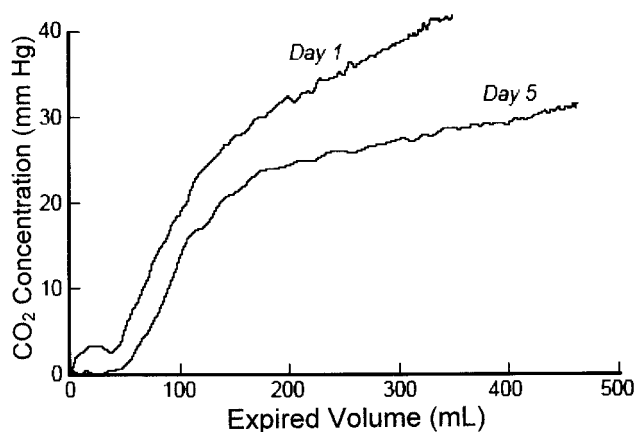


Fig. 25. Changes in the volumetric capnogram with acute bronchospasm. Day 1 capnogram returns to normal by day 5.

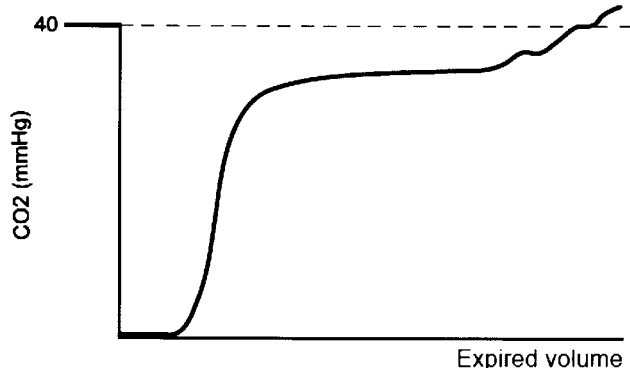


Fig. 26. Concave volumetric capnogram associated with obesity. (Adapted from Reference 49, with permission.)

The Volumetric Capnogram

The normal volumetric capnogram has the same general features as the time-based capnogram. The volumetric capnogram, which traces CO_2 concentration against exhaled volume, is divided into 3 phases (Fig. 22). Using features of each phase, physiologic measurements can be calculated.

Changes in positive end-expiratory pressure (PEEP) affect the volumetric capnogram (Fig. 23). Increasing PEEP shifts the capnogram and alters the slope of phase II. Changes in pulmonary blood flow can also shift the volumetric capnogram (Fig. 24). Currently, the shift is not clinically quantifiable, but optimal PEEP, perfusion, or drug therapy may be determined by measuring that change in slope.

The volumetric capnogram also reflects changes in airway resistance (Fig. 25). A patient with severe asthma demonstrates a prolonged transitional phase, which improves over time. Drug therapy may also be monitored, as with time-based capnography.⁴⁸

Concave phase-III volumetric capnograms have been seen with obese patients and patients with increased expi-

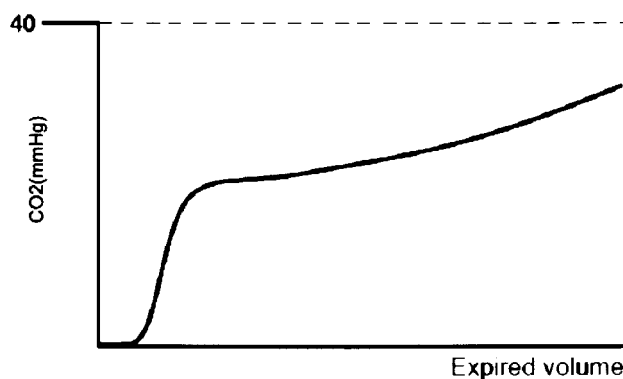


Fig. 27. Concave volumetric capnogram associated with increased airway resistance. (Adapted from Reference 49, with permission.)

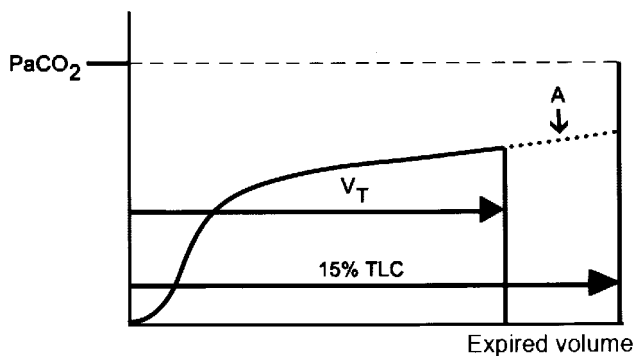


Fig. 28. Volumetric capnogram associated with pulmonary emboli. Extrapolated curve (A) to 15% of total lung capacity (TLC) (late dead space). V_T = tidal volume. (Adapted from Reference 50.)

ratory resistance. Obese patients (Fig. 26) can have biphasic emptying and higher $P_{ET\text{CO}_2}$ than $P_{a\text{CO}_2}$. That difference suggests varying mechanical and ventilation/perfusion properties. The increase in expiratory resistance (Fig. 27) may reflect a slow expiratory phase with a slow accumulation of alveolar CO_2 . The alveoli that empty last may have more time for CO_2 diffusion.⁴⁹

The volumetric capnogram has been used to diagnose pulmonary emboli. Extrapolated CO_2 at 15% of total lung capacity should be equal to $P_{a\text{CO}_2}$ (Fig. 28). When the extrapolated CO_2 is less than the $P_{a\text{CO}_2}$ by $> 12\%$, it suggests pulmonary emboli.⁵⁰ However, dead space of $< 50\%$ and a negative D-dimer safely rule out pulmonary emboli.⁵¹

Summary

The capnogram is an important tool for the clinician, in that it aids diagnosis and treatment and can increase patient safety by alerting the clinician to important situations and changes. The present review touches only on a few of the published works on capnography. Smalhout's collection of 6,000 capnograms illustrates a wide

range of capnographic possibilities. Smalhout states that the capnogram is the ECG of respiration. Just as the electrocardiogram is one indicator of cardiac health, the capnogram is an important adjunct to assessing respiratory function. Hopefully, additional research from clinicians will further the field and interpretation of capnograms.

REFERENCES

- American Society of Anesthesiologists (ASA). Basic standards for intraoperative monitoring; 1999.
- Wenzel V, Voelckel WG, Krismer AC, Mayr VD, Strohmeier HU, Baubin MA, et al; American Heart Association; European Resuscitation Council. [The new international guidelines for cardiopulmonary resuscitation: an analysis and comments on the most important changes.] *Anaesthesist* 2001;50(5):342–357. *Article in German*
- Guidelines 2000 for Cardiopulmonary Resuscitation and Emergency Cardiovascular Care. Part 6: advanced cardiovascular life support: section 3: adjuncts for oxygenation, ventilation and airway control. The American Heart Association in collaboration with the International Liaison Committee on Resuscitation. *Circulation* 2000;102(8 Suppl):I95–I104.
- Society of Critical Care Medicine. Task Force on Guidelines. Recommendations for services and personnel for delivery of care in a critical care setting. *Crit Care Med* 1988;16(8):809–811.
- American Academy of Pediatrics Committee on Drugs: Guidelines for monitoring and management of pediatric patients during and after sedation for diagnostic and therapeutic procedures. *Pediatrics* 1992; 89(6 Pt 1):1110–1115.
- American Association for Respiratory Care. AARC Clinical Practice Guideline: Capnography/capnometry during mechanical ventilation—2003 revision & update. *Respir Care* 2003;48(5):534–539.
- American College of Emergency Physicians: Expired carbon dioxide monitoring. *Ann Emerg Med* 1995;25(3):441.
- Fowler WS, Comroe JH Jr. Alveolar gas, method in medical research. Chicago: Year Book; 1950;2:219–226.
- Peppriell JE, Bacon DR, Lema MJ, Ament R, Yearley CK. The development of academic anesthesiology at the Roswell Park Memorial Institute: James O. Elam, MD, and Elwyn S. Brown, MD. *Anesth Analg* 1991;72(4):538–545.
- Sands RP Jr, Bacon DR. An inventive mind: the career of James O. Elam, M.D. (1918–1995). *Anesthesiology* 1998;88(4):1107–1112.
- Elam JO, Brown ES. Ten Pas RH Carbon dioxide homeostasis during anesthesia. I. Instrumentation. *Anesthesiology* 1955;16(11):876–885.
- Elam JO, Brown ES. Carbon dioxide homeostasis during anesthesia. II. Total sampling for determination of dead space, alveolar ventilation, and carbon dioxide output. *Anesthesiology* 1955;16(11):886–902.
- Elam JO, Brown ES. Carbon dioxide homeostasis during anesthesia. III. Ventilation and carbon dioxide elimination. *Anesthesiology* 1956; 17(1):115–127.
- Elam JO, Brown ES. Carbon dioxide homeostasis during anesthesia. IV. An evaluation of the partial rebreathing system. *Anesthesiology* 1956;17(1):128–134.
- Gravenstein JS, Jaffe MB, Paulus DA. Capnography: clinical aspects—carbon dioxide over time and volume. Cambridge UK: Cambridge University Press; 2004.
- Smalhout B. Capnografie (thesis) University of Utrecht, The Netherlands, Utrecht, The Netherlands: A Oosthoek Publishing Co; 1967.
- Smalhout B, Kalenda Z. An atlas of capnography, 2nd ed. Kerckebosche Zeist, The Netherlands; 1981.
- Weingarten M. Respiratory monitoring of carbon dioxide and oxygen: a ten-year perspective. *J Clin Monit* 1990;6(3):217–225.
- Aiken RS, Clark-Kennedy AE. On the fluctuation in the composition of the alveolar air during the respiratory cycle in muscular capacity. *J Physiol* 1928;65:389–411.
- Fowler WS. Lung function studies. II. The respiratory deadspace. *Am J Physiol* 1948;154:405–416.
- Berengo A, Cuttillo A. Single breath analysis of carbon dioxide records. *J Appl Physiol* 1961;16(3):522–530.
- Fletcher R. The single breath test for carbon dioxide (Thesis). Lund, Sweden; 1980.
- Fletcher R, Jonson B. Dead-space and the single breath test for carbon dioxide during anaesthesia and artificial ventilation: effects of tidal volume and frequency of respiration. *Br J Anaesth* 1984;56(2):109–119.
- Gravenstein JS, Paulus DA, Hayes TJ. Gas monitoring in clinical practice, 2nd ed. New York: Butterworth-Heinemann; 1995.
- Bhavani-Shankar K, Philip JH. Defining segments and phases of a time capnogram. *Anesth Analg* 2000;91(4):973–977.
- Pyles ST, Berman LS, Modell JH. Expiratory valve dysfunction in a semiclosed circle anesthesia circuit: verification by analysis of carbon dioxide waveform. *Anesth Analg* 1984;63(5):536–537.
- Kumar AY, Bhavani-Shankar K, Moseley HS, Delph Y. Inspiratory valve malfunction in a circle system: pitfalls in capnography. *Can J Anaesth* 1992;39(9):997–999.
- Podraza AG, Salem MR, Joseph NJ, Brenckley JL. Rebreathing due to incompetent unidirectional valves in the circle absorber system (abstract). *Anesthesiology* 1991;75:A422.
- Holland R, Webb RK, Runciman WB. The Australian Incident Monitoring Study. Oesophageal intubation: an analysis of 2000 incident reports. *Anaesth Intensive Care* 1993;21(5):608–610.
- Repetto JE, Donohue PA-C PK, Baker SF, Kelly L, Nogue LM. Use of capnography in the delivery room for assessment of endotracheal tube placement. *J Perinatol* 2001;21(5):284–287.
- Roberts WA, Maniscalco WM, Cohen AR, Litman RS, Chhibber A. The use of capnography for recognition of esophageal intubation in the neonatal intensive care unit. *Pediatr Pulmonol* 1995;19(5):262–268.
- Grmec S. Comparison of three different methods to confirm tracheal tube placement in emergency intubation. *Intensive Care Med* 2002; 28(6):701–704.
- Katz SH, Falk JL. Misplaced endotracheal tubes by paramedics in an urban emergency medical services system. *Ann Emerg Med* 2001; 37(1):32–37.
- Sum-Ping ST, Metha MP, Anderton JM. A comparative study of methods of detection of esophageal intubation. *Anesth Analg* 1989; 69(5):627–632.
- Asai T, Shingu K. Case report: a normal capnogram despite esophageal intubation. *Can J Anaesth* 2001;48(10):1025–1028.
- Li J. Capnography alone is imperfect for endotracheal tube placement confirmation during emergency intubation. *J Emerg Med* 2001; 20(3):223–229.
- Asai T, Stacey M. Confirmation of feeding tube position: how about capnography? (letter) *Anaesthesia* 1994;49(5):451.
- D'Souza CR, Kilam SA, D'Souza U, Janzen EP, Sipos RA. Pulmonary complications of feeding tubes: a new technique of insertion and monitoring malposition. *Can J Surg* 1994;37(5):404–408.
- Kindopp AS, Drover JW, Heyland DK. Capnography confirms correct feeding tube placement in intensive care unit patients. *Can J Anaesth* 2001;48(7):705–710.
- Burns SM, Carpenter R, Truweit JD. Report on the development of a procedure to prevent placement of feeding tubes into the lungs using end-tidal CO₂ measurements. *Crit Care Med* 2001;29(5):936–939.

41. Araujo-Preza CE, Melhado ME, Gutierrez FJ, Maniatis T, Castellano MA. Use of capnometry to verify feeding tube placement. *Crit Care Med* 2002;30(10):2255–2259.
42. Kalenda Z. The capnogram as a guide to the efficacy of cardiac massage. *Resuscitation* 1978;6(4):259–263.
43. Falk JL, Rackow EC, Weil MH. End-tidal carbon dioxide concentration during cardiopulmonary resuscitation. *N Engl J Med* 1988;318(10):607–611.
44. Carlon GC, Ray C Jr, Miodownik S, Kopec I, Groeger JS. Capnography in mechanically ventilated patients. *Crit Care Med* 1988;16(5):550–556.
45. Badgwell JM, Kleinman SE, Heavner JE. Respiratory frequency and artifact affect the capnographic baseline in infants. *Anesth Analg* 1993;77(4):708–712.
46. Pascucci R, Schena J, Thompson JE. Comparison of a sidestream and mainstream capnometer in infants. *Crit Care Med* 1989;17(6):560–562.
47. Arsowa S, Schmalisch G, Wauer R. [Techniques and clinical application of capnography in newborn infants and infants.] *Padiatr Grenzgeb* 1993;31(5):295–311. Article in German
48. Yaron M, Padyk P, Hutsinpieller M, Cairns CB. Utility of the expiratory capnogram in the assessment of bronchospasm. *Ann Emerg Med* 1996;28(4):403–407.
49. Fletcher R. The single breath test for carbon dioxide [dissertation]. Lund, Sweden: University of Lund, 1980. 2nd edition revised and reprinted, Solna, Sweden: Siemens Elema, 1986.
50. Anderson JT, Owings JT, Goodnight JE. Bedside noninvasive detection of acute pulmonary embolism in critically ill surgical patients. *Arch Surg* 1999;134(8):869–874; discussion 874–875.
51. Rodger MA, Jones G, Rasuli P, Raymond F, Djunaedi H, Bredeson CN, Wells PS. Steady-state end-tidal alveolar dead space fraction and D-dimer: bedside tests to exclude pulmonary embolism. *Chest* 2001;120(1):115–119.

Discussion

Bigatello: You mentioned that you put P_{ETCO_2} on-line when you place feeding tubes. I'm interested in that, because a feeding tube can go into the lungs, and a few of them also cause damage. We have a very specific protocol according to which, with intubated patients, we place every feeding tube under direct laryngoscopy. I do not have data to know whether that has decreased the incidence. But certainly measuring P_{ETCO_2} will be a possible adjunct. How do you fit your particular apparatus? Does it work well for you? Is it something that you suggest on a regular basis?

Thompson: There are several publications that describe the connections for adult patients.^{1–4} Our protocol calls for getting aspirates and measuring the pH before we use the feeding tube.

REFERENCES

1. Kindopp AS, Drover JW, Heyland DK. Capnography confirms correct feeding tube placement in intensive care unit patients. *Can J Anaesth* 2001;48(7):705–710.
2. Burns SM, Carpenter R, Truweit JD. Report on the development of a procedure to prevent placement of feeding tubes into the lungs using end-tidal CO_2 measurements. *Crit Care Med* 2001;29(5):936–939.
3. D'Souza CR, Kilam SA, D'Souza U, Janzen EP, Sapos RA. Pulmonary complications of feeding tubes: a new technique of insertion and monitoring malposition. *Can J Surg* 1994;37(5):404–408.

4. Araujo-Preza CE, Melhado ME, Gutierrez FJ, Maniatis T, Castellano MA. Use of capnometry to verify feeding tube placement. *Crit Care Med* 2002;30(10):2255–2259.

Harris: You showed a graph of the time to a steady-state CO_2 reading. How long does it normally take for CO_2 to equilibrate when you make a ventilator change? It always seems to take a very long time. And what does it depend on?

Thompson: In the majority of cases the change takes place within 20 minutes, but some patients come to full stabilization in 5–7 minutes.¹

REFERENCE

1. Taskar V, John J, Larsson A, Wetterberg T, Jonson B. Dynamics of carbon dioxide elimination following ventilator resetting. *Chest* 1995;108(1):196–202.

Blanch: I have a question regarding the pediatric population. Assessing-physiologic dead space in ARDS [acute respiratory distress syndrome] is useful to predict outcome. Do you know whether measuring dead space could also be useful in pediatric patients?

Thompson: Predicting outcome is very difficult. In pediatrics we have only about a 10–15% mortality rate with pediatric ARDS. I'm not sure that we're going to ever show any impact of these devices on pediatric

ARDS. The low incidence, high survival rate, and the use of ECMO [extracorporeal membrane oxygenation] limits the number of patients available for study.

Sanborn: Is it fair to say that CO_2 monitoring is mainly used as a check on what you've done rather than as a guide to doing something? It seems that if you make a ventilator change, CO_2 monitoring tells you whether your adjustment was OK, rather than looking at the CO_2 signal in whatever way and saying, "Oh I need to do this."

Thompson: I would say that's true with a single-breath CO_2 measurement, looking at CO_2 elimination. I'm not sure that's true with P_{ETCO_2} —with the capnograph waveform.

Durbin: About 20 years ago it was suggested that looking at the end-tidal-to-arterial CO_2 gradient is a way to optimize PEEP. The theory is that as you overdistend normal lung areas, you drive blood away from them, and therefore worsen \dot{V}/\dot{Q} [ventilation/perfusion ratio]. When you start with collapsed areas that start opening up, \dot{V}/\dot{Q} gets better. The balance between those 2 opposing effects allow you to optimize PEEP by simply looking at the end-tidal-to-arterial CO_2 gradient. That approach has not been widely used, to my knowledge, but it was reported.¹ Any thoughts on that approach?

REFERENCE

1. Murray IP, Modell JH, Gallagher TJ, Banner MJ. Titration of PEEP by the arterial minus end-tidal CO₂ gradient. *Chest* 1984; 85(1):100–104.

Thompson: I think we would be more apt to use V_D/V_T [the ratio of dead space to tidal volume] now with more modern equipment. But, yes, absolutely. I was brought up on the gradient that it's all dead space ventilation. Shunt has very little to do with that gradient, so you are increasing alveolar dead space when you widen the gradient. I agree.

Hess: On that subject I would refer to Lluís Blanch's 1987 paper.¹

REFERENCE

1. Blanch L, Fernandez R, Benito S, Mancebo J, Net A. Effect of PEEP on the arte-

rial minus end-tidal carbon dioxide gradient. *Chest* 1987;92(3):451–454.

Blanch: Yes. We studied the effect of PEEP on the arterial minus end-tidal CO₂ gradient in patients with acute lung injury. At similar cardiac output, the gradient decreased with PEEP, equal to the lower inflection point of the P-V curve, and with patients who did not have a lower inflection point we applied a random PEEP level, and the behavior of the gradient was unpredictable and not correlated with changes in oxygenation. The interpretation was that PEEP induced alveolar recruitment, decreased alveolar dead space, and the gradient narrowed, whereas the contrary occurred when PEEP induced overdistension and both alveolar dead space and the gradient increased.

Therefore, variations of the gradient at similar hemodynamic status might help clinicians understand the physiologic effects of PEEP.

Bigatello: I think this brings up the utility of looking at CO₂ elimination as an index of alveolar recruitment, which Gattinoni et al reported on.¹ If we are recruiting the lung and not overdistending, but truly recruiting new units, we should ventilate better so the P_{aCO₂} will decrease.

REFERENCE

1. Gattinoni L, Vaggini F, Carlesso E, Taccone P, Conte V, Chiumello D, et al; Prone-Supine Study Group. Decrease in P_{aCO₂} with prone position is predictive of improved outcome in acute respiratory distress syndrome. *Crit Care Med* 2003; 31(12):2727–2733.