

## In Defense of the Stethoscope

Raymond LH Murphy Jr MD MPH

- Introduction
- Case Presentation
  - Problems With Auscultation
  - Importance of Squawks
  - Arguments That Support the Clinical Use of the Stethoscope
- Respiratory Acoustic Analysis
- Guidelines
- Correlation of Adventitious Sounds and Disease States
  - Types of Sounds
  - Patterns of Distribution of Sounds
  - Computerized Detection and Quantification
- Utility of Auscultation With an Acoustic Stethoscope
- Improvements in Education
- Observer Variability in Medical Tests
- Computerized Analysis
  - Single-Channel Devices
  - Multi-Channel Computerized Analysis
- Summary and Recommendations

The stethoscope is widely considered to be an unreliable instrument. Many studies document the significant observer variability in its use. Numerous other diagnostic tools are available that are generally regarded to provide more reliable diagnostic information. Some even argue that teaching of the ancient art should be de-emphasized in medical schools. Yet auscultation with an acoustic stethoscope can provide important, even life-saving, information. The purpose of this article is to present evidence that supports the use of the stethoscope in clinical medicine. The argument for the stethoscope will be made by presenting relevant investigations, including clinical studies acknowledged to meet the criteria of evidence-based medicine. It will focus on studies that have employed computerized acoustic technology to correlate lung sounds with disease states. This technology has advanced in recent years, which has stimulated a resurgence of interest in auscultation. Numerous studies have been done that utilized objective methods that circumvented the problem of observer variability. There is now a good deal of scientific evidence to support the hypothesis that lung sounds contain information that is clinically useful. This technology also allows this information to be collected more efficiently than previously possible. Advances in educational technology have made it possible to impart information on auscultation much more easily than was possible in the past. Contrary to predictions, the stethoscope is not likely to be relegated to the museum shelf in the near future. Computer technology is making it an even more useful clinical instrument. *Key words:* auscultation, lung sounds, heart sounds, computerized acoustic analysis. [Respir Care 2008;53(3):355–369. © 2008 Daedalus Enterprises]

## Introduction

This article was in part stimulated by 2 recent editorials.<sup>1,2</sup> One reviewed the history of the stethoscope and stated that it is safe to assume that the stethoscope would be someday relegated to a museum shelf. The second discussed the demise of the physical examination and presented much information on problems with auscultation. The author stated that physicians are uncomfortable with uncertainty. They want more objective information than that obtained by physical examination. It was a balanced discussion in that the author also pointed out that even the tests commonly believed to be more accurate have their subjectivity and that physical examination could sometimes provide “the vital clue” to aid in diagnosis. The major thrust of the article, however, was to point out the deficiencies of physical examination and highlight the disdain some physicians have for it. For example, the author described an oncology fellow who, “Even as he went through the motions of teaching physical diagnosis, he appeared to be dismissing it.” The author stated that he, himself, is a bit of an agnostic but dutifully applies his stethoscope to his patients’ chests “often simply out of habit.” The purpose of this article is to present a contrary view by reviewing evidence that supports the use of the stethoscope in clinical medicine.

Though the stethoscope is useful in several clinical areas, including cardiac auscultation and detection of vascular abnormalities, this article will focus on auscultation of the lung, as that is the area of my main experience. To illustrate some of the problems and clinical benefits of auscultation I will begin with a discussion of a patient with a respiratory problem.

## Case Presentation

A 69-year-old white female presented to the emergency department with acute shortness of breath. She had generally been in good health and regularly participated in vigorous physical activity. She had a 20-pack-year history of cigarette smoking but stopped 18 years ago. Several months prior to admission she was seen by her primary

care physician because of a nonproductive cough associated with intermittent dyspnea. Allergy testing was negative. She was started on a bronchodilator for a presumptive diagnosis of new-onset asthma. Review of systems was unremarkable except for complaints consistent with esophageal reflux. She was intolerant of histamine-2 blockers. The night prior to admission she had a large meal together with several alcoholic beverages. She awoke the next morning markedly short of breath and coughing, and presented herself to the emergency department. On physical examination she was noted to be hypoxemic, and had a respiratory rate of 22 breaths/min, temperature of 37.7°C, and pulse of 107 beats/min. The emergency department physician noted mild wheezing and faint inspiratory crackles. The patient’s white-blood-cell count was 13.5 cells/ $\mu$ L. A chest radiograph was interpreted as within normal limits. Three hours after arrival in the emergency room, another physician examined the patient and heard crackles and squawks, but no wheezing. These findings were confirmed by automated lung-sound analysis. What is the importance of the squawks, and how should the patient be treated?

## Problems With Auscultation

This case illustrates several problems with the current state of auscultation. I will comment briefly on the causes of the problems and the developments in technology that are improving the situation. The house officers and emergency physician missed an important clinical finding. When it was called to their attention, they thought it unimportant. Fortunately, the attending physician agreed to add an antibiotic to the regimen and the patient did well. It is not surprising that they did not know about the importance of squawks. A review of many textbooks on physical diagnosis failed to find mention of the association of squawks with pneumonia, even though Laënnec described this phenomenon nearly 200 years ago.<sup>3</sup>

It is also not surprising that they paid little attention to the physical findings. A high percentage of medical professionals have little regard for chest auscultation. Indeed, Forgacs, a distinguished student of lung sounds, wrote that it “had been reduced to a perfunctory ritual.”<sup>4</sup> There are several obvious reasons for these opinions. The reliability of auscultation can be legitimately questioned, because observer variability is high, as has been well documented.<sup>5–7</sup>

Furthermore, there are many tools available for diagnosis and management of patients with cardiopulmonary disorders, such as chest radiographs, computed tomography (CT) scans, and magnetic resonance imaging, and these are widely considered to be more reliable than the stethoscope. Traditionally, auscultation has been taught at the bedside, and skill in the art is obtained through experience. This has been time-consuming. With many pressures on

---

Raymond LH Murphy Jr MD MPH is affiliated with Stethographics, Westborough, Massachusetts, and with Faulkner Hospital, Boston, Massachusetts.

Dr Murphy is the founder, chairman, and chief medical officer of Stethographics, Westborough, Massachusetts, which manufactures devices for lung-sound detection, recording, and analysis. He reports no other conflicts of interest related to the content of this paper.

Correspondence: Raymond LH Murphy Jr MD MPH, Pulmonary Department, Faulkner Hospital, 1153 Centre Street, Suite 40, Boston MA 02130. E-mail: rlmurphy@partners.org.

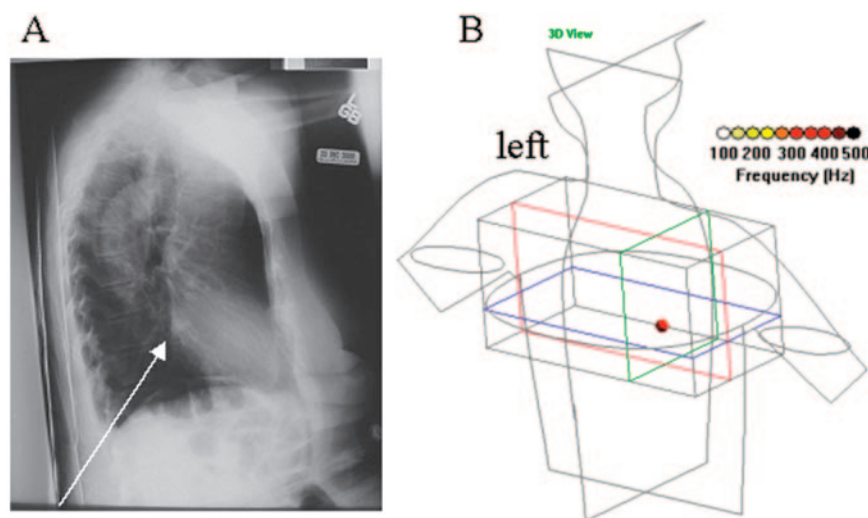


Fig. 1. A: Localization of the opacification on chest radiograph. B: The squawk on the multi-channel lung-sound analyzer.

their time, physicians in training are likely to focus more attention on the other tools for diagnosis. In addition, the problems with auscultation have been compounded by difficulties with nomenclature. This had become so severe that it had been said that “almost every physician had his own terminology.”<sup>8</sup> Fortunately this problem has been greatly reduced by the publication of guidelines, as will be discussed in more detail below.<sup>9,10</sup> More importantly, there has been a resurgence of interest in lung sounds, and numerous studies have been done that have improved our knowledge of this ancient art. This has been stimulated by the development of computerized acoustic technology. Comprehensive reviews of these studies have been presented.<sup>7,11–13</sup> I will present the evidence that shows that there is objective information that supports the concept that auscultation of the chest, when done by a knowledgeable clinician, remains clinically useful and is indeed important. The recommendation to treat this patient with antibiotics was the result of a clinician having knowledge of studies done with computer-assisted auscultation. I will also present other examples where auscultation remains useful.

### Importance of Squawks

Squawks are short, inspiratory, musical sounds that have a rather distinctive sound that is easily recognizable, once learned. Squawks have been described in patients with hypersensitivity pneumonitis and fibrotic lung disorders.<sup>14</sup> They also have been reported to be present in 15% of patients with pneumonia.<sup>15</sup> When squawks are heard and there is no evidence of hypersensitivity or other restrictive disorders and the patient has an acute syndrome consistent with respiratory infection, their presence provides rela-

tively specific, although not sensitive, evidence of pneumonia. The emergency department physician's diagnosis was acute asthma. The patient was treated with bronchodilators and a course of steroids was prescribed. Because the squawks were detected, antibiotic therapy was begun. On rereading the chest radiograph a small (2-cm × 3-cm) opacification was noted at the right base (Fig. 1A). A squawk was detected in the same region (see Fig. 1B). This localization was based on the arrival time of the sounds at the chest microphones.<sup>16</sup> The opacification and the squawk cleared on follow-up examinations. The patient has had no recurrence of episodes of acute shortness of breath with wheezing. A hypersensitivity panel was negative. Her gastroesophageal reflux disease symptoms improved with treatment. It is likely that the patient had aspiration pneumonitis and would have been treated with steroid and no antibiotic had the squawk not been detected.

### Arguments That Support the Clinical Use of the Stethoscope

Early work that showed the utility of auscultation in diagnosis came from the field of occupational medicine. Patients with asbestosis commonly have basilar crackles, as has been described by numerous observers. A study of shipyard pipe-coverers showed that crackles were more common in the pipe-coverers than they were in an age-matched control group of shipyard workers not directly exposed to asbestos. To avoid bias, that study was done with the observer blinded to the workers' exposure histories. The subjects with crackles were more likely to have abnormal chest radiographs and abnormal pulmonary function. Utilizing that information, technicians have been trained in detection of these crackles for surveillance of

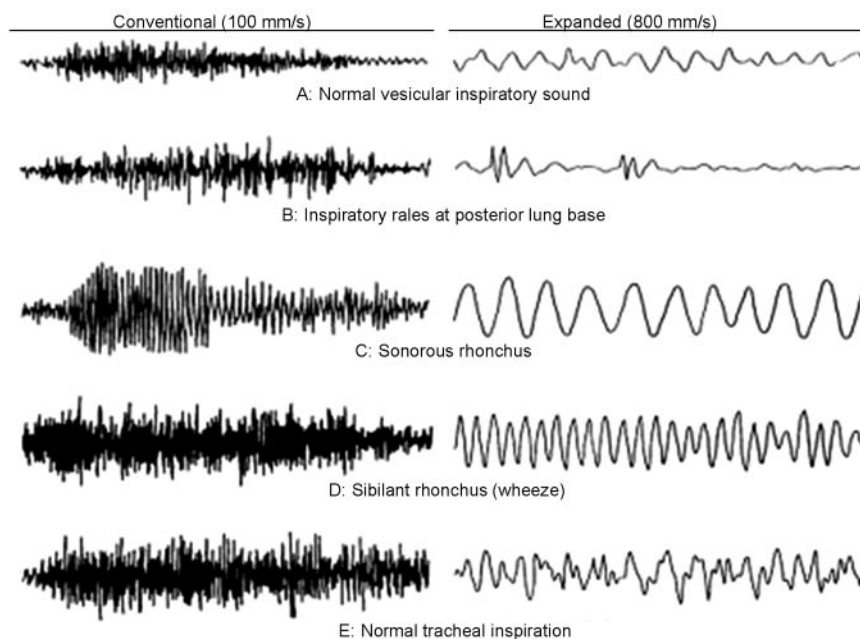


Fig. 2. Time domain plots are illustrated in both the time-unexpanded and time-expanded modes. It is clear that the pattern differences between different types of lung sounds are seen more easily in the expanded mode. (From Reference 23, with permission.)

workers exposed to asbestos.<sup>17</sup> Validation of these observations became clearer after the development of computerized techniques. The detection of crackles via time-expanded waveform analysis has been shown, by British and Finnish investigators, to be as good as CT scans in detecting asbestosis.<sup>18,19</sup>

The accuracy of lung sounds for the identification of disease states in studies cited to follow the rules of evidence-based medicine were also confirmatory.<sup>20–22</sup> Expressed in terms of likelihood ratio, fine end-inspiratory crackles were associated with pulmonary fibrosis with a likelihood ratio of +5.9. Other observations also cited to meet these criteria include: wheezing during quiet breathing predicts asthma (likelihood ratio +6) or chronic bronchitis (likelihood ratio +6). Fine or coarse early inspiratory crackles were associated with chronic bronchitis (likelihood ratio +14 to +20); decreased breath sounds were associated with emphysema (likelihood ratio +10.2). Though the association of fine crackles with pulmonary fibrosis is strong, as noted, fine and coarse crackles were also found in congestive heart failure (likelihood ratio +3.4). This calls attention to the fact that there are dangers that can arise from the misinterpretation of auscultation findings. Patients with interstitial fibrosis are commonly given diuretics inappropriately. Their crackles are mistaken for those of heart failure. Similarly, the cause of wheezing may be misinterpreted. A diagnosis of cardiac asthma may be missed if the wheezing is mistakenly attributed to bronchial rather than cardiac asthma. These observations reaffirm the importance of proper education

in physical diagnosis. It brings to mind the question often posed to medical students: What is the most important part of the stethoscope? The answer, of course, is the part between the ear-pieces.





### Respiratory Acoustic Analysis

In the year 2000 the European Respiratory Society pointed out that over the past “30 years, computerized methods for recording analysis of respiratory sounds have overcome the many limitations of simple auscultation. Respiratory acoustic analysis can now quantify changes in lung sounds, make permanent records of the measurements made, and produce graphical representations that help with the diagnosis and management of patients suffering from chest diseases.”<sup>10</sup>

Indeed, evidence for this was presented in 1977. The patterns of lung sounds in the time-expanded mode were presented, as illustrated in Figure 2.<sup>23</sup> This method involves the spreading out of the x-axis of time-amplitude plots and, as a result, can show the details of crackles, wheezes, and other sounds not readily discernable in the unexpanded mode. It was recognized that “this allowed adventitious sounds to be characterized solely on the basis of their graphic characteristics.”<sup>24</sup>

That observation, combined with advances in signal processing, has been put to good use. Algorithms were developed by studying waveforms such as these to characterize and quantify these sounds. Technology was also developed that enabled collection of data at multiple sites simultaneously,

Table 1. Recommended Terms for Adventitious Sounds

Acoustic Characteristics	Waveform	Recommended ATS* nomenclature	Terms in some textbooks	A British usage	Laënnec's original term	Laënnec's model
Discontinuous, interrupted, explosive sounds Loud, low in pitch:		Coarse crackle	Coarse rale	Crackle	Râle muqueux ou gargouillement	Escape of water from a bottle held with mouth directly downward
Discontinuous, interrupted explosive sounds Less loud than above and of shorter duration; higher in pitch than coarse rales or crackles		Fine crackle	Fine rale crepitation	Crackle	Râle humide ou crepitation	Crepitation of salts in a heated dish. Noise emitted by healthy lung when compressed in the hand
Continuous sounds Longer than 250 ms, high-pitched; dominant frequency of 400 Hz or more, a hissing sound		Wheeze	Sibilant rhonchus	High-pitched wheeze	Râle sibilant sec ou sifflement	Prolonged whisper of various intonations; chirping of birds; sound emitted by suddenly separating 2 portions of smooth oiled stone. The motion of a small valve
Continuous sounds Longer than 250 ms low-pitched; dominant frequency about 200 Hz or less; a snoring sound.		Rhonchus	Sonorous rhonchus	Low-pitched wheeze	Râle sec sonore ou ronflement	Snoring; bass note of a musical instrument; cooing of a wood pigeon

\* American Thoracic Society

While the terms used to name the categories of lung sounds vary widely, the categorization scheme itself has changed little since Laënnec. The most recent names recommended for adoption by the American Thoracic Society and terms used by others are shown here, accompanied by acoustic descriptions and examples of typical sound waveforms for each category. (From Reference 26, with permission.)

which allows presentation of the patterns of distribution of normal and abnormal sounds on the chest.<sup>25</sup> This provides a more organized approach to the study of the correlation of acoustic findings with disease states and calls attention to both the strengths and potential pitfalls of auscultation. In addition, this work led to the development of guidelines to help clear up the previously confused terminology.

### Guidelines

Both the American Thoracic Society (Table 1) and the European Respiratory Society have published guidelines to standardize the nomenclature.<sup>9,10,26</sup> The comprehensive European Respiratory Society guidelines are the result of work done by a task force that represented 7 European countries: Belgium, Britain, Finland, France, Germany, and the Netherlands. Their main objective was to develop guidelines for research and clinical practice in the field of respiratory sound

analysis. They presented specific acoustic variables for normal sounds as well as fine crackles, coarse crackles, wheezes, rhonchi, pleural friction sounds, and squawks. A detailed list of medical and technical terms used in respiratory acoustics was also presented to provide easily accessible definitions for all workers involved in this field. They presented recommendations for respiratory acoustic examinations, including the preferred environmental conditions, patient management procedures, data acquisition techniques, as well as advice on digitization and sound analysis.

### Correlation of Adventitious Sounds and Disease States

The correlation of sounds with disease states can be examined by studying the types of sounds, their patterns of distribution over the chest, and also by studying comput-



erized analysis of the type, quantity, timing, and waveform differences in amplitude of the sounds.

### Types of Sounds

Table 2 summarizes the findings obtained with a multi-channel lung-sound analyzer in a convenience sample of patients with common illnesses who were studied in a community teaching hospital. This device collects data with microphones imbedded in a soft foam mat that is placed on the back and the lateral bases, as has been described.<sup>25</sup> It is illustrated in Figure 3. Fine and coarse crackles, wheezes, rhonchi, and squawks are identified and counted by this device.

Examination of Table 2 calls attention to an important problem with auscultation. There is considerable overlap in the presence of abnormal sounds in common illnesses. As a consequence, correlation of the type of sound with disease states can be difficult. For example, as can be seen in this table, wheezing is more common in asthma than in the other conditions. Fifty-nine percent of the patients with asthma had some wheezing at the time they were studied. However, inspection of the table also shows that wheezing was not uncommon in pneumonia, chronic obstructive pulmonary disease, and congestive heart failure. This brings to mind the adage, perhaps forgotten by the physicians in this case, "All that wheezes is not asthma."

There is also overlap in other sounds. Rhonchi are also seen to be almost equally common in pneumonia, congestive heart failure, chronic obstructive pulmonary disease, and asthma. Crackles are also seen to be present in all these conditions. They occur even in those with no recognized cardiopulmonary disorder, as has been reported.<sup>27,28</sup> Although it can be difficult to separate disease states by the type of their adventitious sounds, there are some exceptions. Expiratory crackles are more common in pneumonia than they are in asthma, chronic obstructive pulmonary disease, or congestive heart failure; when detected in an acutely ill patient with no history of chronic lung disease, the possibility of pneumonia should be considered.

The crackles in patients with interstitial pulmonary fibrosis are fairly distinctive. As can be seen in the table, the highest rates of crackles are seen in this disorder; the inspiratory crackles averaged  $25 \pm 12$  per breath. Recognition of this sound is often the first clue that interstitial pulmonary fibrosis is present.

### Patterns of Distribution of Sounds

The pattern of distribution of sounds over the chest can also be obtained with a multi-channel lung-sound analyzer. Pattern differences are often helpful in separating diseases from each other. Typical patterns in common conditions are illustrated in Figure 4. The pattern seen in a

patient with vocal cord dysfunction is presented in Figure 5. It illustrates the observation that presentation of the simultaneously recorded waveforms in a stack mode provides evidence as to the origin of the sound. In this case the wheeze pattern is seen to appear first at the microphone placed over the trachea.

As noted, the automated analysis of the lung sounds of the patient presented in this article confirmed the observations of one of the clinicians and provided objective evidence that supports the diagnosis of pneumonia. The detection of squawks was particularly helpful (Figure 6). Their waveforms are distinctive, as is illustrated in Figure 7. Information can also be obtained from the way the sound patterns change. The patient whose CT is presented in Figure 8 had interstitial pulmonary fibrosis. On being intubated because of respiratory failure, she was observed to aspirate. On the 4th day of her stay in the intensive care unit she developed a fever and an elevated white-blood-cell count. Her CT was interpreted as showing "diffuse infiltrates, no focal abnormalities." She developed coarse crackles over her left base, where in retrospect an air bronchogram consistent with pneumonia was noted on the CT. There was some increased opacification consistent with pneumonia at her right base as well. Rhonchi were detected over the right lung that were not present on day 1. The rhonchi were probably due to phlegm in the airways, associated with the aspiration. They were probably not due to the interstitial pulmonary fibrosis. As can be seen in Table 2, none of the 19 patients with interstitial pulmonary fibrosis had rhonchi.

### Computerized Detection and Quantification

The type, quantity, and waveform differences in amplitude and timing of the sounds, as well as other features, can be calculated automatically by computer. In one example of this approach, an algorithm for detecting pneumonia separated patients diagnosed with this disease from age-matched controls with a sensitivity of 0.78, a specificity of 0.88, and a positive predictive power of 0.93.<sup>29</sup> In another example, multi-channel lung-sound analysis was shown to offer promise of help in separating the crackles of interstitial pulmonary fibrosis from those of congestive heart failure. The transmission of individual crackles over the chest can be tracked by a computer and differs in the 2 disease states.<sup>30</sup>

### Utility of Auscultation With an Acoustic Stethoscope

Such objective measurements demonstrate that, despite the difficulties with auscultation mentioned above, pattern differences exist that can help in diagnosis of cardiopulmonary disorders. This provides support for the concept that useful information is obtainable via auscultation, when

Table 2. Summary of the Results of Multichannel Lung-Sound Analysis in 700 Patients

Type of Lung Sound	Normals (n = 334)	Pneumonia (n = 122)	Congestive Heart Failure (n = 80)	Asthma (n = 51)	COPD (n = 94)	Interstitial Pulmonary Fibrosis (n = 19)
<u>Wheezes</u>						
Inspiration						
Average wheeze rate (%)	0 ± 4	3 ± 13	3 ± 13	10 ± 16	2 ± 8	0
Percent of patients who wheeze for > 4% of the inspiration	2	12	10	37	17	0
Among these patients, average wheeze rate (%)	18 ± 20	27 ± 24	30 ± 29	25 ± 17	20 ± 16	0
Among these patients, average wheeze frequency (Hz)	300 ± 136	248 ± 61	320 ± 129	340 ± 142	232 ± 58	0
Expiration						
Average wheeze rate (%)	1 ± 5	7 ± 16	6 ± 16	25 ± 32	12 ± 23	0
Percent of patients who wheeze for > 4% of the inspiration	2	21	14	47	31	5
Among these patients, average wheeze rate (%)	22 ± 29	30 ± 22	32 ± 31	53 ± 27	37 ± 27	2 ± 4
Among these patients, average wheeze frequency (Hz)	309 ± 122	304 ± 89	297 ± 83	259 ± 67	301 ± 119	346 ± 124
Percent of patients who have either or both	4	29	16	59	39	5
<u>Rhonchi</u>						
Inspiration						
Average rhonchi rate (%)	0 ± 1	5 ± 13	3 ± 12	5 ± 15	3 ± 11	0
Percent of patients with rhonchi for > 4% of the inspiration	2	16	8	16	15	0
Among these patients, average rhonchi rate (%)	17 ± 25	28 ± 20	36 ± 20	31 ± 25	22 ± 21	0
Among these patients, average rhonchi frequency (Hz)	129 ± 36	140 ± 46	117 ± 29	142 ± 34	129 ± 29	0
Expiration						
Average rhonchi rate (%)	0 ± 3	6 ± 16	4 ± 12	7 ± 20	7 ± 19	0
Percent of patients with rhonchi for > 4% of the expiration	3	17	18	16	18	0
Among these patients, average rhonchi rate (%)	13 ± 11	33 ± 24	24 ± 19	44 ± 28	38 ± 28	0
Among these patients, average rhonchi frequency (Hz)	107 ± 42	126 ± 29	111 ± 45	142 ± 37	132 ± 30	0
Percent of patients who have either or both	4	29	20	27	26	0
<u>Crackles</u>						
Inspiration						
Average crackle/breath	1 ± 2	7 ± 5	6 ± 5	3 ± 3	5 ± 6	25 ± 12
Percent of patients with over 2 crackles/breath	16	81	73	56	65	100
Among these patients, average crackle/breath	4 ± 2	8 ± 5	7 ± 5	4 ± 2	7 ± 6	25 ± 12
Among these patients, average crackle frequency (Hz)	371 ± 88	302 ± 60	310 ± 63	329 ± 63	311 ± 61	448 ± 58
Expiration						
Average crackles/breath	1 ± 1	5 ± 5	2 ± 3	3 ± 3	2 ± 3	9 ± 9
Percent of patients with > 2 crackles/breath	8	63	31	39	37	84
Among these patients, average crackles/breath	4 ± 2	5 ± 3	5 ± 3	5 ± 4	5 ± 3	10 ± 9
Among these patients, average crackle frequency (Hz)	337 ± 106	285 ± 65	285 ± 65	284 ± 55	309 ± 98	405 ± 77
Percent of patients who have either or both	21	87	76	65	71	100

COPD = chronic obstructive pulmonary disease

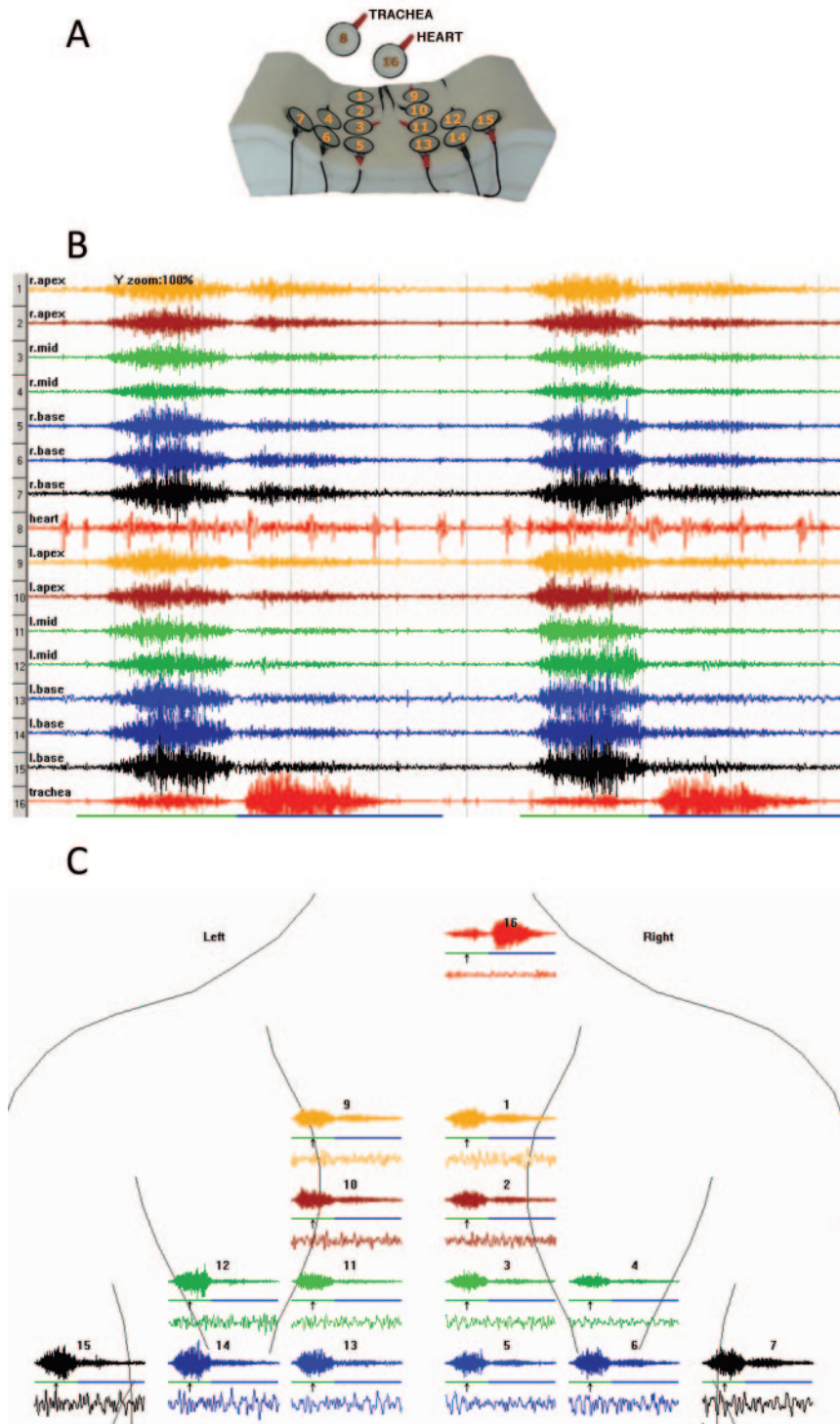


Fig. 3. A: The arrangement of the microphones in the back-pad arrayed over the posterior chest and lateral bases. Twelve microphones are placed on the back; numbers 1 through 6 are on the right side, 9 through 14 are on the left. There is one on each lateral base: microphone numbers 7 and 15 respectively. One microphone is over the trachea: number 16. B: Time amplitude plots of lung sounds are displayed as they appear on the computer screen. The arrangement is that of a stacked mode. In this example, 2 breaths are shown. C: The plot of a single breath selected from the stacked-mode plot and presented in an array more consistent with the anatomical orientation of the microphones. Waveforms are presented in both the unexpanded (top) and expanded (bottom) modes. The unexpanded waveform shows one full breath. The unexpanded and expanded waves that correspond to the same channel are shown in the same color. The choice of colors is arbitrary. The solid bars under the unexpanded waves mark the respiratory cycle: green bars indicate inspiration, and blue bars indicate expiration. The arrow indicates the location of the expanded interval. The duration of the expanded interval is 100 milliseconds.



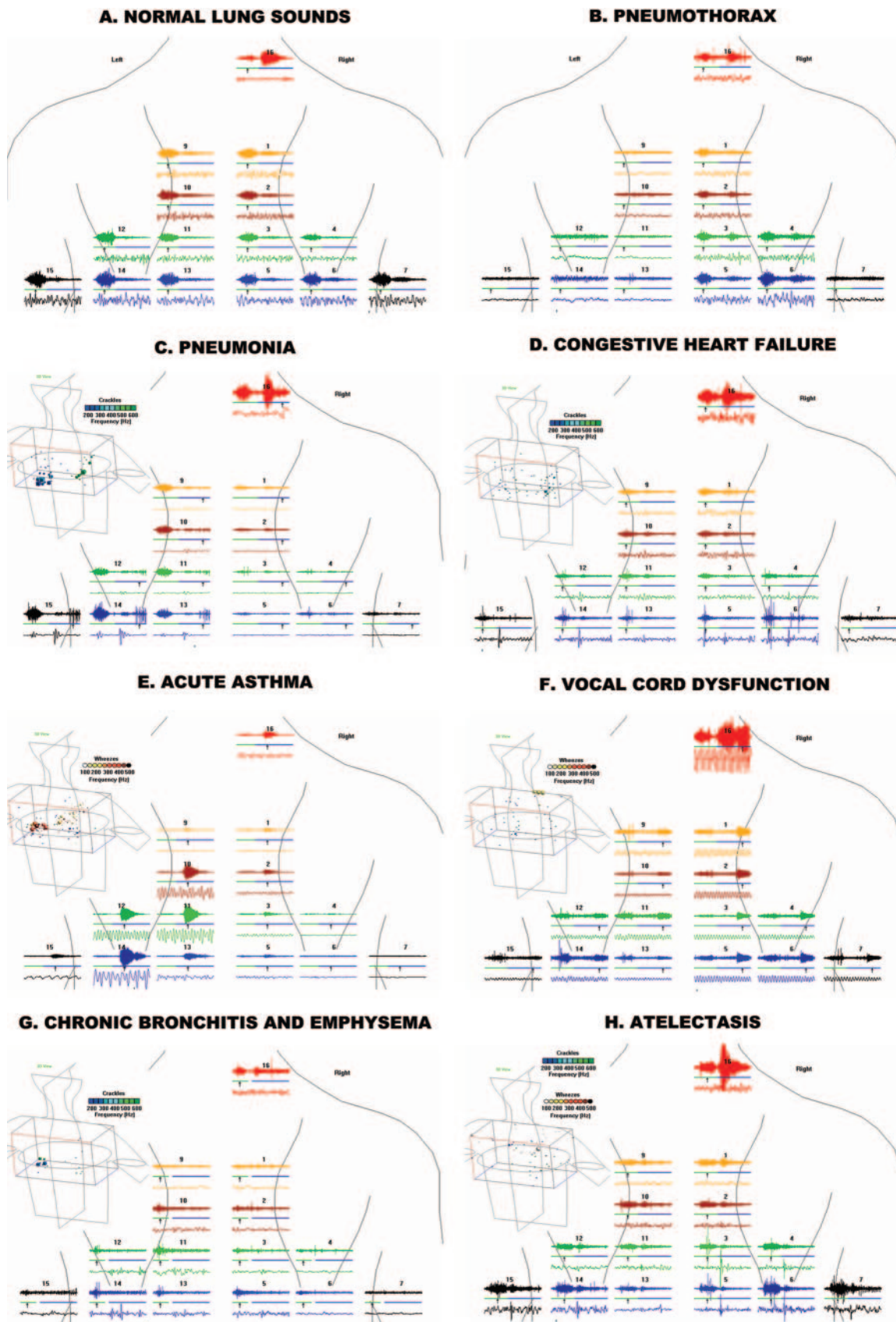


Fig. 4. Waveforms in common cardiopulmonary conditions. A: Normal. In this subject there is no lung disease. There are no wheezes and no crackles. The time amplitude pattern seen over the chest is relatively uniform from site to site. The expiratory phase has its highest amplitude over the trachea and has relatively low amplitude at sites distant from large airways. The amplitude is of intermediate value at sites close to large airways (bronchovesicular). B: This waveform pattern was seen in a 26-year-old male who presented with chest pain. The amplitudes of the sounds on the left side were markedly decreased. This led to a diagnosis of spontaneous pneumothorax, prior to its confirmation via chest radiograph. C: In this patient with pneumonia, crackles are concentrated at the left base, where opacification was detected on radiograph. Both inspiratory and expiratory crackles are present. The insert shows 3-dimensional localization of abnormal lung sounds. The cubes indicate crackles. The spheres indicate wheezes and rhonchi. The color indicates the frequency of the sound. The size of the markers is proportional to the crackle and wheeze rate. D: In this patient with congestive heart failure, inspiratory crackles are present at both bases. E: In this patient with acute bronchial asthma, substantial expiratory wheezing is present. F: In this patient with vocal cord dysfunction, diffuse expiratory wheezing is also present. The intensity over the trachea is higher than that over the chest sites. G: The pattern of the distribution of the sounds in a typical patient with chronic obstructive pulmonary disease shows that the amplitude tends to be markedly decreased, but the degree of this decrease varies from site to site. The expiratory phase is relatively prolonged. H: Bibasilar fine crackles as they appeared in this healthy male undergoing spinal anesthesia. They were not present preoperatively and cleared promptly after the patient took several deep breaths.

done by a knowledgeable clinician. It also helps explain the apparent paradox of an unreliable instrument that continues to be widely used.

Auscultation, particularly when combined with medical history and the other modalities of physical diagnosis, can guide steps taken in patient management before any of the advanced technologies are employed. Examples are as follows.

Collapse of one lung can be detected by the absence or marked decrease of lung sounds on one side. Treatment for this condition is usually done immediately, particularly in the severely ill, based on auscultation findings, and can be life-saving.

Stridor can be heard when foreign bodies are in large airways. This is a potentially life-threatening situation, and action can be taken to remove the offending material once this sound is recognized (eg, a Heimlich maneuver can be performed to treat the “cocktail coronary”). Diffuse wheezing points toward a diagnosis of acute bronchial asthma, and in a patient with a known history of asthma bronchodilators are often administered before other testing is done.

Fluid can be withdrawn from the pleural space reliably, based on physical findings. The presence of numerous crackles on auscultation in a patient presenting with lung congestion secondary to heart failure is used to guide the administration of medications to reduce the fluid prior to more definitive testing.

The stethoscope is not likely to be relegated to the museum shelf in the near future. On the contrary, its usefulness will be increased by application of recent technological advances, including the tools to facilitate instruction in its use.

### Improvements in Education

As I point out, taking advantage of the important information that can be provided by auscultation requires a knowledgeable clinician. Fortunately, it is now easier for clinicians to become knowledgeable. The teaching of aus-

cultation has been improved because of the availability of audio recordings and advanced multimedia educational materials. It has been shown that the availability of visual as well as auditory presentations of sound has improved the learning process.<sup>31</sup> This takes advantage of the fact that many people are predominantly visual rather than predominantly auditory learners. In addition the information imparted is now more accurate because it is based on acoustic analysis, agreed-upon criteria, and correlation studies of acoustic and clinical findings. The teaching of auscultation has also improved with other advances in technology. An interesting example is the use of video analysis to monitor caregivers' performance. In a case report that used this technology it was documented that the failure to use auscultation with a stethoscope was a likely contributor to the prolonging of an uncorrected misplaced endotracheal tube.<sup>32</sup> By giving direct feedback, the video aided in the education process.

The clinical benefit of acoustic pattern studies is illustrated in the case study of the patient with aspiration pneumonia. The reason that one clinician was able to detect and properly interpret the squawk in the patient presented above is that he had studied the waveforms of many patients with pneumonia, as well as other illnesses. He was thus able to “rediscover” an observation made by Laënnec.

### Observer Variability in Medical Tests

It was recently pointed out that one of the reasons for the demise of the physical examination is that physicians want more precise tools.<sup>2</sup> Although the problems with observer variability in detection of lung sounds are widely recognized, it is less widely recognized that there is substantial observer variability in clinical data collection in general, including the interpretation of chest radiographs.<sup>33,34</sup> This was also illustrated in this case. Several experienced observers missed the small patch of retrocardiac opacification.

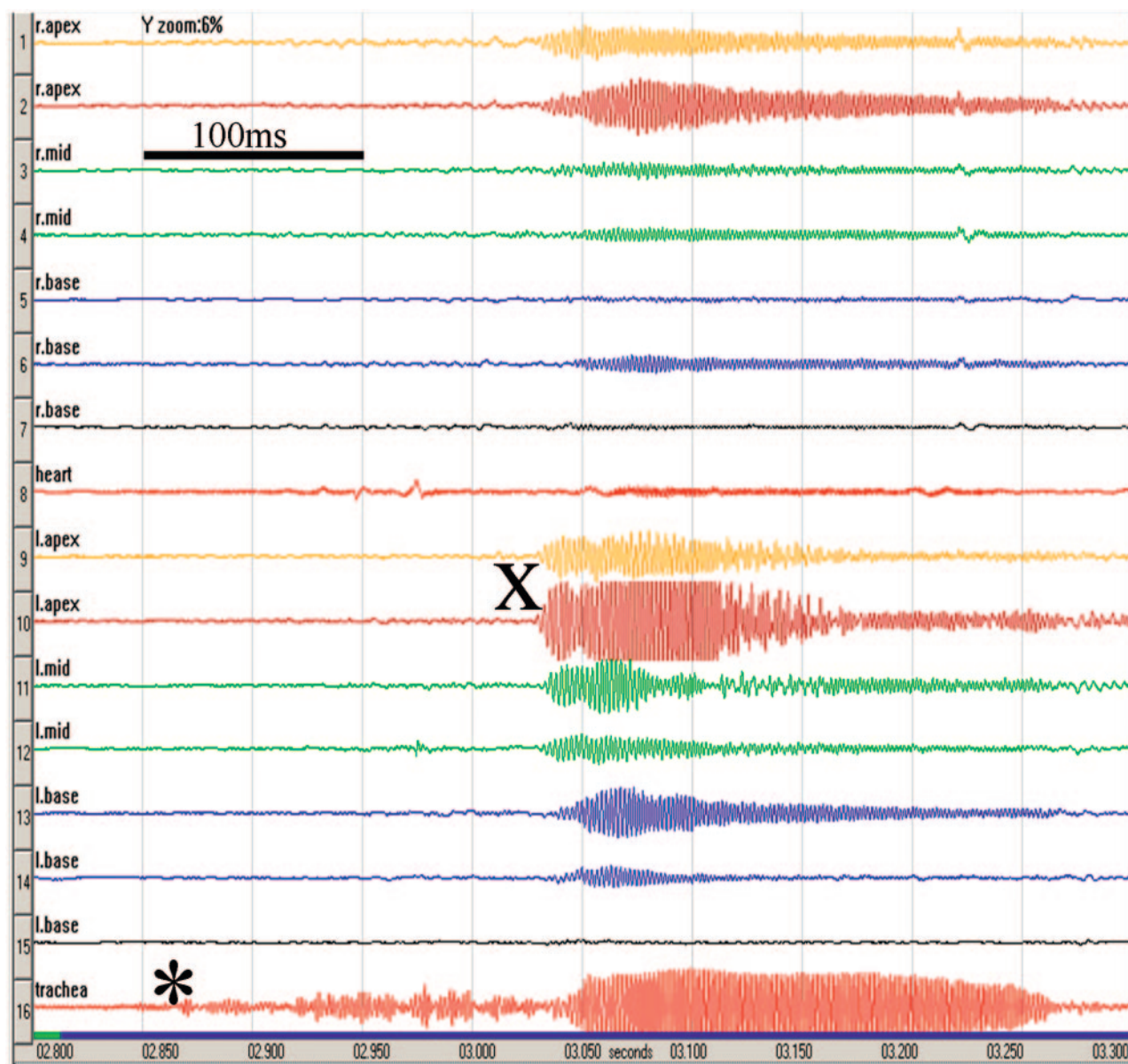


Fig. 5. Expiratory sounds of the patient with vocal cord dysfunction viewed in the stack mode. It is apparent that the waveform of the wheeze appears at the tracheal microphone before it is detectable anywhere on the chest. The beginning of the wheeze at the trachea is marked by (\*). The first channel on the chest that detects wheeze waveform is channel 10 that is positioned on the back over left apex. The beginning of wheeze on channel 10 is marked by (X). The interval between beginning of the wheeze at the trachea and beginning of the wheeze on channel 10 is 180 ms.

There is also observer variability in the interpretation of CT scans. In a study of lung tumor size, the authors concluded that measurements of tumor size on CT scans are often inconsistent and can lead to an incorrect interpretation of tumor response.<sup>35</sup> In a study of CT scans for the diagnosis of pulmonary tuberculosis in children, kappa statistics showed that observers only agreed moderately in their detection of the lymphadenopathy they believed to be critical in making the diagnosis.<sup>36</sup> The CT scan may not always provide clear, easily interpreted information, as is illustrated in the patient pre-

sented in Figure 8. The lung sound and CT findings are shown from a patient with interstitial pulmonary fibrosis, who had a clinical diagnosis of aspiration pneumonia and whose CT had been read as “diffusely abnormal, no evidence of focal infiltrates.” On review of the CT an air bronchogram was noted in the same region where coarse crackles, not present on the examination done on the day of admission, were detected.

Chest sounds can now be quantified objectively, which reduces the inaccuracies prevalent in the past. This can be done both by single-channel and multi-channel devices.



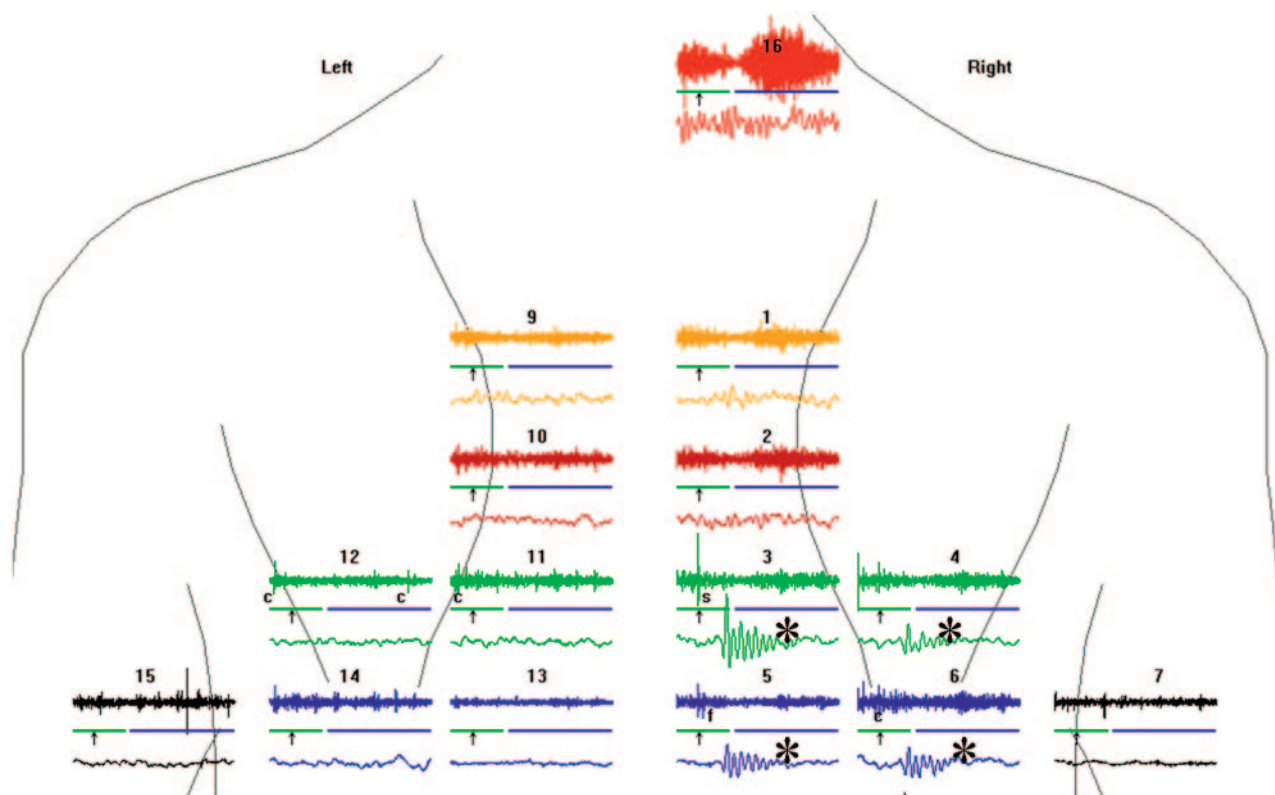


Fig. 6. The waveform of the patient presented in this article shows squawks (\*).

### Computerized Analysis

#### Single-Channel Devices

Though initially computerized acoustic analysis was a phenomenon confined to the laboratory, waveform displays and computer analysis of heart and lung sounds can now be done at the bedside with small, handheld computers such as personal digital assistants. These devices are readily available and are Food and Drug Administration approved. Data can be collected from the patient and transferred readily to a laptop or desktop computer for analysis, archiving, and documentation of findings. The collection of data in an objective and standardized way has the advantage of facilitating the transfer of information from clinician to clinician. This has particular relevance in hospital situations, where numerous practitioners are sequentially involved in the care of the same patient. Availability of immediate feedback in the form of waveforms and computer analysis has the potential of improving the performance of practitioners at all levels. Educational materials are available on personal digital assistants that can avoid the necessity of memorization of details of both heart and lung sounds that clinicians have so often been shown to forget.

An important application of these advances that has the potential of also saving money is in the detection and

interpretation of innocent murmurs. Primary care providers evaluate these murmurs, and 7% of children examined are referred to cardiac specialists (cardiologists or directly to an echocardiography laboratory). The majority of these referrals to cardiologists are unnecessary. In one study 61% of the murmurs referred for subspecialist evaluation were found to be functional or innocent murmurs.<sup>37</sup> Considerable resources are expended on this problem. For example, of 600 new patients assessed in a pediatric cardiology out-patient clinic in the course of one year, over 25% (almost 200) new patients were seen because of innocent murmurs.<sup>38</sup> It is likely that the advances mentioned above could have an important impact on this problem.

#### Multi-Channel Computerized Analysis

Although their use at this time is largely confined to researchers, multi-channel devices are also available and are also Food and Drug Administration approved. They have particular relevance because the sounds can be detected at many sites over the chest, which provides clues to the underlying pathophysiology. Since many sites can be examined, there is potentially more 3-dimensional information than is obtainable via chest radiograph. The chest radiograph is a summation shadowgram (ie, 3-dimensional information is presented in 2 dimensions). Depending on

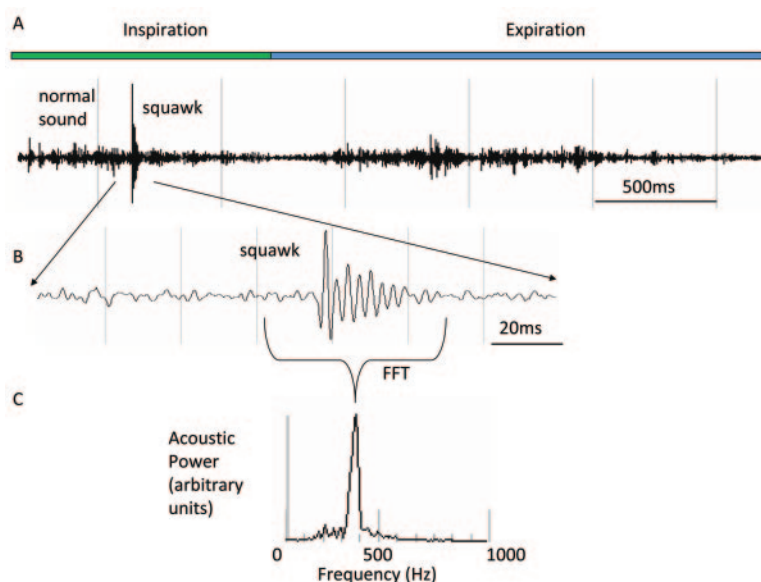


Fig. 7. A: Unexpanded time amplitude plot of a breath containing a squawk. It is present at mid-inspiration. B: The expanded squawk waveform exhibits monophonic sinusoidal fluctuations that last approximately 30 milliseconds. C: The squawk sound in the frequency domain shows a single peak at 350 Hz.

the size of the patient, as many as 60 different sites on the chest can be examined with a stethoscope. Of course, in modern practice, particularly in the industrialized world, practitioners are not likely to spend the requisite time to listen to many sites on the chest. Even if they did, the problems with memory and transcription are not inconsiderable. Computerized analysis can be valuable in this regard. This was pointed out in an editorial entitled "Is the Stethoscope on the Verge of Becoming Obsolete,"<sup>39</sup> which accompanied the article on the diagnosis of pneumonia mentioned above.<sup>29</sup> The author called attention to the efficiencies of computerized auscultation as compared to a well-executed lung examination with an acoustic stethoscope, and pointed out that the latter could take up to 10 min. He noted that:

... the system collected data from each patient in about 2 min at 14 chest wall sites. Conventional auscultation, which requires moving the stethoscope from site to site, would require 28 min to acquire the same amount of data. Unless the clinician were to take notes immediately after listening to each site; he or she would probably not be able to remember all the acoustical details in that long procedure.<sup>39</sup>

Currently, these examinations are relatively easily done with existing methods. It is likely that as new technology is developed the acquisition of acoustic data will be even simpler. The addition of more sites will improve accuracy. I believe that this will improve noninvasive diagnosis.

This can have particular relevance in the intensive care setting, where lateral views are unavailable and technical difficulties are commonly encountered with the anteroposterior views. Another area where this technology has the potential of playing an important role is in situations where radiation is undesirable, such as the case of pregnant women and children. It also has the advantage of not requiring transportation of the patient. The CT scan of the patient presented in Figure 8 required that the patient, who was being ventilated, be moved to the radiology department, and thus involved some risk. The lung sound examinations were done at the bedside. With the appropriate sensors, lung sound monitoring could be done continuously. The existing multi-channel devices require the use of a cart to transport them to the bedside. This inconvenience can be avoided. Examining tables that have computers nearby require only that the software be installed and that the mat of microphones be nearby (eg, hanging on the wall next to the bed). As computers are becoming more commonly present at the bedside, this will be easy to implement in the future.

The use of multi-channel lung-sound analysis is in its infancy. I summarize here the results of only 700 patients (see Table 2). Other investigators are now working with similar devices and in different settings. One group has shown that computerized acoustic assessment of crackles and wheezes is feasible in infants.<sup>40</sup> Another group has reported findings of particular interest to respiratory therapists. They presented evidence that multi-channel lung-sound analysis was useful in showing that the lower lung



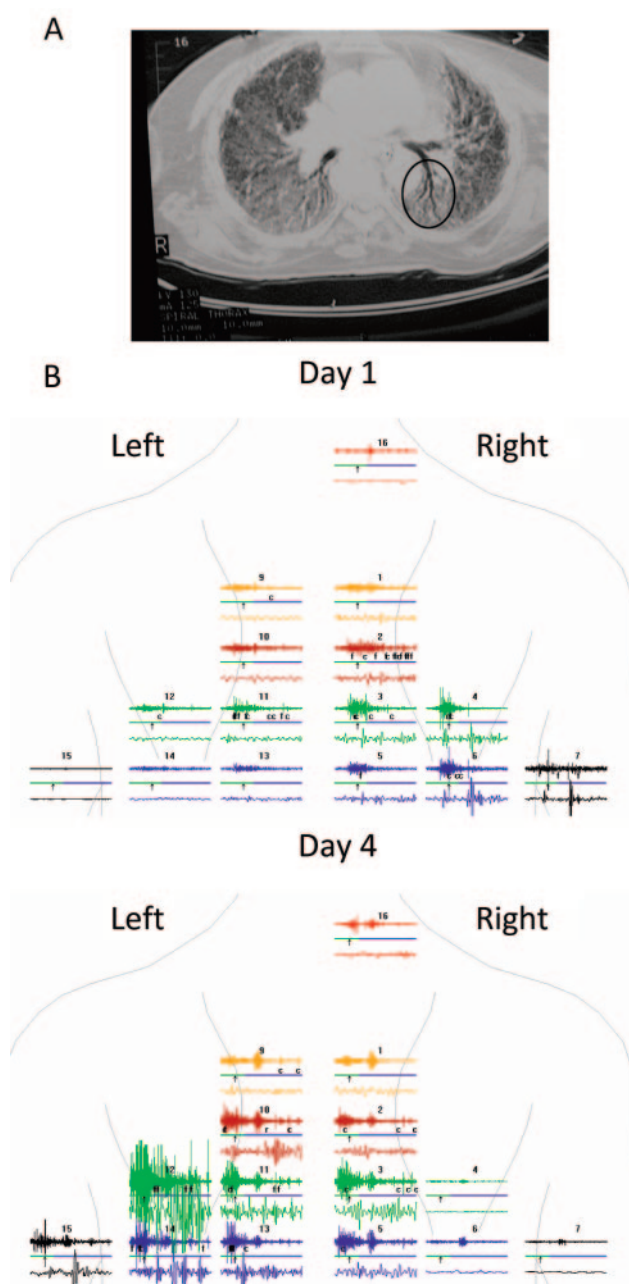


Fig. 8. Computed tomogram and lung-sound plots of a patient with diffuse interstitial pulmonary fibrosis and aspiration pneumonia.

regions were better ventilated with pressure support rather than volume control when tidal volumes were held constant.<sup>41</sup> Another group is investigating the clinical utility of a  $5 \times 5$  array of microphones and a complex neural network analysis scheme.<sup>42</sup> The fact that many other investigators are now engaged in this type of work will help delineate the role of this technology in patient care. Multi-channel devices will probably not be stand-alone diagnostic tools, but will add to the diagnostic armamentarium of

the clinician. As I noted, the same types of adventitious sounds commonly occur in different diseases, and thus the sounds are often not specific for a given disease. Computerized acoustic analysis has provided tools that promise more precise separation of these patterns. The degree to which this will be useful is unknown at this time, but the future appears to be promising. This is particularly true now that other innovative technologies are being introduced. One such technique is that of acoustic reflectometry.<sup>43</sup> This is also of particular interest to therapists and others involved in respiratory care, because it has been shown to be potentially useful in the immediate detection of misplaced endotracheal tubes. No doubt there will be many more innovations.

### Summary and Recommendations

Auscultation with an acoustic stethoscope can provide important, even life-saving information. However, there is no question that considerable observer variability exists in the use of the stethoscope and that this has led to widespread distrust of acoustic findings. The situation is changing. Stimulated by advances in computer science, there has been a resurgence of interest in chest sounds. Studies of the correlation of these sounds with disease states have reaffirmed that the sounds contain objective information of clinical value. Advances in educational technology have made it possible to impart information on auscultation much more easily than was possible in the past. Thus, auscultation with an acoustic stethoscope can be made more reliable. Accordingly, I highly recommend that practitioners be well-trained in auscultation.

An important development is that computerized devices, approved by the Food and Drug Administration, are now available that provide objective acoustic data at the bedside. These include both single-channel devices that communicate with handheld computers and multi-channel devices that facilitate the showing of the patterns of distribution of sound over the chest, and are helpful in diagnosis and management of cardiopulmonary illnesses. There is a trend toward increased use of computers at the bedside. The addition of acoustic technology and the appropriate software is a natural extension of this trend. An exciting aspect of this phenomenon is that computer technology continues to advance. When the time-expanded waveform analysis reported above was first done, 2 computers, each the size of a telephone booth, were used. They were capable of processing only 6 breaths per hour. Now this processing can be done virtually in real time by handheld computers. The stethoscope is going to its wedding, not its grave.<sup>44</sup>

## REFERENCES

- Markel H. The stethoscope and the art of listening. *N Engl J Med* 2006;354(6):551–553.
- Jauhar S. The demise of the physical exam. *N Engl J Med* 2006;354(6):548–551.
- Laënnec RTH. A treatise on the diseases of the chest and mediate auscultation. Translated from the French by John Forbes. New York: Samuel Wood and Sons, 1935.
- Forgacs P. Lung sounds. *Brit J Dis Chest* 1969;63(1):1–12.
- Mangione S, Neiman LZ. Cardiac auscultatory skills of internal medicine and family practice trainees: a comparison of diagnostic proficiency. *JAMA* 1997;278(9):717–722.
- Mangione S, Nieman LZ. Pulmonary auscultatory skills during training in internal medicine and family practice. *Am J Respir Crit Care Med* 1999;159(4 Pt 1):1119–1124.
- Loudon R, Murphy R. Lung sounds. *Am Rev Respir Dis* 1984;130(4):663–673.
- Fraser R, Pare P. Diagnosis of diseases of the chest. Philadelphia: WB Saunders, 1970.
- ACCP-ATS joint committee on pulmonary nomenclature. Diagnosis, definition and classification in chronic generalized respiratory disorder. A proposal to come to a manageable clinical classification system in the human being. An answer to the stimulating report of the ACCP-ATS joint committee on pulmonary nomenclature. *Respiration* 1977;34(5):250–255.
- Sovijarvi A, Vanderschoot J, Earis J. Computerized respiratory sound analysis (CORSAs) recommended standards for terms and techniques. *Eur Respir Rev* 2000;10(77):585–649.
- Gavriely N. Breath sounds methodology. Boca Raton: CRC Press, 1995.
- Pasterkamp H, Kraman S, Wodicka G. Respiratory sounds: advances beyond the stethoscope. *Am J Respir Crit Care Med* 1997;156(3 Pt 1):974–987.
- Earis J, Cheetham B. Current methods used for computerized respiratory sound analysis. *Eur Respir Rev* 2000;10(77):586–590.
- Earis J, Marsh K, Pearson M. The inspiratory “squawk” in extrinsic allergic alveolitis and other pulmonary fibroses. *Thorax* 1979;37:923–926.
- Paciej R, Vyshedskiy A, Bana D, Murphy R. Squawks in pneumonia. *Thorax* 2004;59(2):177–179.
- Murphy RLH. Localization of chest sounds with 3D display and lung sound mapping. US patent 5,844,997, 12/1/1998.
- Murphy RL, Gaensler EA, Holford SK, Del Bono EA, Epler G. Crackles in the early detection of asbestosis. *Am Rev Respir Dis* 1984;129(3):375–379.
- Al Jarad N, Strickland B, Bothamley G, Lock S, Logan-Sinclair R, Rudd RM. Diagnosis of asbestosis by a time expanded wave form analysis, auscultation and high resolution computed tomography: a comparative study. *Thorax* 1993;48(4):347–53.
- Ross RM. The clinical diagnosis of asbestosis in this century requires more than a chest radiograph. *Chest* 2003;124(3):1120–1128.
- Delaunoy M. Lung auscultation: back to basic medicine. *Swiss Med Wkly* 2005;135:511–2.
- McGee S. Evidence based physical diagnosis. Philadelphia: Saunders, 2001.
- Mangione S. Physical diagnosis secrets. Hanley & Belfus, 2000.
- Murphy RL, Holford SK, Knowler WC. Visual lung sound characterization by time-expanded waveform analysis. *N Engl J Med* 1977;296(17):968–971.
- Cugell DW. Sounds of the lungs. *Chest* 1978;73(3):311–312.
- Murphy R. Computerized multichannel lung sound analysis: development of acoustic instruments for diagnosis and management of medical conditions. *IEEE Eng Med Biol Mag* 2007;26(1):16–19.
- Murphy RL. Auscultation of the lung: past lessons, future possibilities. *Thorax*. 1981;36(2):99–107.
- Thacker RE, Kraman RS. The prevalence of auscultatory crackles in subjects without lung disease. *Chest* 1982;81(6):672–674.
- Workum P, Holford SK, Del Bono EA, Murphy RLH. The prevalence and character of crackles (rales) in young women without significant lung disease. *Am Rev Respir Dis* 1982;126(5):921–923.
- Murphy RL, Vyshedskiy A, Power-Charnitsky VA, Bana DS, Marinelli PM, Wong-Tse A, Paciej R. Automated lung sound analysis in patients with pneumonia. *Respir Care* 2004;49(12):1490–1497.
- Vyshedskiy A, Bezares F, Paciej R, Ebril M, Shane J, Murphy R. Transmission of crackles in patients with pulmonary fibrosis, congestive heart failure and pneumonia. *Chest* 2005;128(3):1468–1474.
- Sestini P, Renzoni F, Rossi M, Beltrami V, Vagliasindi M. Multimedia presentation of lung sounds as a learning aid for medical students. *Eur Respir J* 1995;8(5):783–788.
- Mackenzie CF, Martin P, Xiao Y. Video analysis of prolonged uncorrected esophageal intubation. Level One Trauma Anesthesia Simulation Group. *Anesthesiology* 84(6):1494–1503.
- Koran LM. The reliability of clinical methods, data and judgment (second of two parts). *N Engl J Med* 1975;293(13):642–701.
- Cochrane AL, Garland LH. Observer error in the interpretation of chest films; an international investigation. *Lancet* 1952;2(11):505–509.
- Erasmus JJ, Gladish GW, Broemeling L, Sabloff BS, Truong MT, Herbst RS, Munden RF. Interobserver and intraobserver variability in measurement of non-small-cell carcinoma lung lesions: implications for assessment of tumor response. *J Clin Oncol* 2003;21(13):2574–2582.
- Andronikou S, Brauer B, Galpin J, Brachmeyer S, Lucas S, Joseph E, et al. Interobserver variability in the detection of mediastinal and hilar lymph nodes on CT in children with suspected pulmonary tuberculosis. *Pediatr Radiol* 2005;35(4):425–428.
- McConnell M, Adkins S, Hannon D. Heart murmurs in pediatric patients: when do you refer? *Am Fam Physician* 1999;60(2):558–564.
- Dyck JD, Robertson MA. The innocence of innocent heart murmurs. *Perspect Cardiol* 2003;9(9):38–46.
- Wilkins RL. Is the stethoscope on the verge of becoming obsolete? *Respir Care* 2004;49(12):1488–1489.
- Beck R, Elias N, Shoval S, Tov N, Talmon G, Godfrey S, Bentur L. Computerized acoustic assessment of treatment efficacy of nebulized epinephrine and albuterol in RSV bronchiolitis. *BMC Pediatr* 2007;7:22.
- Dellinger RP, Jean S, Cinel I, Tay C, Rajanala S, Glickman YA, Parrillo JE. Regional distribution of acoustic-based lung vibration as a function of mechanical ventilation mode. *Critical Care* 2007;11(1):R26.
- Charleston-Villalobos S, Cortés-Rubiano S, González-Camarena R, Chi-Lem G, Aljama-Corralles T. Respiratory acoustic thoracic imaging (RATHI): assessing deterministic interpolation techniques. *Med Biol Eng Comput* 2004;42(5):618–626.
- Raphael DT. Acoustic reflectometry profiles of endotracheal and esophageal intubation. *Anesthesiology* 2000;92(5):1293–1299.
- Murphy R. The stethoscope-obsolescence or marriage? *Respir Care* 2005;50(5):660–661.