

## An Unusual Cause of a Difficult Extubation

We report an unusual cause of difficult tracheal extubation due to occlusion of the endotracheal tube (ETT) pilot balloon tubing by a bite block.

A 73-year-old man recently underwent coronary artery bypass graft and mitral valve repair at our institution. Fourteen days after discharge, he presented to his local emergency room with epigastric pain, and a Stanford type A aortic dissection extending from just distal to the aortic valve to the iliac arteries was found. He underwent emergency aortic valve resuspension and replacement of the ascending aorta with a dacron tubular graft, which was complicated by substantial bleeding and required massive fluid resuscitation.

Approximately 36 hours after arriving in the intensive care unit, the intensive care unit staff reported difficulty in removing the ETT. The original 9.0-mm cuffed ETT (Hudson Respiratory Care, Temecula, California) was in place and a Bite Proof Bite Block (B&B Medical Technologies, Orangevale, California) had been positioned around the ETT to prevent occlusion by the patient's teeth. Fiberoptic examination through the ETT showed no apparent abnormalities. Only 2 mL of air could be withdrawn from the pilot balloon, which resulted in no leak around the ETT. We considered that, given the patient's massive fluid resuscitation, there might have been substantial tracheal edema trapping the ETT against the tracheal wall. However, on examination, the patient only had trace peripheral edema and had been aggressively diuresed. The ETT was then removed with a moderate amount of force. Upon removal, the ETT

cuff was found to be fully inflated and the ETT balloon tubing was wrapped and kinked inside the bite block apparatus (Fig. 1). The patient's airway remained patent and there was no apparent laryngeal damage.

Though reports of difficult endotracheal intubation are common, a substantial portion of adverse respiratory events have been attributed to complications with tracheal extubation.<sup>1</sup> Three etiologies may be responsible for a difficult extubation, including failure to deflate the ETT balloon, a large ETT balloon caught on the vocal cords, or adhesion of the ETT to the tracheal wall due to insufficient lubricant.<sup>2,3</sup> The majority of difficult extubations are attributed to failure to deflate the ETT balloon.<sup>3</sup> This case illustrates a unique complication during extubation. Readers are encouraged to verify that the ETT balloon tubing and inflation port are free of any additional equipment to allow full deflation and prevent complications with extubation. Commercially designed bite blocks may be of substantial importance in this regard.

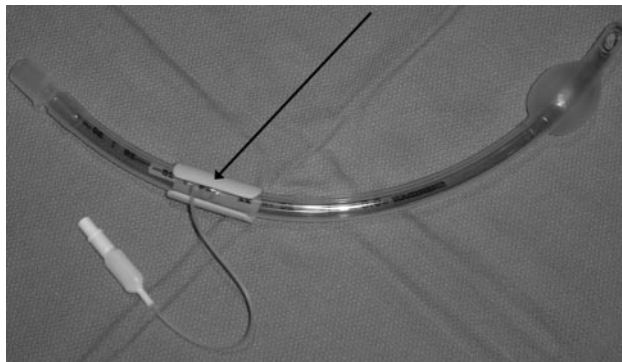


Fig. 1. Endotracheal tube with balloon inflated and bite block in a position that occludes the balloon tubing (arrow). The bite block adhesive is removed.

**Stephen J Gleich**  
Medical Student  
Mayo Clinic College of Medicine  
Rochester, Minnesota

**William J Mauermann MD**  
**Norman E Torres MD**  
Division of Cardiovascular  
Anesthesiology  
Department of Anesthesia  
Mayo Clinic College of Medicine  
Rochester, Minnesota

The authors report no conflicts of interest in the content of this letter.

## REFERENCES

1. Caplan RA, Posner KL, Ward RJ, Cheney FW. Adverse respiratory events in anesthesia: a closed claims analysis. *Anesthesiology* 1990;72(5):828–833.
2. Blanc VF, Tremblay NA. The complications of tracheal intubation: a new classification with a review of the literature. *Anesth Analg* 1974;53(2):202–213.
3. Hartley M, Vaughan RS. Problems associated with tracheal extubation. *Br J Anaesth* 1993;71(4):561–568.