

## Late Presentation of Double Aortic Arch in School-Age Children Presumed to Have Asthma: The Benefits of Spirometry and Examination of the Flow-Volume Curve

Derek A Uchida MD

**Children with double aortic arch most often present in infancy. This report presents 3 patients in whom the diagnosis of double aortic arch was not revealed until later in childhood. They were all given a misdiagnosis of asthma, but abnormalities detected on the flow-volume curve led to the true diagnosis.** *Key words: aorta, asthma, maximal expiratory flow-volume curves, spirometry.* [Respir Care 2009;54(10):1402–1404. © 2009 Daedalus Enterprises]

### Introduction

Extrinsic compression of the airway by vascular rings causes respiratory symptoms and/or feeding abnormalities that usually result in prompt diagnosis during early infancy.<sup>1,2</sup> However, there are rarer occasions when the diagnosis is delayed by many years. This report presents 3 cases of children with double aortic arch who were treated for several years for poorly controlled asthma. In all 3 cases, analysis of the flow-volume curve provided valuable clues regarding the true diagnosis.

### Case Reports

#### Case 1

An 11-year-old male presented with a history of chest congestion and cough since 7 months of age. A sweat test as a young child was normal, and he was given a diagnosis of asthma. Over time his symptoms failed to improve with fluticasone, montelukast, and albuterol. He complained of shortness of breath in the morning and with physical activity. Previous chest radiographs were interpreted as nor-

mal. He was referred to our asthma clinic. Spirometry was done for the first time (Table 1). The flow-volume curve was noted to have a plateau of forced expiratory flow and a suggestion of a plateau on the inspiratory limb as well (Fig. 1). A fixed central airway obstruction was suspected. A computed tomography angiogram was ordered and demonstrated a vascular ring, consisting of a double aortic arch with right-arch dominance. Surgical treatment resulted in substantial improvement in symptoms, but persistent abnormality of the expiratory limb of the flow-volume curve. He has not been on routine medications for asthma since the surgery.

#### Case 2

An 11-year-old female presented with a history of wheezing since infancy. She was treated for gastroesophageal reflux, without benefit, and subsequently diagnosed with asthma. Despite treatment with fluticasone-salmeterol and montelukast, spirometry in her pediatrician's office showed a forced expiratory volume in the first second (FEV<sub>1</sub>) of 71% of predicted, which did not improve after albuterol. She was referred to our asthma clinic. Spirometry values suggested an obstructive ventilatory defect (see Table 1). The flow-volume curve was noted to have plateaus on both the inspiratory and expiratory limbs (see Fig. 1). A chest radiograph demonstrated a right-sided aortic arch. This combination of findings prompted further imaging with a computed tomography scan of the chest. This study revealed a double aortic arch with partial atresia of the left arch between the left subclavian artery and descending aorta. Surgical treatment resulted in resolution of her re-

---

Derek A Uchida MD is affiliated with the Department of Pediatric Pulmonology, Primary Children's Medical Center, University of Utah School of Medicine, Salt Lake City, Utah.

The author has disclosed no conflicts of interest.

Correspondence: Derek A Uchida MD, Department of Pediatric Pulmonology, Primary Children's Medical Center, University of Utah School of Medicine, 100 North Mario Capecchi Drive, Salt Lake City, UT 84113. E-mail: derek.uchida@hsc.utah.edu.

Table 1. Spirometry Data

	Case 1	Case 2	Case 3
FVC (L, % predicted)	2.52 (100)	2.88 (107)	1.72 (90)
FEV <sub>1</sub> (L, % predicted)	1.95 (85)	2.19 (89)	1.32 (77)
FEV <sub>1</sub> /FVC	0.77	0.76	0.77
FEV <sub>1</sub> /PEF (mL/L/min)	11	14	13

FVC = forced vital capacity  
 FEV<sub>1</sub> = forced expiratory volume in the first second  
 PEF = peak expiratory flow

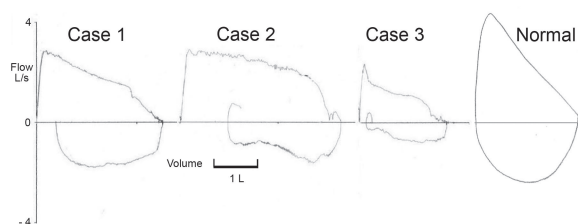


Fig. 1. Representative flow-volume curves from the 3 cases. The last curve is an example of a normal flow-volume curve for comparison.

spiratory symptoms; she has not had spirometry performed since the surgery.

### Case 3

A 9-year-old female presented with a history of cough since birth. As an infant, while living in a different state, she underwent bronchoscopy and was given a diagnosis of tracheomalacia. She continued to have episodes of coughing triggered by cold weather and viral respiratory infections, and was diagnosed with asthma. The interpretation of a chest radiograph performed a year prior to presentation raised the question regarding the presence of a right aortic arch (Fig. 2A). She was referred to our asthma clinic because of persistent symptoms despite albuterol use, and spirometry was performed for the first time (see Table 1 and Fig. 1). The configuration of the flow-volume curve prompted further evaluation. Computed tomography angiogram of the chest demonstrated a double aortic arch with right-arch dominance (see Fig. 2B). She is still symptomatic after surgical treatment, and her flow-volume curve continues to show flattening of the expiratory limb. A trial of inhaled ipratropium bromide in place of albuterol was not beneficial.

### Discussion

Double aortic arch is a type of vascular ring in which the ascending aorta bifurcates and forms a right and left

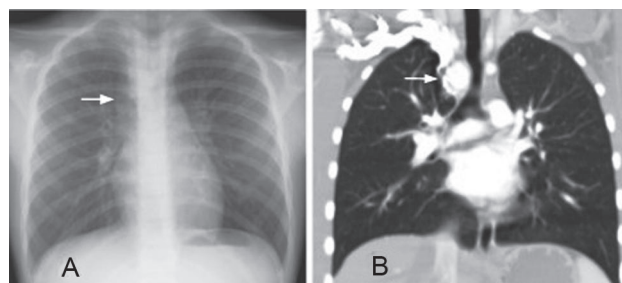


Fig. 2. Imaging studies from case 3. A: Chest radiograph, showing right aortic arch (arrow). B: Computed tomography angiogram, showing the location of the vascular ring, with dominant right arch (arrow). The trachea is narrowed at the level of the ring.

sided arch. The 2 arches encircle the trachea and esophagus, then come together distally to complete the ring and form the descending aorta.<sup>2</sup> Usually the right arch is dominant, or larger, than the left.<sup>2</sup> The diagnosis of double aortic arch is typically made because of the symptoms caused by tracheal and/or esophageal compression. Cough, biphasic stridor, wheezing, increased work of breathing, recurrent respiratory infections, and dysphagia are common symptoms.<sup>2</sup> A finding of a right sided aortic arch on a chest radiograph, as noted in cases 2 and 3, may indicate the presence of this condition.<sup>1</sup> In a recent review of 81 patients with this abnormality, the median age at presentation for double aortic arch was 5 months.<sup>1</sup>

This report describes 3 cases of children, diagnosed at ages 9, 11, and 11 years, with double aortic arch. All were given a diagnosis of asthma but experienced ongoing respiratory symptoms despite asthma therapy. Abnormalities of the shapes of the flow-volume curves of these 3 patients prompted further investigation to evaluate for a central airway obstruction.

Characteristic changes of the shape of the flow-volume curve should prompt clinicians to consider a diagnosis of central airway obstruction from vascular rings or other causes.<sup>3</sup> Typically, with a fixed intrathoracic tracheal obstruction such as double aortic arch, there is a plateau of both inspiratory and expiratory flows.<sup>4</sup> With variable intrathoracic obstruction, such as what might be encountered with other types of vascular rings<sup>3</sup> or tracheomalacia, a plateau is present on expiratory flow but lacking on inspiration.<sup>4</sup> As with all aspects of spirometry, it is of utmost importance that patients' efforts are maximal and repeatable for accurate flow-volume curves to be obtained<sup>4</sup>; this can be particularly difficult in the pediatric population.

Despite surgical correction, some children with a history of vascular rings continue to display abnormalities of pulmonary function,<sup>5</sup> possibly due to persistent tracheomalacia at the site of tracheal narrowing from the ring.<sup>6</sup> Of note, tracheomalacia was diagnosed during infancy in case 3, and she remained symptomatic, with persistent flow-volume-curve abnormalities despite surgical treat-

ment. A trial of inhaled ipratropium bromide was instituted, given evidence that albuterol may worsen expiratory flow rates in patients with tracheomalacia.<sup>7</sup> Unfortunately, this did not result in clinical benefit to the patient.

This report underscores the importance of spirometry in the evaluation of patients with presumed asthma. Despite institution of long-term controller therapy for asthma, 2 patients in this case series continued to have symptoms and demonstrated important abnormalities on spirometry. This lack of response to standard asthma therapy was an indication that an alternative diagnosis should be considered. National guidelines for the management of asthma recommend spirometry for patients greater than or equal to 5 years of age, in whom the diagnosis of asthma is being considered.<sup>8</sup> However, 2 of our patients had not undergone spirometry previous to our evaluation, despite years of treatment for asthma, consistent with studies documenting underutilization of this objective measurement in asthmatics.<sup>9</sup>

While spirometry can provide important information regarding lung function in children, this report also underscores the need for proper interpretation of the results, with particular emphasis on careful inspection of the flow-volume curve. In case 2, prior spirometry had been performed but the patient was still presumed to have asthma. The traditional measurements of forced vital capacity (FVC), FEV<sub>1</sub>, and the FEV<sub>1</sub>/FVC ratio in all 3 cases were consistent with an obstructive ventilatory defect such as asthma. However, examination of the flow-volume curves revealed flattening of the inspiratory and expiratory limbs of the flow-volume curves, suggesting a fixed intrathoracic airway obstruction.<sup>4</sup> This prompted further investigations, revealing the true diagnosis of double aortic arch in these children.

There are recommendations for more widespread use of office-based objective measurements, such as spirometry in children with asthma.<sup>8,10</sup> It should be noted that, in contrast to adults with longstanding asthma, FEV<sub>1</sub> in children with asthma is often in the normal range.<sup>10,11</sup> While FEV<sub>1</sub> is a poor indicator of asthma severity in children, the FEV<sub>1</sub>/FVC ratio is often below the normal range in these patients.<sup>11</sup> The FEV<sub>1</sub>/FVC ratio is typically higher in normal children, compared to adults, being as high as 0.97 in preschoolers at 90 cm height, and exhibiting a gradual decrease as the child grows older and increases in height.<sup>12</sup>

Unfortunately, some office-based spirometry systems do not offer flow-volume curve tracings. In these instances, assessment of the FEV<sub>1</sub> and peak expiratory flow (PEF) may be helpful in screening for central airway obstruction.

PEF is typically substantially decreased, compared to FEV<sub>1</sub>, in patients with central airway obstruction, and a value of FEV<sub>1</sub>/PEF greater than 8.8 mL/L/min has been suggested as an indicator of this condition in children.<sup>13</sup> This was found to hold true in our 3 cases (see Table 1).

In summary, establishing a diagnosis of asthma in a child depends in large part on the exclusion of other conditions that may produce similar symptoms. These 3 cases of children misdiagnosed for years with asthma, who in fact had vascular rings of the double-aortic-arch variety, highlight the value of spirometry and the importance of careful examination of the flow-volume curve.

#### REFERENCES

1. Alsenaidi K, Gurofsky R, Karamlou T, Williams WG, McCrindle BW. Management and outcomes of double aortic arch in 81 patients. *Pediatrics* 2006;118(5):e1336-1341.
2. Juraszek AL, Guleserian KJ. Common aortic arch abnormalities: diagnosis and management. *Curr Treat Options Cardiovasc Med* 2006;8(5):414-418.
3. Parker JM, Cary-Freitas B, Berg BW. Symptomatic vascular rings in adulthood: an uncommon mimic of asthma. *J Asthma* 2000;37(3):275-280.
4. Pellegrino R, Viegi G, Brusasco V, Crapo RO, Brugos F, Casaburi R, et al. Interpretative strategies for lung function tests. *Eur Respir J* 2005;26(5):948-968.
5. Bertrand JM, Chartrand C, Lamarre A, Lapierre JG. Vascular ring: clinical and physiological assessment of pulmonary function following surgical correction. *Pediatr Pulmonol* 1986;2(6):378-383.
6. Stoica SC, Lockowandt U, Coulden R, Bilton D, Dunning J. Double aortic arch masquerading as asthma for thirty years. *Respiration* 2002;69(1):92-95.
7. Panitch HB, Keklikian EN, Motley RA, Wolfson MR, Schidlow DV. Effect of altering smooth muscle tone on maximal expiratory flows in patients with tracheomalacia. *Pediatr Pulmonol* 1990;9(3):170-176.
8. US Department of Health and Human Services; National Institutes of Health; National Heart, Lung, and Blood Institute; National Asthma Education and Prevention Program. Expert Panel Report 3. Guidelines for the diagnosis and management of asthma. NIH Publication 08-4051; 2007.
9. Cabana M, Slish KK, Nan B, Leo H, Bratton SL, Dombkowski KJ. Outcomes associated with spirometry for pediatric asthma in a managed care organization. *Pediatrics* 2006;118(1):e151-e156.
10. Spahn JD, Chipps BE. Office-based objective measures in childhood asthma. *J Pediatr* 2006;148(1):11-15.
11. Bacharier LB, Strunk RC, Mauget D, White D, Lemanske RF Jr, Sorkness CA. Classifying asthma severity in children: mismatch between symptoms, medication use, and lung function. *Am J Respir Crit Care Med* 2004;170(4):426-432.
12. Eigen H, Bieler H, Grant D, Christoph K, Terrill D, Heilman DK, et al. Spirometric pulmonary function in healthy preschool children. *Am J Respir Crit Care Med* 2001;163(3 Pt 1):619-623.
13. Linna O, Hyrynkanas K, Lanning P, Nieminen P. Central airways stenosis in school-aged children: differential diagnosis from asthma. *Acta Paediatr* 2002;91(4):399-402.