

Bronchoscopy During Noninvasive Ventilation: Indications and Technique

Septimiu D Murgu MD, Jocelyn Pecson RN RRT, and Henri G Colt MD

Introduction

Indications for Noninvasive Ventilation During Bronchoscopy

Severe Refractory Hypoxemia

Obstructive Sleep Apnea and Obesity Hypoventilation Syndrome

Bronchoscopy in Pediatric Patients

Postoperative Respiratory Distress

Severe Chronic Obstructive Pulmonary Disease

Expiratory Central-Airway Collapse

Contraindications

Technique

Summary

Diagnostic or therapeutic flexible bronchoscopy is often necessary in severely ill patients. These patients often have comorbidities that increase the risk of bronchoscopy-related complications. Noninvasive ventilation might decrease the risk of these complications in patients with severe refractory hypoxemia, postoperative respiratory distress, or severe emphysema, and in pediatric patients. Noninvasive ventilation may prevent hypoventilation in patients with obstructive sleep apnea and obesity hypoventilation syndrome who require bronchoscopy, and may assist in the bronchoscopic evaluation of patients with expiratory central-airway collapse. We describe the indications, contraindications, and technique of flexible bronchoscopy during noninvasive ventilation. Key words: bronchoscopy; non-invasive ventilation; NIV; continuous positive airway pressure; CPAP; complications; patient safety; respiratory failure. [Respir Care 2010;55(5):595–600. © 2010 Daedalus Enterprises]

Introduction

Noninvasive ventilation (NIV) is frequently used to treat obstructive sleep apnea, obesity hypoventilation syndrome, exacerbations of chronic obstructive pulmonary disease (COPD), and chronic respiratory failure in neuromuscular

disease.¹⁻³ According to international consensus, NIV is defined as any form of ventilatory support applied without endotracheal intubation, and therefore includes continuous positive airway pressure (CPAP) and bi-level positive airway pressure (BiPAP) among other modes.⁴ NIV via nasal or face mask improves postoperative hypoxemia⁵; reduces pulmonary complications after cardiac, upper-abdominal, or thoracic surgery⁶⁻⁸; facilitates weaning in patients intubated for exacerbation of COPD⁹; and reduces intubation rate in patients with acute cardiogenic pulmonary edema¹⁰ and in immunocompromised patients with hypoxic respiratory failure^{11,12}. Several studies have evaluated NIV's role in preventing intubation during bronchoscopy in high-risk patients.^{13,14} Furthermore, patients with symptomatic expiratory central-airway collapse may benefit from NIV.¹⁵ The purpose of this article is to describe the indications for NIV during bronchoscopy and to describe the technique.

Septimiu D Murgu MD, Jocelyn Pecson RN RRT, and Henri G Colt MD are affiliated with the Division of Pulmonary and Critical Care Medicine, Department of Medicine, University of California School of Medicine, Irvine, California.

The authors have disclosed no conflicts of interest.

Correspondence: Septimiu D Murgu MD, Division of Pulmonary and Critical Care Medicine, Department of Medicine, University of California School of Medicine, 101 The City Drive South, Building 53, Room 119, Route 81, Orange CA 92868. E-mail: smurgu@uci.edu.

Indications for Noninvasive Ventilation During Bronchoscopy

Severe Refractory Hypoxemia

Bronchoscopy in patients with respiratory disorders can be challenging. The bronchoscope occupies 10–15% of the normal tracheal lumen and can increase the work of breathing and decrease P_{aO_2} by 10–20 mm Hg, which can cause respiratory complications and cardiac arrhythmia.¹⁶ Hypoxemia occurs with insertion of the bronchoscope through the glottis into the trachea, and becomes worse when local anesthetics or saline solution is instilled into the lower airways. Bronchoalveolar lavage is associated with worse oxygen desaturation than when lavage is not done.¹⁷ Furthermore, suction during bronchoscopy reduces the end-expiratory volume and positive end-expiratory pressure and thus causes alveolar closure.

Though hypoxemia is associated with cardiac arrhythmias in 11–40% of patients who undergo fiberoptic bronchoscopy, these cardiac rhythm disturbances are rarely clinically important. The American Thoracic Society, however, recommends avoiding flexible bronchoscopy and bronchoalveolar lavage in patients with hypoxemia that cannot be corrected to at least a P_{aO_2} of 75 mm Hg or to an arterial oxygen saturation of > 90% with supplemental oxygen.¹⁸ In these higher-risk patients the traditional alternatives are avoidance of bronchoscopy and empirical treatment, or intubation and mechanical ventilation to assure adequate ventilation during bronchoscopy. Endotracheal intubation and mechanical ventilation have potentially severe complications, however, and in many patients NIV is a valid alternative to intubation, especially in immunosuppressed patients^{12,19} and in critically ill patients with pneumonia.²⁰ Single and multicenter randomized studies found, however, that in a heterogeneous group of patients with a history of cardiac or respiratory disease and who developed respiratory distress during the first 48 hours after extubation, the addition of NIV to standard medical therapy did not improve re-intubation rate, hospital mortality, intensive-care-unit stay, or hospital stay.^{21,22} In fact, in that patient population NIV may be harmful and increase the risk of death from cardiac ischemia, respiratory muscle fatigue, aspiration pneumonitis, or complications of emergency intubation.²²

In other studies NIV improved oxygenation, compared to high-flow oxygen alone, during bronchoscopy in patients at high risk for respiratory complications due to severe hypoxemia.^{13,23} Note, however, that oxygen supplementation alone is not the standard of practice in severe respiratory conditions with severe hypoxemia. That population might be better served by intubation or NIV, regardless of their need for bronchoscopy; but, to our knowledge, there have been no head-to-head trials of NIV versus intubation in severely hypoxemic patients who required bronchoscopy.

Small studies have suggested that NIV during bronchoscopy might be a safe and effective alternative to intubation for maintaining adequate gas exchange in high-risk immunosuppressed patients.²⁴ There was no clear outcome benefit, however, because those studies were underpowered to identify a significant difference in intubation rate. Furthermore, the oxygenation improvement might not have any clinical relevance.

Obstructive Sleep Apnea and Obesity Hypoventilation Syndrome

The causes of hypoxemia during bronchoscopy include ventilation-perfusion mismatch from obstruction by the bronchoscope, suction, lavage fluid in the alveoli, and probably unmasking of latent obstructive sleep apnea from the sedation.²⁵ The hypoxemia risk may be even higher in patients with obesity hypoventilation syndrome who already have awake hypercapnia.²⁶

Mechanical ventilation modes counteract the negative inspiratory forces by applying pressure into the oropharynx and thus compensate for any hypotonicity of the upper-airway muscles, which assists in the treatment of obstructive sleep apnea. The collapse of the pharyngeal airway and the response to CPAP have been documented bronchoscopically.^{27,28}

Case reports have documented the benefit of nasal CPAP applied to one nostril with a nasal pillow to maintain ventilation in morbidly obese patients during intubation; the CPAP splints the airway open and thus facilitates the visualization of anatomic landmarks and the translaryngeal passage of the bronchoscope.²⁹ Though prompt endotracheal intubation and complete airway protection may be necessary in these patients with potentially difficult airways, CPAP may assure ventilation—sometimes better than laryngeal mask airway—during fiberoptic intubation, although there is a greater risk of gastric insufflation.³⁰

Bronchoscopy in Pediatric Patients

Young children are at higher risk for hypoxemia and hypercapnia during bronchoscopy, because their airways are narrower and more collapsible than those of older children and adults, and the bronchoscope imposes a proportionally higher resistance.³¹ CPAP increases the width of the compliant laryngeal opening and decreases the collapsibility of the lateral pharyngeal walls, which are thought to be the most compliant structures in the upper airway.³² Flexible bronchoscopy in spontaneously breathing young children is associated with significant decreases in tidal volume and peak tidal inspiratory and expiratory flows, which were reversed by CPAP.³³

Postoperative Respiratory Distress

Respiratory distress from mucus plugging after thoracic or abdominal surgery may necessitate intubation and me-




Fig. 1. Patient with expiratory central-airway collapse from congenital tracheobronchomegaly (Mounier-Kuhn syndrome) undergoing flexible bronchoscopy for secretion removal during noninvasive ventilation while supine (A) and upright (B). In the picture, the image on the monitor shows the severity of airway collapse.

chanical ventilation, which can lead to lung injury, poor surgical outcome, and prolonged hospital stay. Flexible bronchoscopy may aid in the removal of the mucus plugs from the tracheobronchial tree and improve ventilation and oxygen exchange, thereby avoiding intubation.³⁴ A spontaneously breathing patient with hypoxemia despite maximum supplemental oxygen may benefit most from bronchoscopy on NIV.

Severe Chronic Obstructive Pulmonary Disease

In patients with severe emphysema, bronchoscopy can lead to air trapping because functional residual capacity (FRC) increases by 17% when the scope is inserted transnasally.³⁵ Positive-pressure ventilation may counteract the intrinsic positive end-expiratory pressure physiology. In fact, NIV has also been reported to be useful in performing uncomplicated bronchoscopy in hypercapnic COPD patients with pneumonia.¹⁴

Expiratory Central-Airway Collapse

NIV is a conservative treatment alternative for patients with expiratory central-airway collapse.³⁶ NIV can be used to maintain airway patency, facilitate secretion drainage, and improve expiratory flow. Small studies have shown that the addition of nasal CPAP improves spirometry values, sputum production, atelectasis, and exercise tolerance.^{15,37-39} The presumed mechanism is “pneumatic stenting,” defined as increased transmural pressure in the central airways because of the increased intraluminal pressure from the NIV, which increases the cross-sectional area of the airway lumen.³⁷

Alternative explanations have been proposed, however, which challenge the concept of pneumatic stenting.⁴⁰ Since

the measured flow and the shape of the flow-volume curve depend on the lung volume at which they are measured, expiratory flow is greater at higher lung volume than at lower lung volume. CPAP significantly increases the peak expiratory flow at FRC in healthy infants and in infants with tracheomalacia. This flow increase at FRC was secondary to the increased lung volume with CPAP, since the peak expiratory flows measured at different CPAP levels were not different when compared at the same lung volumes. Therefore, the optimal CPAP level in infants with severe tracheomalacia may be related to increasing the lung volume to the level at which the infant is not flow-limited during tidal breathing, without also significantly increasing the work of breathing by decreasing the pulmonary compliance at increased lung volume.

Panitch et al measured expiratory resistance, mid-expiratory tidal flow, and maximum flow at FRC at CPAP of 0, 4, and 8 cm H₂O. Maximum flow at FRC increased 3-fold from baseline to CPAP of 8 cm H₂O ($P < .005$). However, there was no difference in expiratory resistance or in mid-expiratory tidal flow at any CPAP level. These data suggest that in infants with acquired tracheobronchomalacia, assessment of forced expiratory flow reflects the amount of CPAP necessary to prevent airway collapse during forced exhalation better than can measurements of tidal mechanics.⁴¹

Regardless of the mechanism of action, based on limited data, NIV does improve symptoms in expiratory central-airway collapse, and can be used during bronchoscopy in these patients to maintain airway lumen patency⁴² and to titrate the pressure needed to limit airway collapse to the accepted normal value of $< 50\%$ during exhalation (Fig. 1). Prospective studies are needed, however, to objectively document improvements in dyspnea, functional status, and severity of airway collapse.

Table 1. Advantages and Disadvantages of NIV and ETT During Bronchoscopy

	Advantages	Disadvantages
NIV Bronchoscopy	<p>Potentially avoids complications related to ETT and prolonged mechanical ventilation</p> <p>Allows for spontaneous breathing, which improves ventilation-perfusion matching and hemodynamic profile</p> <p>Can be performed outside the intensive care unit for evaluating expiratory central-airway collapse</p> <p>Allows a complete airway examination</p> <p>Less need for sedation</p>	<p>Contraindicated in many critically ill patients because of:</p> <ul style="list-style-type: none"> • Severe acidosis (pH < 7.2) • Copious secretions • Hemodynamic instability • Mental status changes resulting in inability to protect airway • O₂ saturation < 85% despite high F_{IO₂} <p>May cause gastric distention and increase the risk of aspiration</p>
ETT Bronchoscopy	<p>Offers a stable, secure airway</p> <p>Better CO₂ clearance</p> <p>Better oxygenation</p> <p>Unloads respiratory muscles</p> <p>Reduces risk of aspiration</p> <p>Allows repeated insertion of the bronchoscope through the ETT, for secretion removal or if hypoventilation occurs during bronchoscopy.</p>	<p>Detrimental effects from mechanical ventilation</p> <ul style="list-style-type: none"> • Alveoli over-distention injury • Cardiac impairment • Air-trapping • Patient-ventilator dyssynchrony <p>If prolonged need for mechanical ventilation, there is increased risk of:</p> <ul style="list-style-type: none"> • Ventilator-associated pneumonia • Ventilator-induced lung injury • Airway injury • Post-extubation tracheal stenosis <p>Complete examination of the upper airways and upper trachea might not be possible with an indwelling ETT</p> <p>Increased need for sedation and/or paralytic agents</p> <p>Potential hypoventilation, intrinsic PEEP, and high peak airway pressure if ETT/bronchoscope-diameter difference is < 2 mm</p>

NIV = noninvasive ventilation

ETT = endotracheal tube

F_{IO₂} = fraction of inspired oxygen

PEEP = positive end-expiratory pressure

Contraindications

The contraindications to bronchoscopy on NIV are the same as for any NIV application. These include conditions resulting in high aspiration risk or inability to protect the airway, such as emergency intubation (ie, cardiopulmonary resuscitation, respiratory arrest, severe hemodynamic instability, or encephalopathy); psychomotor agitation; respiratory failure caused by neurologic disease or status asthmaticus; the presence of facial deformities; and recent oral, esophageal, or gastric surgery.⁴³ Furthermore, inability to maintain oxygen saturation above 85% despite a high fraction of inspired oxygen (F_{IO₂}) is considered an indication for endotracheal intubation.²² The presence of copious secretions that cannot be cleared or that are associated with acidosis or changes in mental status is also an indication to secure the airway with endotracheal intubation.²² Table 1 summarizes potential advantages and disadvantages of NIV versus endotracheal intubation during bronchoscopy.

Technique

The patient is connected to the ventilator via a full face mask that is secured to the patient's face with elastic straps (Fig. 2). The mask has a dual axis swivel adapter (T-adaptor) and the bronchoscope is advanced to the nares through the swivel adaptor. Air leak is prevented by the tight disposable cap of the swivel adaptor. Silicone or jelly lubricant facilitates advancement of the bronchoscope through the swivel adaptor. Bronchoscopy is then performed in a standard fashion. After laryngeal analgesia with 1% lidocaine (not exceeding 300 mg), the bronchoscope is advanced into the trachea and complete airway examination is performed. Electrocardiography and pulse oximetry are continuously monitored throughout the procedure. Various definitions of severe hypoxemia have been used (P_{aO₂}/F_{IO₂} < 100 mm Hg, and P_{aO₂}/F_{IO₂} < 300 mm Hg) to decide on the use of NIV-facilitated bronchoscopy.^{23,24} We use an oxygen saturation (measured via pulse oximetry [S_{pO₂}]) of ≤ 92% despite F_{IO₂} of 1.0 in a spontaneously breathing patient as the criterion to consider NIV during

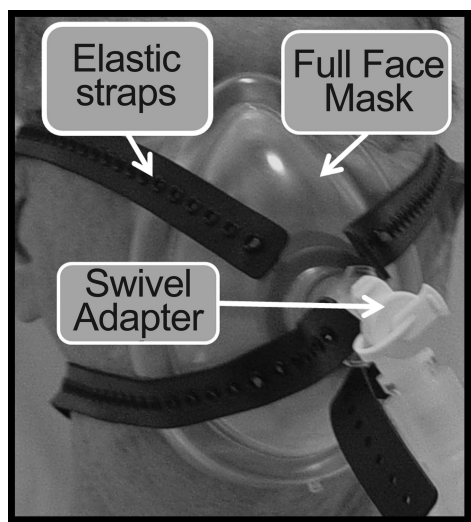


Fig. 2. Face mask, straps, and airway swivel adapter for flexible bronchoscopy during noninvasive ventilation.

bronchoscopy, provided NIV improves oxygen saturation before the bronchoscopy is initiated.

Bronchoalveolar lavage is performed with the tip of the bronchoscope wedged in the bronchial segment of interest, with sequential instillation and retrieval of 3–5 30-mL aliquots of physiologic saline solution.^{20,23,24}

The NIV ventilator settings depend on the clinical indications. In refractory hypoxemia or hypercarbia from COPD, for example, CPAP is set at 5 cm H₂O and pressure-support ventilation is set at 15–17 cm H₂O. During the bronchoscopy, F_{IO₂} is kept at 1.0, and after bronchoscopy is decreased to the pre-bronchoscopy level if the patient is able to maintain S_{pO₂} > 92%. When NIV is used for bronchoscopy in a severely hypoxemic patient, positive-pressure ventilation is maintained for at least 30 min after the procedure, after which NIV can be discontinued if S_{pO₂} remains > 92% and there is no evidence of respiratory insufficiency.

If necessary, as in the evaluation of central-airway collapse, procedures can be performed in the upright or supine position, as well as on or off NIV to evaluate the degree of airway narrowing and response to CPAP (see Fig. 1). In excessive dynamic airway collapse or tracheobronchomalacia, CPAP of 7–10 cm H₂O usually assures airway patency, as has been suggested in small case series and case reports.^{15,39} The pressure can be incrementally raised by 3 cm H₂O, until airway caliber during exhalation is at least 50% of that during inspiration. The exact CPAP setting that maintains airway patency in patients with various degrees of expiratory central-airway collapse has not been systematically studied. If central-airway collapse is evaluated, photographic and/or video documentation is obtained in the upright and supine position, and on and off CPAP, to evaluate the airway narrowing and response to CPAP.

Other techniques of NIV-facilitated bronchoscopy have been reported.^{20,43} Antonelli et al conducted bronchoscopy through an NIV helmet, with 10–20 cm H₂O pressure support, 8–15 cm H₂O positive end-expiratory pressure, and the lowest F_{IO₂} that maintained peripheral oxygen saturation ≥ 92%.²⁰ Recently, Heunks et al modified a total full face mask by inserting a synthetic plastic cylinder that was secured in the mask at a position that allows introduction of the bronchoscope through the mouth without interfering with the ventilator circuit. Air leakage was prevented with a disposable cap from a swivel adaptor, which sealed the cylinder.⁴³

Summary

Clinicians may recommend endotracheal intubation in order to perform flexible bronchoscopy in patients at high risk for respiratory failure, such as those with severe refractory hypoxemia, severe COPD, postoperative respiratory failure, or severe obstructive sleep apnea and obesity hypoventilation syndrome. Bronchoscopy on NIV may be an alternative in these patients. While knowing the feasibility and safety of diagnostic and therapeutic bronchoscopy on NIV is warranted because it can avoid intubation and its associated risks, the evidence to support bronchoscopy on NIV is based on studies that were underpowered to detect changes in major clinical outcomes. Future studies should clarify whether NIV-facilitated bronchoscopy impacts intubation rate or mortality in this high-risk critically ill group.

REFERENCES

1. Ellis ER, Bye PT, Bruderer JW, Sullivan CE. Treatment of respiratory failure during sleep in patients with neuromuscular disease. Positive-pressure ventilation through a nose mask. *Am Rev Respir Dis* 1987;135(1):148-152.
2. Gay PC, Patel AM, Viggiano RW, Hubmayr RD. Nocturnal nasal ventilation for treatment of patients with hypercapnic respiratory failure. *Mayo Clin Proc* 1991;66(7):695-703.
3. Hill NS, Eveloff SE, Carlisle CC, Goff SG. Efficacy of nocturnal nasal ventilation in patients with restrictive thoracic disease. *Am Rev Respir Dis* 1992;145(2 Pt 1):365-371.
4. International consensus conference in intensive care medicine: non-invasive positive pressure ventilation in acute respiratory failure. *Am J Respir Crit Care Med* 2001;163(1):283-291.
5. Kindgen-Milles D, Buhl R, Gabriel A, Bohner H, Muller E. Nasal continuous positive airway pressure: a method to avoid endotracheal reintubation in postoperative high-risk patients with severe nonhypercapnic oxygenation failure. *Chest* 2000;117(4):1106-1111.
6. Kindgen-Milles D, Muller E, Buhl R, Bohner H, Ritter D, Sandmann W, Tarnow J. Nasal-continuous positive airway pressure reduces pulmonary morbidity and length of hospital stay following thoraco-abdominal aortic surgery. *Chest* 2005;128(2):821-828.
7. Auriant I, Jallot A, Hervé P, Cerrina J, Le Roy Ladurie F, Fournier JL, et al. Noninvasive ventilation reduces mortality in acute respiratory failure following lung resection. *Am J Respir Crit Care Med* 2001;164(7):1231-1235.

8. Squadrone V, Cocha M, Cerutti E, Schellino MM, Biolino P, Occella P, et al. Continuous positive airway pressure for treatment of postoperative hypoxemia: a randomized controlled trial. *JAMA* 2005;293(5):589-595.
9. Ram FS, Picot J, Lightowler J, Wedzicha JA. Non-invasive positive pressure ventilation for treatment of respiratory failure due to exacerbations of chronic obstructive pulmonary disease. *Cochrane Database Syst Rev* 2004;(3):CD004104.
10. Masip J, Roque M, Sanchez B, Fernandez R, Subirana M, Exposito JA. Noninvasive ventilation in acute cardiogenic pulmonary edema. Systematic review and meta-analysis. *JAMA* 2005;294(24):3124-3130.
11. Depuydt PO, Benoit DD, Vandewoude KH, Decruyenaere JM, Colardyn FA. Outcome in noninvasively and invasively ventilated hematologic patients with acute respiratory failure. *Chest* 2004;126(4):1299-1306.
12. Hilbert G, Gruson D, Vargas F, Valentino R, Gbikpi-Benissan G, Dupon M, et al. Noninvasive ventilation in immunosuppressed patients with pulmonary infiltrates, fever, and acute respiratory failure. *N Engl J Med* 2001;344(7):481-487.
13. Antonelli M, Conti G, Rocco M, Arcangeli A, Cavaliere F, Proietti R, Meduri GU. Noninvasive positive-pressure ventilation versus conventional oxygen supplementation in hypoxemic patients undergoing diagnostic bronchoscopy. *Chest* 2002;121(4):1149-1154.
14. Da Conceicao M, Genco G, Favier JC, Bidallier I, Pitti R. Fiberoptic bronchoscopy during non-invasive positive pressure ventilation in patients with chronic obstructive lung disease with hypoxemia and hypercapnea. *Ann Fr Anesth Reanim* 2000;19(4):231-236.
15. Wiseman NE, Duncan PG, Cameron CB. Management of tracheobronchomalacia with continuous positive airway pressure. *J Pediatr Surg* 1985;20(5):489-493.
16. Payne CB Jr, Goyal PC, Gupta SC. Effects of transoral and transnasal fiberoptic bronchoscopy on oxygenation and cardiac rhythm. *Endoscopy* 1986;18(1):1-3.
17. Katz AS, Michelson EL, Stawicki J, Holford FD. Cardiac arrhythmias, frequency during fiberoptic bronchoscopy and correlation with hypoxemia. *Arch Intern Med* 1981;141(5):603-606.
18. Goldstein RA, Rohatgi PK, Bergofsky EH, Block ER, Daniele RP, Dantzker DR, et al. Clinical role of bronchoalveolar lavage in adults with pulmonary disease. *Am Rev Respir Dis* 1990;142(2):481-486.
19. Mutlu GM, Factor P. Complications of mechanical ventilation. *Respir Care Clin N Am* 2000;6(2):213-252.
20. Antonelli M, Pennisi M, Conti G, Bello G, Maggiore SM, Michetti V, et al. Fiberoptic bronchoscopy during noninvasive positive pressure ventilation delivered by helmet. *Intensive Care Med* 2003;29(1):126-129.
21. Keenan SP, Powers C, McCormack DG, Block G. Noninvasive positive-pressure ventilation for postextubation respiratory distress: a randomized controlled trial. *JAMA* 2002;287(24):3238-3244.
22. Esteban A, Frutos-Vivar F, Ferguson ND, Arabi Y, Apezteguia C, Gonzalez M, et al. Noninvasive positive-pressure ventilation for respiratory failure after extubation. *N Engl J Med* 2004;350(24):2452-2460.
23. Maitre B, Jaber S, Maggiore SM, Bergot E, Richard JC, Bakthiari H, et al. Continuous positive airway pressure during fiberoptic bronchoscopy in hypoxemic patients: a randomized double-blind study using a new device. *Am J Respir Crit Care Med* 2000;162(3 Pt 1):1063-1067.
24. Antonelli M, Conti G, Riccioni L, Meduri GU. Noninvasive positive-pressure ventilation via face mask during bronchoscopy with BAL in high-risk hypoxemic patients. *Chest* 1996;110(3):724-728.
25. Chhajed PN, Aboyou C, Malouf MA, Hopkins PM, Plit M, Grunstein RR, Glanville AR. Management of acute hypoxemia during flexible bronchoscopy with insertion of a nasopharyngeal tube in lung transplant recipients. *Chest* 2002;121(4):1350-1354.
26. Mokhlesi B, Tulaimat A. Recent advances in obesity hypoventilation syndrome. *Chest* 2007;132(4):1322-1336.
27. Popper RA, Leidinger MJ, Williams AJ. Endoscopic observations of the pharyngeal airway during treatment of obstructive sleep apnea with nasal continuous positive airway pressure-A pneumatic splint. *West J Med* 1986;144(1):83-85.
28. Borowiecki B, Pollak CP, Weitzman ED, Rakoff S, Imperato J. Fibro-optic study of pharyngeal airway during sleep in patients with hypersomnia obstructive sleep-apnea syndrome. *Laryngoscope* 1978;88(8 Pt 1):1310-1313.
29. Rothfleisch R, Davis LL, Kuebel DA, deBoisblanc BP. Facilitation of fiberoptic nasotracheal intubation in a morbidly obese patient by simultaneous use of nasal CPAP. *Chest* 1994;106(1):287-288.
30. Aoyama K, Yasunaga E, Takenaka I, Kadoya T, Sata T, Shigematsu A. Positive pressure ventilation during fiberoptic intubation: comparison of the laryngeal mask airway, intubating laryngeal mask and endoscopy mask techniques. *Br J Anaesth* 2002;88(2):246-254.
31. Schnapf BM. Oxygen desaturation during fiberoptic bronchoscopy in pediatric patients. *Chest* 1991;99(3):591-594.
32. Kuna ST, Bedi DG, Ryckman C. Effect of nasal airway positive pressure on upper airway size and configuration. *Am Rev Respir Dis* 1988;138(4):969-975.
33. Trachsel D, Erb TO, Frei FJ, Hammer J; Swiss Paediatric Respiratory Research Group. Use of continuous positive airway pressure during flexible bronchoscopy in young children. *Eur Respir J* 2005;26(5):773-777.
34. Dellinger RP. Fiberoptic bronchoscopy in adult airway management. *Crit Care Med* 1990;18(8):882-887.
35. Matsushima Y, Jones RL, King EG, Moysa G, Alton JD. Alterations in pulmonary mechanics and gas exchange during routine fiberoptic bronchoscopy. *Chest* 1984;86(2):184-188.
36. Murgu SD, Colt HG. Treatment of adult tracheobronchomalacia and excessive dynamic airway collapse: an update. *Treat Respir Med* 2006;5(2):103-115.
37. Rozycki HJ, Van Houten ML, Elliott GR. Quantitative assessment of intrathoracic airway collapse in infants and children with tracheobronchomalacia. *Pediatr Pulmonol* 1996;21(4):241-245.
38. Ferguson GT, Benoist J. Nasal continuous positive airway pressure in the treatment of tracheobronchomalacia. *Am Rev Respir Dis* 1993;147(2):457-461.
39. Adliff M, Ngato D, Keshavjee S, Brenaman S, Granton JT. Treatment of diffuse tracheomalacia secondary to relapsing polychondritis with continuous positive airway pressure. *Chest* 1997;112(6):1701-1704.
40. Davis S, Jones M, Kisling J, Angelicchio C, Tepper RS. Effect of continuous positive airway pressure on forced expiratory flows in infants with tracheomalacia. *Am J Respir Crit Care Med* 1998;158(1):148-152.
41. Panitch HB, Allen JL, Alpert BE, Schidlow DV. Effects of CPAP on lung mechanics in infants with acquired tracheobronchomalacia. *Am J Respir Crit Care Med* 1994;150(5 Pt 1):1341-1346.
42. Miller RW, Pollack MM, Murphy TM, Fink RJ. Effectiveness of continuous positive airway pressure in the treatment of bronchomalacia in infants: a bronchoscopic documentation. *Crit Care Med* 1986;14(2):125-127.
43. Heunks LM, de Bruin CJ, van der Hoeven JG, van der Heijden HF. Non-invasive mechanical ventilation for diagnostic bronchoscopy using a new face mask: an observational feasibility study. *Intensive Care Med* 2010;36(1):143-147.