

Alveolar Dead-Space Response to Activated Protein C in Acute Respiratory Distress Syndrome

Richard H Kallet MSc RRT FAARC, Robert M Jasmer MD, and Jean-François Pittet MD

We report a complicated case of acute respiratory distress syndrome (ARDS) from severe sepsis, in which we measured the ratio of physiologic dead space to tidal volume (V_D/V_T) with volumetric capnography prior to, during, and after therapy with human recombinant activated protein C. Previous studies hypothesized that early in ARDS, elevated V_D/V_T primarily reflects increased alveolar V_D , probably caused by pronounced thrombi formation in the pulmonary microvasculature. This may be particularly true when severe sepsis is the cause of ARDS. We repeatedly measured V_D/V_T in a 29-year-old man with sepsis-induced ARDS over the course of activated protein C therapy. Treatment with activated protein C resulted in a pronounced reduction in V_D/V_T , from 0.55 to 0.27. Alveolar V_D decreased from 165 mL to 11 mL (93% reduction). Activated protein C was terminated at 41 h because of gastrointestinal bleeding. When the measurement was repeated 29 h after therapy was discontinued, V_D/V_T had increased modestly, to 0.34, whereas alveolar V_D had increased to 71 mL, or 43% of the pre-activated-protein-C baseline measurement. Alveolar V_T rose from 260 mL to 369 mL and decreased slightly after termination of activated protein C (336 mL). Over the course of activated protein C therapy there was a persistent decrease in alveolar V_D and increase in alveolar V_T , even while positive end-expiratory pressure was reduced and respiratory-system compliance decreased. Thus, improved alveolar perfusion persisted despite signs of alveolar de-recruitment. This suggests that activated protein C may have reduced microvascular obstruction. This report provides indirect evidence that microvascular obstruction may play an important role in elevated V_D/V_T in early ARDS caused by severe sepsis. *Key words:* acute respiratory distress syndrome; ARDS; activated protein C; alveolar dead-space; lung-protective ventilation; physiologic dead space; severe sepsis; single-breath test for carbon dioxide; volumetric capnography. [Respir Care 2010;55(5):617–622. © 2010 Daedalus Enterprises]

Introduction

Inflammation, microvascular injury, and abnormal pro-coagulation are prominent pathophysiologic features of the acute respiratory distress syndrome (ARDS).¹ These fea-

tures are believed to be a major cause of the elevated ratio of physiologic dead space to tidal volume (V_D/V_T) that is characteristic of the syndrome.² Previously we reported that both early³ and sustained² V_D/V_T increases were associated with a poorer prognosis in ARDS. Therefore, changes in V_D/V_T may be useful in assessing the effectiveness of pharmacologic therapies aimed at reducing inflammation and reversing abnormal pro-coagulation in ARDS. Activated protein C is essential in maintaining proper balance between coagulation and fibrinolysis,⁴ and also has anti-inflammatory properties.⁵ In both ARDS⁶ and severe sepsis,⁷ the plasma activated protein C level is reduced and is associated with both a higher mortality and multiple-organ dysfunction.

In patients with severe sepsis, treatment with human recombinant activated protein C (drotrecogin alfa) significantly reduces mortality as well as markers of inflamma-

Richard H Kallet MSc RRT FAARC and Jean-François Pittet MD are affiliated with the Department of Anesthesia, and Robert M Jasmer MD is affiliated with the Division of Pulmonary and Critical Care Medicine, University of California, San Francisco at San Francisco General Hospital, San Francisco, California.

Mr Kallet has disclosed a relationship with Philips/Respironics. Drs Jasmer and Pittet have disclosed no conflicts of interest.

Correspondence: Richard H Kallet MS RRT FAARC, Respiratory Care Services, San Francisco General Hospital, NH:GA-2, 1001 Potrero Avenue, San Francisco CA 94110. E-mail: rkallet@sfghsom.ucsf.edu.

tion and pro-coagulation.⁸ Although a recent phase-2 study of patients with acute lung injury did not find a mortality reduction, administration of activated protein C significantly reduced V_D/V_T while increasing the plasma activated protein C level.⁹

Physiologic dead space includes both airway (anatomic) and alveolar components, with the latter caused by alterations in pulmonary perfusion. The improvement in both plasma activated protein C and V_D/V_T was therefore attributed to improved microcirculation and better matching of ventilation to perfusion.⁹ Therefore, administration of activated protein C should cause a corresponding decline in alveolar V_D . However, alveolar V_D was not reported in the aforementioned study.⁹ We present a case of severe sepsis-induced ARDS in which both V_D/V_T and alveolar V_D were measured over the course of therapy with activated protein C. Our report provides evidence supporting the hypothesis that microvascular obstruction is an important cause of increased alveolar V_D in sepsis-induced ARDS and can be reversed effectively with activated protein C.

Case Report

The patient was a previously healthy 29-year-old male who presented to the hospital with agitation and altered mental status, vomiting, and shortness of breath. In the emergency department he had a heart rate of 145 beats/min, blood pressure of 134/68 mm Hg, and a core temperature of 36.7°C. Initial blood analysis was notable for a white-blood-cell count of $34.5 \times 10^3/\mu\text{L}$, hematocrit of 47%, creatinine of 2.3 mg/dL, blood urea nitrogen of 48 mg/dL, glucose of 42 mg/dL, and total bilirubin of 3.9 mg/dL.

His oxygen saturation (measured via pulse oximetry) was 80% while breathing room air with a frequency of 28 breaths/min. The patient was placed on a non-rebreathing oxygen mask at 10 L/min, which resulted in an arterial pH of 7.31, P_{aCO_2} of 31 mm Hg, P_{aO_2} of 105 mm Hg, and a base deficit of -10.5 mEq/dL. An initial chest radiograph revealed extensive bilateral patchy infiltrates.

Following emergency intubation the patient was admitted to the medical intensive care unit, where both bronchoscopy with bronchoalveolar lavage and blood cultures were done. Both bronchoalveolar lavage fluid and blood samples were positive for methicillin-resistant *Staphylococcus aureus*. Also on the day of admission, an abdominal/pelvic computed tomogram revealed a large thrombus that extended from the right renal vein to the inferior vena cava. Therefore, the suspected source of ARDS was septic emboli from the deep-vein thrombosis. This suspicion was confirmed when subsequent chest radiographs, taken over the next 2 days, revealed extensive cystic changes in the left lower lobe. Initial antibiotic coverage included ceftriaxone, vancomycin, and trimethoprim-sulfamethoxazole. Five hours after admission, the patient developed septic

shock that required both phenylephrine (267 $\mu\text{g}/\text{min}$) and norepinephrine (3 $\mu\text{g}/\text{min}$) to maintain a mean arterial blood pressure > 60 mm Hg. Approximately 10 h after admission, activated protein C was started at 24 $\mu\text{g}/\text{kg}/\text{h}$.

Lung-protective ventilation was initiated, using the ARDS Network protocol,¹⁰ with volume-control ventilation at a set frequency of 30 breaths/min, a delivered V_T of 577 mL (6.5 mL/kg predicted body weight), and a positive end-expiratory pressure (PEEP) of 10 cm H_2O , which produced an end-inspiratory plateau pressure of 27 cm H_2O . These initial ventilator settings resulted in an arterial pH of 7.28, a P_{aCO_2} of 38 mm Hg and a P_{aO_2} of 80 mm Hg, on an inspired oxygen fraction (F_{IO_2}) of 0.50 ($P_{\text{aO}_2}/F_{\text{IO}_2}$ 160 mm Hg). As septic shock and ARDS worsened, the arterial pH decreased further, to 7.11, and the PEEP and F_{IO_2} requirements rose to 14 cm H_2O and 0.90, respectively, to sustain a P_{aO_2} above 60 mm Hg. This in turn required a further reduction in V_T , to 500 mL (5.6 mL/kg predicted body weight), to maintain plateau pressure under 30 cm H_2O . Patient-ventilator synchrony ultimately required continuous infusions of fentanyl (100 $\mu\text{g}/\text{h}$), midazolam (2 mg/h), and vecuronium at 5.5 mg/h).

Several measurements of V_D/V_T were made to assist ventilator management during the first 3 days of ARDS while the patient was managed on volume-control ventilation. Measurements of mixed expired carbon dioxide partial pressure (P_{ECO_2}) and V_D/V_T were made with an automated volumetric capnograph and pulmonary mechanics monitor (NICO, Respirationics, Wallingford, Connecticut).¹¹ Active humidification was used, and the apparatus dead space of the ventilator circuit was minimized, to approximately 15 mL, which included the dead space of the NICO monitor's Capnostat CO_2/flow sensor.¹¹ The Capnostat sensor and NICO monitor were used only to obtain dead-space measurements, and were removed from the ventilator circuit afterwards.

An arterial blood sample was obtained when P_{ECO_2} stabilized (change of no more than ± 1 mm Hg over 5 min).¹¹ V_D/V_T was calculated by the NICO monitor, which uses the Enghoff modification of the Bohr equation¹²:

$$V_D/V_T = (P_{\text{aCO}_2} - P_{\text{ECO}_2})/P_{\text{aCO}_2}$$

In addition, the NICO monitor incorporates the Fletcher single-breath technique to determine the airway and alveolar components of physiologic dead space and carbon dioxide excretion (\dot{V}_{CO_2}) (Fig. 1).¹³ Alveolar V_T (to perfused alveoli) was calculated as:

$$\text{Expired } V_T = [V_T \times (V_D/V_T)]$$

V_D/V_T was measured at baseline, prior to initiation of activated protein C, and again at 2, 19, 45, and 70 h after

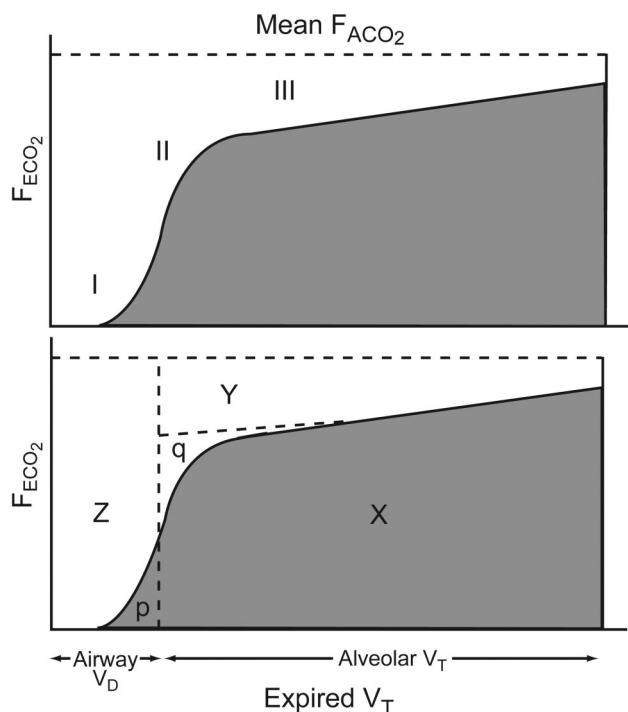


Fig. 1. The Fletcher technique¹³ for measuring dead-space fraction, and its subcomponents of airway dead space (V_D) and alveolar V_D , is based on the single-breath test for carbon dioxide. The horizontal axis represents expired tidal volume (V_T), and the vertical axis represents the fractional concentration of expired carbon dioxide (F_{ECO_2}). The F_{ECO_2} - V_T curve has 3 phases, which are depicted in the upper panel. Phase I, in which the expired volume contains no CO_2 , represents pure airway V_D . Phase II is the rapid upstroke in F_{ECO_2} that indicates the mixing of alveolar gas from fast-emptying lung units (ie, those with short time constants) with airway V_D . Phase III represents pure alveolar gas and is known as the alveolar plateau. The steepness in the upward slope of Phase III represents unequal emptying of alveolar units with different time constants. In the lower panel, Area X represents the volume of expired CO_2 . To calculate airway V_D the expired capnogram is mathematically manipulated to create a 2-compartment model of a single airway and single alveolus. This is achieved by extending the slope of Phase III backwards where it crosses a perpendicular line drawn to bisect the slope of Phase II. Those lines form triangles of equal area (p and q), which creates distinct airway and alveolar compartments. This in turn allows the calculation of airway V_D (area Z). The remaining portion of the expired capnogram represents the V_T distributed to both perfused and unperfused alveoli. Borrowing from the Enghoff method,¹² the arterial P_{CO_2} is used to signify mean alveolar P_{CO_2} across all lung zones, and forms the horizontal line at the top of the figure (for conceptual purposes this is expressed as the mean fractional concentration of alveolar carbon dioxide [F_{ACO_2}]). The area subtended by mean F_{ACO_2} , the slope of Phase III, and the continuation of the line bisecting the slope of Phase II form area Y, which represents the alveolar V_D . The sum of areas Y and Z represents the physiologic V_D . The subtraction of physiologic V_D from the expired V_T allows the estimation of the volume received by perfused alveoli (alveolar V_T).

therapy commenced. All V_D/V_T measurements, except for the last one at 70 h, were made under conditions of passive ventilation while the patient received a neuromuscular

blocking agent. During the last V_D/V_T measurement at 70 h, the patient was synchronous with the ventilator and triggering at a frequency of 3 breaths/min above the mandatory frequency.

During the first 3 days of ARDS the patient's pulmonary function markedly improved in response to activated protein C therapy. There was a substantial decrease in V_D/V_T , as well as lower F_{IO_2} and PEEP requirements, whereas \dot{V}_{CO_2} increased (Table 1). The decrease in physiologic V_D occurred with a corresponding decline in alveolar V_D , to 7% of the baseline value, whereas airway V_D remained relatively stable at 82% of the baseline level (Fig. 2). As alveolar V_D decreased, there was a substantial increase in alveolar V_T , of 140% of the baseline value (see Table 1).

Approximately 41 h after initiation of activated protein C therapy, the patient developed signs of gastrointestinal bleeding, with a decrease in hematocrit and bloody stools; therefore, activated protein C was discontinued. A subsequent measurement made 29 h after termination of activated protein C revealed that alveolar V_D had again increased, to approximately 43% of the baseline value. However, this produced only a modest increase in V_D/V_T , as the rise in alveolar V_D was countered by a 5% (20 mL) decrease in airway V_D , due to the effects of decreased PEEP and increased inspiratory time.

On day 10 of ARDS a thrombolectomy was performed and an inferior vena cava filter was placed via interventional radiology. Intravenous heparin therapy was initiated twice but had to be discontinued because of bleeding. Unfortunately, the patient's condition continued to deteriorate, with worsening necrotizing pneumonia. This resulted in several episodes of tension pneumothoraces, as well as the development of a large pleural effusion that was loculated and difficult to drain. The patient also developed acute renal failure requiring continuous venovenous hemofiltration. On day 13 of ARDS the patient developed candidemia, which was treated with liposomal amphotericin. Despite a 2-week course of vancomycin, the patient's blood cultures remained positive for methicillin-resistant *Staphylococcus aureus*. He again developed septic shock that became refractory to escalating vasopressor therapy with norepinephrine, epinephrine, dopamine, and phenylephrine. After consultation with the patient's family, aggressive therapy was withdrawn and he died on day 17 of ARDS.

Discussion

We have reported a complicated case of severe sepsis-induced ARDS in which the administration and subsequent discontinuation of activated protein C coincided with a substantial fall and then a moderate rise in alveolar V_D . Prominent factors that possibly contributed to the fall in

ALVEOLAR DEAD-SPACE RESPONSE TO ACTIVATED PROTEIN C IN ARDS

Table 1. Pulmonary Gas Exchange and Mechanics During Treatment With Activated Protein C

	Before Activated Protein C Therapy	Hours After Start of Activated Protein C Therapy			
		2	19	45	70
V_D/V_T physiologic	0.55	0.61	0.50	0.27	0.34
V_D alveolar (mL)	165	149	107	11	71
V_D airway (mL)	152	164	144	125	104
V_T expired (mL)	577	513	501	506	514
V_T alveolar (mL)	260	200	251	369	336
\dot{V}_{CO_2} (mL/min)	261	258	292	317	294
PEEP (cm H ₂ O)	14	14	8	5	5
PEEP total (cm H ₂ O)	15	16	ND	6	5
P_{plat} (cm H ₂ O)	29	28	21	22	20
Mean P_{aw} (cm H ₂ O)	21	21	15	10	9
C_{RS} (mL/cm H ₂ O)	38	38	37	30	32
f (total breaths/min)	30	30	33	24	15
T_I (s)	0.63	0.47	0.43	0.58	0.86
\dot{V}_E (L/min)	17.3	15.4	16.8	12.3	7.7
P_{aCO_2} (mm Hg)	38	36	30	29	50
P_{ECO_2} (mm Hg)	17	14	15	21	33
Oxygenation index	13.1	23.1	8.2	5.1	5.2
P_{aO_2}/F_{IO_2} (mm Hg)	160	100	184	195	173

V_D = dead space volume

V_T = tidal volume

\dot{V}_{CO_2} = carbon dioxide excretion

PEEP = positive end-expiratory pressure

PEEP total = total PEEP at the alveolar level, measured during an end-expiratory pause and representing the absolute pressure

ND = no data available

P_{plat} = plateau pressure

P_{aw} = airway pressure

C_{RS} = compliance of the respiratory system

f = respiratory frequency

T_I = inspiratory time

\dot{V}_E = minute ventilation

P_{ECO_2} = mixed expired carbon dioxide partial pressure

F_{IO_2} = fraction of inspired oxygen

alveolar V_D include the effects of activated protein C on macro and microthromboemboli, as well as the effects of PEEP on alveolar recruitment and alveolar ventilation.

In regards to pulmonary vascular obstruction, it has long been recognized that embolization of both large and small pulmonary vessels is a prominent feature of severe ARDS.¹⁴⁻¹⁶ A wide variety of pulmonary vascular lesions have been described, and these tend to develop in stages.¹⁷ Relevant to our report, the first week of lung injury (the early exudative phase) is characterized by acute endothelial injury resulting in capillary engorgement and diffuse microthrombi. Tomashefski et al¹⁷ described 2 types of microthrombi: those found in the capillaries and small alveolar wall arteries, consisting of dense hyaline clots formed from platelets and fibrin; and those predominantly located in the small pre-acinar and large intra-acinar arteries. This is consistent with Vieillard-Baron's¹⁸ observation that in ARDS the site of pulmonary vascular obstruction tends to be focused in the distal vessels. Macrothrombi in the larger pulmonary arteries have been found in all

stages, but tend to be more prominent in the intermediate and later stages of ARDS.¹⁷

Nonetheless, the presence of a large thrombus in this patient's right renal vein and inferior vena cava complicates the pathophysiologic interpretation. Smaller thrombi generated from this source may have formed emboli in the larger pulmonary arteries. As computerized tomographic pulmonary angiography was not done in this patient, we cannot rule out the presence or relative contribution of pulmonary arterial macrothrombi to the elevation in alveolar V_D . However, when the initial dead-space measurements were made, the central venous pressure was 15 mm Hg while the total PEEP was 15–16 cm H₂O (12 mm Hg). The fact that this patient had an extrapulmonary source of ARDS, which typically is characterized by a higher degree of airway pressure transmission to the pleural space,¹⁹ along with a relatively high respiratory-system compliance (C_{RS}) of 38 mL/cm H₂O, suggests that central venous pressure reflected some degree of airway pressure transmission to the pleural space. If a substantial

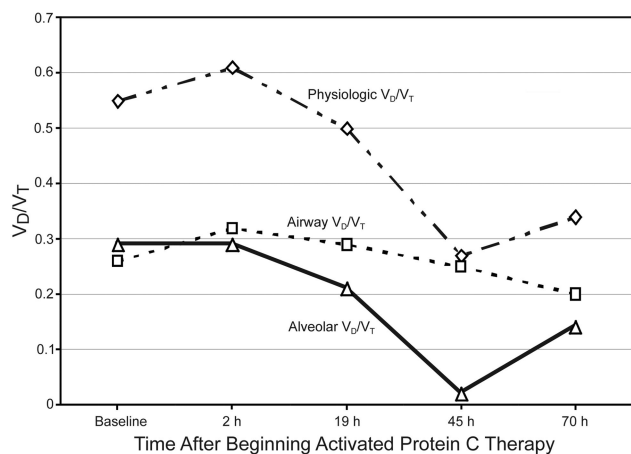


Fig. 2. Changes in physiologic dead-space fraction (V_D/V_T) and its sub-components, airway V_D/V_T and alveolar V_D/V_T , at 5 time points before, during, and after activated protein C therapy. The baseline measurement was just prior to initiation of activated protein C therapy. Both physiologic and alveolar V_D/V_T declined in tandem during therapy. Activated protein C was discontinued after 41 h because of bleeding. Approximately 29 h after activated protein C was stopped, alveolar V_D/V_T had increased from 0.02 to 0.14, but it never approached its initial value of 0.29. Also note that the initial increase in physiologic V_D/V_T after activated protein C therapy started was due to changes in airway V_D/V_T , probably attributable to a V_T decrease that was necessary to achieve the lung-protection target, as well as a radical reduction in inspiratory time (0.47 s), which limited gas diffusion.

pulmonary embolus had been present, central venous pressure probably would have been substantially higher than what was observed. Furthermore, a transesophageal echocardiography study done shortly after the onset of ARDS reported normal right-ventricle size and function, as well as the absence of systolic, interventricular septal flattening, which signifies right-ventricle pressure overload.²⁰ Therefore, we believe that microembolization in the pulmonary capillaries is the more likely source of pulmonary vascular obstruction in this patient.

Alveolar recruitment with PEEP can also affect V_D/V_T . In ARDS, alveolar V_D is inversely proportional to both PEEP and C_{RS} ,²¹ and is indicative of the contribution of intrapulmonary shunt to V_D/V_T .²² Therefore, PEEP titration over the time course of the dead-space measurements may have contributed to the observed changes in alveolar V_D . We were intrigued by the fact that alveolar V_T continued to increase despite decreased PEEP (from 14 cm H₂O to 5 cm H₂O) and a corresponding 21% decrement in C_{RS} (from 38 mL/cm H₂O to 30 mL/cm H₂O). This suggests that some degree of alveolar de-recruitment was also occurring. This finding further suggests that increased pulmonary perfusion may have been affected to a larger extent by decreased microvascular obstruction secondary to activated protein C therapy. The fact that alveolar V_D increased after discontinuation of activated protein C also

may reflect ongoing microvascular obstruction from an increasingly pro-coagulation state, relative to increasing shunt from alveolar de-recruitment, as PEEP and C_{RS} remained stable.

Although the patient had a very high minute-ventilation requirement, dynamic gas-trapping was not an important contributor to alveolar V_D , as the measured intrinsic PEEP was only 1–2 cm H₂O above applied PEEP and did not change substantially during the measurement period. The minor degree of intrinsic PEEP measured in this patient was consistent with values found in patients on lung-protective ventilation during the original ARDS Network study.²³

This complicated case of severe, sepsis-induced ARDS provides further indirect evidence that pulmonary vascular obstruction may be a substantial source of alveolar V_D contributing to elevated V_D/V_T . Treatment with activated protein C was associated with a rapid and almost complete elimination of alveolar V_D and a 142% increase in alveolar V_T . This marked decrease in alveolar V_D also has been observed when heparin is administered preoperatively to patients undergoing cardiac surgery, a situation known to cause inflammation and promote pulmonary microvascular thrombosis.²⁴ It is also consistent with the findings of substantial improvements in pulmonary perfusion observed within 48 h when streptokinase is administered to patients with severe ARDS.²⁵

However, the impressive response in alveolar V_D to activated protein C demonstrated in this case may be exaggerated somewhat by the fact that sepsis-induced ARDS apparently resulted from an extraordinarily large abdominal venous thrombi. Even though indirect signs of a substantial pulmonary embolus were absent in this case, we could not conclusively exclude the possibility. Thus, changes in alveolar V_D observed in this case may not be as pronounced in ARDS not associated with sepsis, and in particular septic emboli (eg, pneumonia, aspiration, or trauma).

This case also demonstrates the utility of volumetric capnography in the management of severe ARDS, particularly in the era of lung-protective ventilation. In general, V_D/V_T is largely independent of V_T in the range 8–13 mL/kg.²⁶ However, when V_T is adjusted to a sub-physiologic level, airway V_D assumes a relatively larger fraction of V_T . Under circumstances when severe reductions in inspiratory time are necessary to achieve elevated minute ventilation demand, as occurred in this case, both airway and alveolar V_D may increase as there is less time for alveolar gas diffusion and mixing.²⁷ This becomes more complicated during PEEP titration, as V_D/V_T decreases with lung recruitment, but rises again when pulmonary over-distention increases alveolar V_D .²¹

As illustrated in this complex case, attempting to implement lung-protective ventilation requires numerous ad-

justments to promote lung recruitment, maintain adequate acid-base balance, and minimize ventilator-associated lung injury. These adjustments often have divergent effects upon V_D/V_T and pulmonary gas exchange function. This can obfuscate the assessment of adjustments to mechanical ventilation, particularly in the context of hemodynamic instability. Having the ability to make sophisticated measurements of pulmonary function may assist in clinical decision making under such circumstances.

In summary, this case report provides indirect evidence supporting the hypothesis that activated protein C reduces V_D/V_T through decreased alveolar V_D by a reduction in pulmonary vascular microemboli. In addition, our report illustrates the utility of volumetric capnography in the management of patients with severe ARDS.

REFERENCES

1. Ware LB, Matthay MA. The acute respiratory distress syndrome. *N Engl J Med* 2000;342(18):1334-1349.
2. Kallet RH, Alonso JA, Pittet JF, Matthay MA. Prognostic value of the pulmonary dead-space fraction during the first six days of acute respiratory distress syndrome. *Respir Care* 2004;49(9):1008-1014.
3. Nuckton T, Alonso J, Kallet R, Daniel B, Pittet JP, Eisner M, Matthay MA. Early elevation in dead-space ventilation is associated with mortality risk in patients with acute respiratory distress syndrome. *N Engl J Med* 2002;346(17):1281-1286.
4. Esmon CT. The protein C anticoagulant pathway. *Arterioscler Thromb* 1992;12(1):35-45.
5. Murakami K, Okajima K, Uchiba M, Johno M, Nakagaki T, Okabe H, Takatsuki K. Activated protein C attenuates endotoxin-induced pulmonary vascular injury by inhibiting activated leukocytes in rats. *Blood* 1996;87(2):642-647.
6. Ware LB, Matthay MA, Parsons PE, Thompson PT, Januzzi JL, Eisner MD; National Heart, Lung, and Blood Institute ARDS Clinical Trials Network. Pathogenetic and prognostic significance of altered coagulation and fibrinolysis in acute lung injury/acute respiratory distress syndrome. *Crit Care Med* 2007;35(8):1821-1828.
7. Fourrier F, Chopin C, Goudemand J, Hendrycx S, Caron C, Rime A, et al. Septic shock, multiple organ failure, and disseminated intravascular coagulation: compare patterns of antithrombin III, protein C, and protein S deficiencies. *Chest* 1992;101(3):816-823.
8. Bernard GR, Vicent JL, Laterre PF, LaRosa SP, Dhainault JF, Lopez-Rodriguez A, et al; PROWESS Study Group. Efficacy and safety of recombinant human activated protein C for severe sepsis. *N Engl J Med* 2001;344(10):699-709.
9. Liu KD, Levitt J, Zhuo H, Kallet RH, Brady S, Steingrub J, et al. Randomized clinical trial of activated protein C for the treatment of acute lung injury. *Am J Respir Crit Care Med* 2008;178(6):618-623.
10. NHLBI Acute Respiratory Distress Syndrome Network. Ventilation with lower tidal volumes as compared with traditional tidal volumes for acute respiratory distress syndrome. *N Engl J Med* 2000; 342(18): 1301-1308.
11. Kallet RH, Daniel BM, Garcia O, Matthay MA. Accuracy of physiologic dead-space measurements in patients with acute respiratory distress syndrome using volumetric capnography: comparison with the metabolic monitor method. *Respir Care* 2005;50(4):462-467.
12. Enghoff H. Volumen inefficax: bemerkungen zur frage des schädlichen raumes. *Upsala Lakareforen Forh* 1938;44:191-218. *Article in German.*
13. Fletcher R, Jonson B, Cumming G, Brew J. The concept of dead-space with special reference to the single breath test for carbon dioxide. *Brit J Anaesth* 1981;53(1):77-88.
14. Zapol WM, Kobayashi K, Snider MT, Greene R, Laver MB. Vascular obstruction causes pulmonary hypertension in severe acute respiratory failure. *Chest* 1977;71(2 Suppl):306-307.
15. Greene R, Zapol WM, Snider MT, Reid L, Snow R, O'Connell RS, Novelline RA. Early bedside detection of pulmonary vascular occlusion during acute respiratory failure. *Am Rev Respir Dis* 1981; 124(5):593-601.
16. Zapol WM, Jones R. Vascular components of ARDS: clinical pulmonary, hemodynamics and morphology. *Am Rev Respir Dis* 1987; 136(2):471-474.
17. Tomashefski JF, Davies P, Boggis C, Greene R, Zapol WM, Reid LM. The pulmonary vascular lesions of adult respiratory distress syndrome. *Am J Pathol* 1983;112(1):112-126.
18. Vieillard-Baron A. Assessment of right ventricular function. *Curr Opin Crit Care* 2009;15(3):254-260.
19. Gattinoni L, Pelosi P, Suter PM, Pedoto A, Vercesi P, Lissoni A. Acute respiratory distress syndrome caused by pulmonary and extrapulmonary disease: different syndromes? *Am J Respir Crit Care Med* 1998;158(1):3-11.
20. Ahmed SN, Syed FM, Porembka DT. Echocardiographic evaluation of hemodynamic parameters. *Crit Care Med* 2007;35(8):S323-S329.
21. Suter PM, Fairley HB, Isenberg MD. Optimum end-expiratory airway pressure in patients with acute pulmonary failure. *N Engl J Med* 1975;292(6):284-289.
22. Kuwabara S, Duncalf D. Effect of anatomic shunt on physiologic deadspace-to-tidal volume ratio: a new equation. *Anesthesiology* 1969;31(6):575-577.
23. Hough CL, Kallet RH, Ranieri VM, Rubenfeld GD, Luce JM, Hudson LD. Intrinsic positive end-expiratory pressure in Acute Respiratory Distress Syndrome (ARDS) Network subjects. *Crit Care Med* 2005;33(3):527-532.
24. Dixon B, Campbell DJ, Santamaria JD. Elevated pulmonary dead space and coagulation abnormalities suggesting lung microvascular thrombosis in patients undergoing cardiac surgery. *Intensive Care Med* 2008;34(7):1216-1223.
25. Greene R, Lind S, Jantsch H, Wilson R, Lynch K, Jones R, et al. Pulmonary vascular obstruction in severe ARDS: angiographic alterations after fibrinolytic therapy. *AJR Am J Roentgenol* 1987; 148(3):501-508.
26. Kiiski R, Takala J, Kari A, Milic-Emili J. Effect of tidal volume on gas exchange and oxygen transport in the adult respiratory distress syndrome. *Am Rev Respir Dis* 1992;146(5 Pt 1):1131-1135.
27. Anderson JT. Embolism. In: Gravenstein JS, Jaffee MB, Paulus DA, editors. *Capnography: clinical aspects*. Cambridge: Cambridge University Press; 2004:187-198.