

# Diagnostic Yield and Safety of Cryoprobe Transbronchial Lung Biopsy in Diffuse Parenchymal Lung Diseases: Systematic Review and Meta-Analysis

Sahajal Dhooria MD DM, Inderpaul Singh Sehgal MD DM, Ashutosh N Aggarwal MD DM, Digambar Behera MD, and Ritesh Agarwal MD DM

**BACKGROUND:** Transbronchial lung biopsy with flexible forceps is the most commonly used technique in diagnosis of diseases diffusely involving the lung parenchyma. Recently, transbronchial lung biopsy using the flexible cryoprobe (cryo-transbronchial lung biopsy) has also been reported. Herein, we perform a systematic review and meta-analysis describing the efficacy and safety of cryo-transbronchial lung biopsy. **METHODS:** The PubMed and EMBASE databases were searched for studies reporting the outcomes of cryo-transbronchial lung biopsy in subjects with diffuse parenchymal lung involvement. The quality of individual studies was assessed using the QualSyst tool. The pooled diagnostic yield of cryo-transbronchial lung biopsy was calculated using proportion meta-analysis (random effects model). Heterogeneity was evaluated using the  $I^2$  test and Cochran Q test. Publication bias was determined using both statistical and graphical methods. **RESULTS:** Our search yielded 14 studies (1,183 subjects). The pooled diagnostic yield of cryo-transbronchial lung biopsy was 76.9% (95% CI 67.2–85.3) if only definitive diagnoses were considered and 85.9% (95% CI 78.2–92.2) if both definitive and probable diagnoses were considered. Four studies (321 subjects) the performance of flexible forceps biopsy and cryo-transbronchial lung biopsy. The diagnostic yield of cryo-transbronchial lung biopsy (86.3, 95% CI 80.2–90.8) was significantly higher than that of flexible forceps biopsy (56.5%, 95% CI 27.5–83.2) with an odds ratio of 6.7 (95% CI 3.6–12.4) and a number needed to treat of 4. Lung tissue was obtained in 98% of all samples with cryo-transbronchial lung biopsy and was free of compression artifacts. The size of samples obtained with cryo-transbronchial lung biopsy was significantly bigger compared with flexible forceps biopsy (20.4 vs 4.3 mm<sup>2</sup>,  $P = .005$ ). The complications of cryo-transbronchial lung biopsy included pneumothorax (6.8%), severe bleeding (0.3%), and death (0.1%). Clinical and statistical heterogeneity was present, and there was evidence of publication bias. **CONCLUSIONS:** Cryo-transbronchial lung biopsy is a relatively safe procedure with good diagnostic yield in diseases diffusely involving the lung parenchyma. *Key words:* cryotherapy; interstitial lung disease; idiopathic pulmonary fibrosis; idiopathic interstitial pneumonia; sarcoidosis; bronchoscopy. [Respir Care 2016;61(5):700–712. © 2016 Daedalus Enterprises]

## Introduction

Diffuse parenchymal lung diseases are a heterogeneous group of disorders that affect the pulmonary parenchyma

and include sarcoidosis, connective tissue disease-associated interstitial lung diseases, occupational lung diseases, idiopathic interstitial pneumonias, and others.<sup>1,2</sup> Certain

---

The authors are affiliated with the Department of Pulmonary Medicine, Postgraduate Institute of Medical Education and Research, Chandigarh, India.

---

Correspondence: Ritesh Agarwal MD DM, Department of Pulmonary Medicine, Postgraduate Institute of Medical Education and Research, Sector-12, Chandigarh 160012, India. E-mail: agarwal.ritesh@outlook.in.

The authors have disclosed no conflicts of interest.

DOI: 10.4187/respcare.04488

infections, such as cytomegalovirus pneumonia, and post lung transplant conditions, such as acute rejection, diffusely involve the lung parenchyma and mimic other diffuse parenchymal lung diseases on radiologic evaluation.<sup>3,4</sup>

Transbronchial lung biopsy, performed with flexible forceps during flexible bronchoscopy, has been the most commonly employed technique for obtaining lung tissue for histopathological examination in diffuse parenchymal lung diseases.<sup>5,6</sup> Flexible forceps biopsy is minimally invasive and does not require general anesthesia, thereby allowing the procedure to be performed on a day-care basis.<sup>7</sup> However, it has significant limitations, including a variable diagnostic yield ranging from 30 to 75% (depending on the underlying disorders). It has an especially lower yield in fibrotic diffuse parenchymal lung diseases, such as idiopathic pulmonary fibrosis (IPF) and nonspecific interstitial pneumonia.<sup>6,8-10</sup> Further, the size of the lung tissue specimen obtained with flexible forceps biopsy is small and frequently associated with artifacts (especially compression or crush artifacts), thus limiting its diagnostic utility.<sup>11,12</sup> For this reason, flexible forceps biopsy is not recommended for the diagnosis of diffuse parenchymal lung diseases, such as IPF.<sup>13</sup> Besides, the procedure is not without risk; pneumothorax and airway bleeding are important complications that might occur with flexible forceps biopsy and may result in hypoxia, ICU admissions, and prolonged hospital stay.<sup>7,14,15</sup>

Surgical lung biopsy provides large tissue samples for histopathological analysis and is the current reference standard for the diagnosis of idiopathic interstitial pneumonias, such as IPF, nonspecific interstitial pneumonia, and others.<sup>16</sup> However, the procedure is performed in the operating room under general anesthesia and requires the mandatory insertion of an intercostal drain. It may be associated with significant morbidity (2–20%), including prolonged air leak and prolonged hospital admission, and mortality (2–17%).<sup>17-23</sup>

Transbronchial lung biopsy can also be performed using cryoprobes, termed cryo-transbronchial lung biopsy.<sup>24</sup> Cryotherapy works on the principle of the Joule-Thomson effect, wherein the adiabatic expansion of a compressed gas leads to rapid cooling. The cooled tip of the cryoprobe adheres to the tissue due to crystallization of water molecules at the interface. Cryoprobes have been traditionally used during bronchoscopy for endobronchial tumor ablation, endobronchial biopsy, and recanalization by extraction of tumors and/or blood clots<sup>25,26</sup>; their use for performing transbronchial lung biopsy is relatively recent.<sup>27</sup> Herein, we perform a systematic review and meta-analysis of studies investigating the yield and safety of cryoprobe for performing cryo-transbronchial lung biopsy in subjects with disorders diffusely involving the lung parenchyma.

## QUICK LOOK

### Current knowledge

Transbronchial lung biopsy with flexible forceps and surgical lung biopsy are commonly used modalities in the diagnosis of diseases diffusely involving the lung parenchyma. Recently, transbronchial lung biopsy using the flexible cryoprobe (cryo-transbronchial lung biopsy) has also been reported.

### What this paper contributes to our knowledge

The results of this study suggest that cryo-transbronchial lung biopsy has a good diagnostic yield in diseases diffusely involving the lung parenchyma with an acceptable safety profile.

## Methods

### Search Strategy

We first confirmed the absence of any systematic review in the PubMed and EMBASE databases on the role of cryo-transbronchial lung biopsy in diffuse lung diseases. Subsequently, all of the authors performed an independent search of the PubMed and EMBASE databases for relevant studies published through August 2015 describing the use of a cryoprobe for performing transbronchial lung biopsy in subjects with diseases diffusely involving the lung parenchyma. The following free text search terms were utilized: (cryo OR cryobiopsy OR cryobiopsies OR cryoprobe OR cryotherapy OR cryotechnology) AND (lung biopsy OR transbronchial OR trans-bronchial OR lung biopsies). The list of references of original, editorials, reviews, and our personal files were also checked for relevant citations. We excluded the following: (1) case reports, abstracts, comments, editorials, and reviews; (2) studies describing cryo-transbronchial lung biopsy in <10 subjects; (3) studies describing the use of cryo-transbronchial lung biopsy for a localized lung lesion; and (4) studies that could possibly have overlap of data with another study from the same center.

### Initial Review of Studies

The bibliographic list thus retrieved from the electronic and manual searches was imported into the reference manager package, and all duplicate citations were discarded. Two authors (SD and RA) scrutinized these citations by examination of the title and abstract to identify the relevant studies. Any disagreement was resolved by discussion between the authors. This database was then screened

again to include only primary articles. The full text of each of these studies was obtained and reviewed in detail.

### Data Abstraction

Data were entered into a standard data extraction form. The following items were extracted: (1) publication details (authors, year of publication, and other citation particulars, including the country of origin); (2) study design (prospective or retrospective); (3) patient population, number of subjects, and the comparator; (4) details of the procedure (anesthetic agents used and depth of anesthesia, use of rigid bronchoscopy or endotracheal intubation, the cryoprobe and cryogen used, duration of cooling, and duration of procedure); (5) characteristics of biopsy specimens (number, surface area, presence of lung tissue and alveolar spaces, presence of artifacts, and use of digital morphometry); (6) diagnostic characteristics (diagnostic yield, specific diagnoses, and diagnostic gold standard); and (7) complications associated with the procedure (severe bleeding defined according to British Thoracic Society guidelines,<sup>7</sup> pneumothorax, and death). Complications were attributed to cryobiopsy for studies in which cryobiopsy and flexible forceps biopsy were performed in the same subject.

### Assessment of Study Quality

Each study included in this review was adjudged for its quality and validity using the QualSyst tool for qualitative studies<sup>28</sup> independently by 2 authors (SD and RA) for the stated criteria. Weighted Cohen's kappa co-efficient was used to define the inter-observer agreement for selection of studies.

### Statistical Analysis

The statistical software package StatsDirect 2.8.0 (StatsDirect Ltd, Altrincham, UK) was used to perform the statistical analyses. The diagnostic yield of cryo-transbronchial lung biopsy was analyzed by calculating the proportions for the individual studies ( $n/N$ , where  $n$  is the number diagnosed with the help of cryo-transbronchial lung biopsy, and  $N$  is the total number of subjects evaluated).<sup>29,30</sup> The proportions were pooled using a DerSimonian random effects model in the presence of significant heterogeneity. The odds ratio and 95% CIs were calculated to assess the diagnostic yield in the cryo-transbronchial lung biopsy versus the flexible forceps biopsy group. The results from individual studies were pooled using the random effects model.<sup>31</sup> The number needed to treat (equal to 1/risk difference) was calculated to estimate the number of cryo-transbronchial lung biopsy procedures that need to be

performed to achieve one additional diagnosis compared with flexible forceps biopsy.

### Assessment of Heterogeneity

Heterogeneity for the individual outcomes was assessed using the  $I^2$  test, which measures the extent of inconsistency among the results of the studies. An  $I^2$  value of  $\geq 50\%$  indicates significant heterogeneity.<sup>32</sup> Heterogeneity was also assessed using the Cochran Q statistic, and a  $P$  value of  $<.1$  was considered to be significant.<sup>33</sup>

### Estimation of Publication Bias

The presence of publication bias was evaluated using the funnel plot (proportion on x axis against the standard error of the proportion on the y axis).<sup>34</sup> Publication bias was also investigated using the Egger test<sup>35</sup> and Begg-Mazumdar test.<sup>36</sup> An ethics committee approval was not required because this was a systematic review of published studies.

## Results

The initial database search retrieved a total of 393 citations, of which 14 studies (1,183 subjects in total, 805 undergoing cryobiopsy) finally met the inclusion criteria (Fig. 1).<sup>27,37-49</sup> Nine studies were retrospective,<sup>27,38-40,43,44,46-48</sup> whereas 5 studies were prospective (4 observational,<sup>37,41,42,49</sup> one randomized trial<sup>45</sup>) (Table 1). Ten studies were conducted in subjects with diffuse lung disease,<sup>27,37,40,42-45,47-49</sup> 2 in lung transplant recipients,<sup>39,41</sup> one in immunocompromised subjects with pulmonary infiltrates,<sup>38</sup> and one including subjects from all 3 categories<sup>46</sup> (Table 1). The studies were generally of good quality (Table 2), with the median (interquartile range) QualSyst score being 18 (17-19). The inter-observer agreement for scoring of study quality was good (weighted Cohen's kappa = 70.3%). Flexible forceps biopsy was the comparator in 6 studies, whereas cryobiopsy was compared against surgical lung biopsy in one study.

The procedures were performed most commonly under conscious sedation in spontaneously breathing subjects (11 studies); in one study, general anesthesia was employed, whereas in 2 other studies, either of the 2 modalities were used (Table 3). Midazolam with alfentanil (4 studies) and propofol with remifentanil (4 studies) were the most commonly used combinations of sedative/anesthetic and analgesic agents (Table 3). The subjects were intubated with one of the following artificial airways namely the endotracheal tube (6 studies), rigid bronchoscope (3 studies), or laryngeal mask airway (1 study). In 4 studies, the procedure was per-

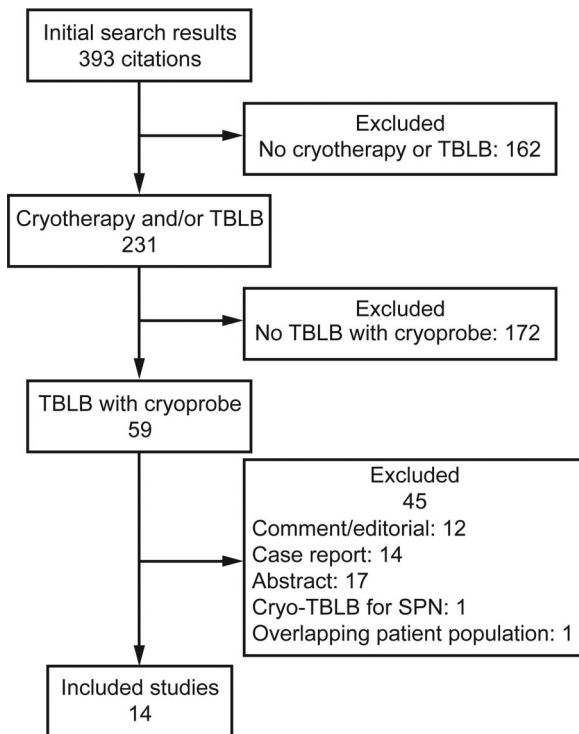


Fig. 1. Flow chart. TBLB = transbronchial lung biopsy; SPN = solitary pulmonary nodules.

formed without endotracheal intubation (Table 3). The procedures were performed through a flexible bronchoscope under fluoroscopic guidance in all of the studies. A 2.4-mm cryoprobe was used in a majority of the studies (9 studies), with nitrous oxide as the cryogen (8 studies) and a cooling time ranging from 3 to 6 s (Table 3). The mean duration of the procedure was reported in 6 studies and ranged from 6 to 35 min (Table 3). In most studies, 2–3 cryobiopsy samples were obtained; in one study each, the number was 5 and up to 6, respectively (Table 4). A chest radiograph was performed after the procedure in all of the studies. Digital morphometry was performed in 3 studies.<sup>27,43,44</sup> The mean surface area of the biopsy samples was significantly higher with the cryoprobe in comparison with flexible forceps (20.4 vs 4.3 mm<sup>2</sup>,  $P = .005$ ). Lung tissue was obtained in 391 of the 399 (98%) cryobiopsy cases in which it was reported (Table 4). The number of alveolar spaces or percentage alveolated area as well as the artifact-free area was higher with the cryoprobe than with flexible forceps biopsy (Table 4). Artifacts associated with the use of the cryoprobe included cold-related artifacts, acute lung injury changes, and the presence of ciliated columnar epithelium in alveolar spaces.<sup>42,49</sup> Nine studies explicitly defined a diagnostic reference standard (Table 5), which included: (1) interdisciplinary discussion between clinician, radiologist, and pathologist (5 studies); (2) clinical,

radiographic, and pathological findings with 6-month follow-up (one study); and (3) clinical, radiographic, and pathological findings (3 studies).<sup>27,38,40,43-45,47-49</sup> A variety of diffuse parenchymal lung diseases, including IPF and nonspecific interstitial pneumonia, could be diagnosed with the help of cryo-transbronchial lung biopsy (Table 5).

### Diagnostic Yield of Cryo-Transbronchial Lung Biopsy

Twelve studies (472 subjects) reported the diagnostic yield of cryo-transbronchial lung biopsy (Table 5).<sup>27,37-40,42-45,47-49</sup> Five studies further classified the diagnoses achieved with the help of cryo-transbronchial lung biopsy as definite (or confident) or probable.<sup>42,43,47-49</sup> The diagnoses achieved in the remaining 7 studies were considered definite.<sup>27,37-40,44,45</sup> The pooled diagnostic yield was 76.9% (95% CI 67.2–85.3) if only the definite diagnoses were considered, whereas it was 85.9% (95% CI 78.2–92.2) when both definite and probable diagnoses were considered (Fig. 2). Four (3 observational, one randomized) studies (Table 6) compared the diagnostic yield of cryobiopsy (161 subjects) with flexible forceps biopsy (160 subjects). The diagnostic yield was significantly higher with cryo-transbronchial lung biopsy (86.3%, 95% CI 80.2–90.8%) compared with flexible forceps biopsy (56.5%, 95% CI 27.5–83.2%) with an odds ratio of 6.7 (95% CI 3.6–12.4%), and a number needed to treat of 4 (Fig. 3).

### Safety of Cryo-Transbronchial Lung Biopsy

Complications were reported by 13 studies for 764 cryo-transbronchial lung biopsy procedures. Overall, there were 55 (7.2%) major complications. Pneumothorax occurred in 52 (6.8%), severe bleeding in 2 (0.3%), and death in one (0.1%) case (Table 7). The highest rate of pneumothorax (28%) was observed in the study performed in subjects with fibrotic diffuse parenchymal lung diseases.<sup>42</sup> The only death was also reported in the same study and was caused by an exacerbation of IPF.<sup>42</sup>

Clinical heterogeneity was evident in the nature of the studies (prospective vs retrospective), patient population, and diagnostic gold standards (Tables 1 and 5). Significant statistical heterogeneity was also observed for the outcome of diagnostic yield of the procedure ( $I^2 = 79.6$ ; Cochran Q statistic 53.9,  $P < .001$ ). There was evidence of publication bias on visual examination of the funnel plot (Fig. 4) and on statistical tests (Begg-Mazumdar: Kendall's tau =  $-0.545$ ,  $P = .009$ ; Egger: bias =  $-3.577$ ,  $P < .001$ ).

### Discussion

The results of this study indicate that cryo-transbronchial lung biopsy has a good diagnostic yield (86%), higher

CRYOPROBE TRANSBRONCHIAL LUNG BIOPSY IN DIFFUSE LUNG DISEASES

Table 1. Characteristics of the Included Studies

Author (Year)	Country	Design	Subjects, <i>N</i> (Subjects Who Underwent Cryo-TBLB, <i>n</i> )	Patient Population	Comparator
Babiak et al (2009) <sup>27</sup>	Germany	Retrospective	41 (41)	Diffuse lung disease on chest CT	FFB
Pajares et al (2010) <sup>37</sup>	Spain	Prospective	10 (10)	Diffuse lung disease	None
Fruchter et al (2013) <sup>38</sup>	Israel	Retrospective	80 (40)	Lung transplant subjects undergoing bronchoscopy (either surveillance or clinically indicated)	FFB
Fruchter et al (2013) <sup>39</sup>	Israel	Retrospective	15 (15)	Immunocompromised subjects with pulmonary infiltrates	None
Kropski et al (2013) <sup>40</sup>	United States	Retrospective	37 (37)	Suspected ILD with requirement of lung biopsy, asymptomatic family members at risk for FIP	None
Yarmus et al (2013) <sup>41</sup>	United States	Prospective	17 (21)*	Bilateral lung transplant subjects undergoing surveillance bronchoscopy	FFB
Casoni et al (2014) <sup>42</sup>	Italy	Prospective	73 (69)	Clinical and radiologic features of fibrotic DPLD (insufficient to achieve a specific diagnosis)	None
Fruchter et al (2014) <sup>43</sup>	Israel	Retrospective	75 (75)	Clinical, physiological and radiographic features of undiagnosed ILD	None
Griff et al (2014) <sup>44</sup>	Germany	Retrospective	52 (52)	Diffuse interstitial non-neoplastic lung diseases	None
Pajares et al (2014) <sup>45</sup>	Spain	Prospective, randomized	77 (39)	Clinical and radiologic features of ILD	FFB
Gershman et al (2015) <sup>46</sup>	Israel	Retrospective	600 (300)	Immunocompromised subjects with pulmonary infiltrates, lung transplant subjects, subjects with diffuse lung diseases	FFB
Hagmeyer et al (2015) <sup>47</sup>	Germany	Retrospective	32 (32)	Suspected ILD with equivocal diagnosis on clinical features, serology, HRCT and BAL	SLB
Hernández-González et al (2015) <sup>48</sup>	Spain	Retrospective	33 (33)	ILD pattern on HRCT defined as “possible UIP” or “inconsistent with UIP”	None
Pourabdollah et al (2015) <sup>49</sup>	Iran	Prospective	41 (41)	Diffuse lung disease	FFB

\* Twenty-one procedures were performed in 17 subjects.  
TBLB = transbronchial lung biopsy  
CT = computed tomography  
FFB = flexible forceps biopsy  
ILD = interstitial lung disease  
FIP = familial interstitial pneumonia  
DPLD = diffuse parenchymal lung disease  
BAL = bronchoalveolar lavage  
SLB = surgical lung biopsy  
HRCT = high-resolution computed tomography  
UIP = usual interstitial pneumonia

than that of flexible forceps biopsy (57%), for obtaining transbronchial lung biopsies in subjects who have diffuse parenchymal lung involvement. In fact, only 4 procedures need to be performed with cryo-transbronchial lung biopsy to obtain one additional diagnosis, compared with flexible forceps biopsy. The cryo-transbronchial lung biopsy procedure is generally safe, associated with a small risk of pneumothorax (6.8%) and a very small risk of severe bleeding (0.3%) and death (0.1%).

The high yield of cryo-transbronchial lung biopsy can be attributed to several factors, including the presence of

lung tissue in the biopsy specimen in almost all (98%) cases, large size of the samples, and the absence of significant artifacts. When the cryoprobe is placed deep inside a sub-segmental bronchus and activated for 3–4 s, the lung parenchymal tissue freezes around the probe and adheres to the probe tip. Subsequent traction of the probe allows shearing off of a large volume of the lung parenchyma during withdrawal of the probe. This is unlike the flexible forceps biopsy technique, where the jaws of the forceps grasp the parenchyma, with the potential of causing compression/crush artifacts. The surface area of the

Table 2. QualSyst Tool for Assessment of Quality of the Included Studies

Criteria	Babiak et al <sup>27</sup>	Pajares et al <sup>37</sup>	Fruchter et al <sup>38</sup>	Fruchter et al <sup>39</sup>	Kropski et al <sup>40</sup>	Yarmus et al <sup>41</sup>	Casoni et al <sup>42</sup>	Fruchter et al <sup>43</sup>	Griff et al <sup>44</sup>	Pajares et al <sup>45</sup>	Gershman et al <sup>46</sup>	Hagmeyer et al <sup>47</sup>	Hernández-González et al <sup>48</sup>	Pourabdollah et al <sup>49</sup>
1. Question/objective sufficiently described?	2	2	2	2	2	2	2	2	2	2	2	2	2	2
2. Study design evident and appropriate?	1	2	1	1	1	2	2	1	2	2	2	1	1	2
3. Context for the study clear?	2	2	2	2	2	2	2	2	2	2	2	2	2	2
4. Connection to a theoretical framework/wider body of knowledge?	2	2	2	2	2	2	2	2	2	2	2	2	2	2
5. Sampling strategy described, relevant, and justified?	1	2	2	2	2	2	2	2	1	2	2	1	2	1
6. Data collection methods clearly described and systematic?	1	2	1	2	2	2	2	1	2	2	2	2	2	2
7. Data analysis clearly described and systematic?	2	1	1	2	2	1	2	2	2	2	2	1	2	2
8. Use of verification procedure(s) to establish credibility?	1	1	1	1	2	1	2	2	2	2	1	2	2	1
9. Conclusions supported by the results?	2	1	2	2	2	2	2	2	2	2	2	2	2	2
10. Reflexivity of the account?	2	2	2	2	2	2	2	1	2	2	1	2	2	2
Total	16	17	16	18	19	18	20	17	19	20	18	17	19	18

cryobiopsy specimen was higher than the flexible forceps biopsy samples by almost 5 times, and these larger samples with sufficient vascular and bronchiolar tissue help in a confident histological diagnosis of the subtype of the fibrotic diffuse parenchymal lung diseases as well as exclusion of cellular rejection and bronchiolitis in the lung transplant population.<sup>39</sup>

Although transbronchial flexible forceps biopsy provides a good diagnostic sensitivity in diseases like sarcoidosis, organizing pneumonia, lymphangitis carcinomatosa, and infections, the yield is poor in case of interstitial lung diseases, such as IPF, nonspecific interstitial pneumonia, respiratory bronchiolitis-associated interstitial lung disease, and others.<sup>9,10,50-52</sup> This is due to the requirement of larger sized lung tissue for differentiating IPF from hypersensitivity pneumonitis and nonspecific interstitial pneumonia, as the former requires the demonstration of temporal and spatial heterogeneity.<sup>13</sup> Further, other features like patchy interstitial fibrosis, fibroblast foci, and honeycombing need to be identified.<sup>13</sup> A large variety of diffuse parenchymal lung diseases, which are difficult to be diagnosed confidently on small flexible forceps biopsy samples were diagnosed with cryo-transbronchial lung biopsy in the included studies (including IPF, nonspecific interstitial pneumonia, desquamative interstitial pneumonia, pulmonary Langerhans cell histiocytosis, and hypersensitivity pneumonitis), thus emphasizing the utility of this novel technique.

The present analysis also highlights the relative safety of the cryo-transbronchial lung biopsy procedure. The larger defect in the lung parenchyma resulting from a cryo-transbronchial lung biopsy is expected to increase the risk of pneumothorax significantly as compared with flexible forceps biopsy. The incidence of pneumothorax was 6.8% (52 of 764), which is higher than the usual reported rate reported with the flexible forceps biopsy.<sup>7,14,15,53,54</sup> However, the risk of pneumothorax is less than that would be expected, considering the larger biopsy tissues obtained with cryo-transbronchial lung biopsy. The possible reasons include the universal use of fluoroscopy while performing cryo-transbronchial lung biopsy and fewer samples required for diagnosis with cryo-transbronchial lung biopsy. Moreover, one third of the pneumothoraces (19 of 52) in the present review occurred in a single study conducted in fibrotic diffuse parenchymal lung diseases. The authors of this study have attributed the high incidence (28% in that study) to the type of patient population and the necessity to biopsy subpleural areas. Thus, the risk of pneumothorax with cryo-transbronchial lung biopsy is acceptable in most patients. Importantly, this needs to be interpreted in light of the fact that only a proportion of the patients (maximum 28%)<sup>42</sup> would require an intercostal drain with cryo-transbronchial lung biopsy, compared with 100% patients who undergo surgical lung biopsy.

Severe bleeding (requiring either cessation of the procedure or the use of a bronchial blocker/sealant or surgical

Table 3. Details of the Cryo-Transbronchial Lung Biopsy Procedure

Author (Year)	Anesthetic Agents	Depth of Anesthesia	Intubation	Cryoprobe Diameter (mm)	Cryogen	Duration of Cooling (s)	Duration of Procedure (min)
Babiak et al (2009) <sup>27</sup>	Propofol	Deep sedation, spontaneous breathing	ETT	2.4	Nitrous oxide	4	26 (19–42)
Pajares et al (2010) <sup>37</sup>	Propofol, remifentanyl	Sedation, spontaneous breathing	ETT	2.4	Nitrous oxide	3	35 ± 11
Fruchter et al (2013) <sup>38</sup>	Midazolam, alfentanil	Conscious sedation, spontaneous breathing	Not done	2.4	Nitrous oxide	4	CB: 8, FFB: 5
Fruchter et al (2013) <sup>39</sup>	Midazolam, alfentanil	Conscious sedation, spontaneous breathing	Not done	2.4	Nitrous oxide	4	CB: 6 (4–15)
Kropski et al (2013) <sup>40</sup>	NR	Conscious sedation, spontaneous breathing	ETT	1.9	NR	4	NR
Yarmus et al (2013) <sup>41</sup>	Propofol, paralytics	Deep sedation and jet ventilation in 10 subjects, spontaneous breathing in 11	RB: 10, LMA: 11	1.8	NR	3	NR
Casoni et al (2014) <sup>42</sup>	Propofol, remifentanyl	Deep sedation, spontaneous breathing	RB	2.4	Carbon dioxide	5–6	NR
Fruchter et al (2014) <sup>43</sup>	Midazolam, alfentanil	Conscious sedation, spontaneous breathing	Not done	2.4	Nitrous oxide	4	7 (5–13)
Griff et al (2014) <sup>44</sup>	Midazolam or disoprivan	Conscious sedation, spontaneous breathing	NR	1.9	Carbon dioxide	3–5	NR
Pajares et al (2014) <sup>45</sup>	Midazolam, propofol, remifentanyl	Conscious sedation, spontaneous breathing	ETT	2.4	NR	3–4	CB: 30.5 ± 7.6, FFB: 32.5 ± 8.6
Gershman et al (2015) <sup>46</sup>	Midazolam, alfentanil, propofol	Conscious sedation, spontaneous breathing	Not done	2.4	Nitrous oxide	4	NR
Hagemeyer et al (2015) <sup>47</sup>	General anesthesia or midazolam and disoprivan	General anesthesia with jet ventilation in 7 subjects, conscious sedation in 25	RB/ETT	NR	Nitrous oxide	4–5	NR
Hernández-González et al (2015) <sup>48</sup>	Propofol, remifentanyl	General anesthesia, mechanical ventilation	ETT	1.9	NR	3–4	NR
Pourabdollah et al (2015) <sup>49</sup>	NR	Conscious sedation, spontaneous breathing	NR	2.4	Nitrous oxide	3	NR

All values are mean ±SD or mean (range).  
 ETT = endotracheal tube  
 CB = cryobiopsy  
 FFB = flexible forceps biopsy  
 NR = not reported  
 RB = rigid bronchoscopy  
 LMA = laryngeal mask airway

Table 4. Characteristics of Transbronchial Lung Biopsies Obtained in the Included Studies

Author (Year)	Digital Morphometry	No. of Biopsies/Subject	Surface Area of Biopsies (mm <sup>2</sup> )	Lung Tissue	No. of Alveolar Spaces or Percent Alveolated Area	Artifacts
Babiak et al (2009) <sup>27</sup>	Performed	CB: 1-8, FFB: 2	CB: 15.11 (2.15–54.15), FFB: 5.82 (0.58–20.88)	CB: 41/41	NR	None
Pajares et al (2010) <sup>37</sup>	NR	2	9.5 (3–25)	10/10	29.6 (3–100)	≥75% artifact-free tissue: 12 samples
Fruchter et al (2013) <sup>38</sup>	NR	CB: 2–3, FFB: 6–8	CB: 10 (5–20.1), FFB: 2 (0.5–4)	CB: 40/40	CB: 65% (20–85%), FFB: 34% (10–55%)	CB: none
Fruchter et al (2013) <sup>39</sup>	NR	2–3	9 (6–13)	15/15	70% (25–85%)	None
Kropski et al (2013) <sup>40</sup>	NR	2	64.2 (1.5–136.7)	24/25	NR	NR
Yarmus et al (2013) <sup>41</sup>	NR	CB: 5, FFB: 10	Significantly higher with CB	Significantly higher with CB		CB: no artifacts, FFB: all had crush artifacts
Casoni et al (2014) <sup>42</sup>	NR	3 (1–6)	43.11 (11.94–76.25)	68/69	NR	No crush artifacts; cold-related artifacts in 40 cases
Fruchter et al (2014) <sup>43</sup>	Performed	3 (2–4)	9 (6–18)	75/75	70% (55–85%)	None
Griff et al (2014) <sup>44</sup>	Performed	1–2	6.9 (2–22)	48/52	NR	NR
Pajares et al (2014) <sup>45</sup>	NR	CB: 3.7 ± 0.9, FFB: 3.5 ± 1.2	CB: 14.7 ± 11, FFB: 3.3 ± 4.1	39/39	CB: 68.2 ± 61.2, FFB: 22 ± 39.8	≥75% artifact-free tissue as percentage of total area; CB: 66.6%, FFB: 31.6%
Gershman et al (2015) <sup>46</sup>	Not performed	CB: 2–4, FFB: NR	NR	NR	NR	NR
Hagmeyer et al (2015) <sup>47</sup>	NR	2–4	NR	NR	NR	NR
Hernández-González et al (2015) <sup>48</sup>	NR	2.7 (0–5)	NR	31/33	NR	None
Pourabdollah et al (2015) <sup>49</sup>	Not performed	CB: 1, FFB: 3–4	CB: 22 ± 19.1, FFB: 6 ± 6.7	NR	>50 alveolar spaces; CB: 40/41, FFB: 26/41	75% artifact-free; CB: 22/41; CCE artifact*; FFB: 10/41

All values are mean ± SD or mean (range).  
 \* Presence of ciliated columnar epithelium in alveolar spaces.  
 CB = cryobiopsy  
 FFB = flexible forceps biopsy  
 NR = not reported  
 CCE = ciliated columnar epithelium



CRYOPROBE TRANSBRONCHIAL LUNG BIOPSY IN DIFFUSE LUNG DISEASES

Table 5. Diagnostic Characteristics in the Included Studies

Author (Year)	Diagnostic Accepted Standard	Diseases Diagnosed on Cryo-TBLB (n)	Diagnostic Yield*
Babiak et al (2009) <sup>27</sup>	Clinical, radiographic, and pathological findings with 6-month follow-up	IPF (15), NSIP (10), DIP (3), PLCH (1), HP (3), sarcoidosis (6), DILD (1)	CB: 39/41, FFB: 24/41
Pajares et al (2010) <sup>37</sup>	NR	IPF (3), NSIP (2)	5/10
Fruchter et al (2013) <sup>38</sup>	NR	Acute cellular rejection (4), DAD (1), pneumonitis (3), normal (32)	CB: 40/40, FFB: 37/40
Fruchter et al (2013) <sup>39</sup>	Clinical, radiographic, and pathological findings	Fibrotic NSIP (1), DAD (3), OP (3), noncaseating GI-2, drug-induced acute interstitial pneumonitis (5), cryptococcal pneumonia (1)	12/15
Kropski et al (2013) <sup>40</sup>	Clinical, radiographic, and pathological findings	UIP/IPF (7), COP (2), RBILD/DIP (2), HP (1), malignancy (2), drug-induced (2), ConB (1), BO (1), normal (1)	20/25
Yarmus et al (2013) <sup>41</sup>	None	NR	NR
Casoni et al (2014) <sup>42</sup>	NR	UIP (47), NSIP (9; 6 fibrosing, 3 cellular), DIP/RBILD (2), OP (1), EP (1), DAD (1), HP (1), FB (1)	Definite: 52/69, definite/probable: 63/69
Fruchter et al (2014) <sup>43</sup>	Interdisciplinary discussion-clinical, pathologic, radiologic	UIP (7), NSIP (22), COP (11), PLCH (3), LAM (1), DIP (1), HP (1), EP (1), LC (1), sarcoidosis (1), lipoid pneumonia (1), PAP (1), silicosis (1)	Definite: 52/75, definite/probable: 73/75
Griff et al (2014) <sup>44</sup>	Interdisciplinary discussion: clinical, pathologic, radiologic	IPF (9), NSIP (1), COP (8), HP (6), DILD (2), rheumatoid lung disease (2), sarcoidosis (10), alveolar microlithiasis (1), pulmonary manifestation of scleroderma (1), histiocytosis (1)	41/52
Pajares et al (2014) <sup>45</sup>	Interdisciplinary discussion-clinical, pathologic, radiologic	UIP (7), NSIP (12), DAD (1), OP (3), HP (3), bronchiolitis-associated DILD (2), sarcoidosis (1)	CB: 29/39, FFB: 13/38
Gershman et al (2015) <sup>46</sup>	NR	NR	NR
Hagmeyer et al (2015) <sup>47</sup>	Interdisciplinary discussion-clinical, pathologic, radiologic	IIP (14/20), non-IIP or excluded ILD (11/12)	Definite: 25/32, definite/probable: 31/32
Hernández-González et al (2015) <sup>48</sup>	Interdisciplinary discussion-clinical, pathologic, radiologic	UIP (7), NSIP (8), LIP (1), HP (6), sarcoidosis (1), OP (1), LAM (1), peribronchiolar metaplasia (1)	Definite: 22/33, definite/probable: 26/33
Pourabdollah et al (2015) <sup>49</sup>	Medical history, radiographic, and laboratory findings	NSIP (2), HP (1), PCP (2), PAP (2), GI (16), pulmonary hemorrhage (1), PLCH (1), LC (1), adenocarcinoma (1), anthracosis (1), aspiration (1), capillaritis (1), intravenous drug disease (1)	CB: definite: 21/41; definite/probable: 31/41; FFB: 14/41

The criteria for probable diagnosis used were: Casoni et al<sup>42</sup>: cases of usual interstitial pneumonia tended to show one or more of its 3 main features (patchy fibrosis or fibroblastic foci or honeycombing); Fruchter et al<sup>43</sup>: clinical, radiologic, and histological data suggestive of a single interstitial lung disease entity or several closely related interstitial lung diseases although a definitive diagnosis of a single interstitial lung disease cannot be made; Hagmeyer et al<sup>47</sup>: cryobiopsy findings showing an approximate congruence with the final diagnosis; Hernández-González et al<sup>48</sup>: not defined; Pourabdollah et al<sup>49</sup>: findings such as poorly formed granuloma and distinct changes in the interstitial tissue, which were suggestive of interstitial diseases.

TBLB = transbronchial lung biopsy

CB = cryobiopsy

FFB = flexible forceps biopsy

IPF = idiopathic pulmonary fibrosis

NSIP = nonspecific interstitial pneumonia

DIP = desquamative interstitial pneumonia

PLCH = pulmonary Langerhans cell histiocytosis

HP = hypersensitivity pneumonitis

DILD = drug-induced interstitial lung disease

NR = not reported

DAD = diffuse alveolar damage

OP = organizing pneumonia

GI = granulomatous inflammation

UIP = usual interstitial pneumonia

COP = cryptogenic organizing pneumonia

RBILD = respiratory bronchiolitis-interstitial lung disease

ConB = constrictive bronchiolitis

BO = bronchiolitis obliterans

EP = eosinophilic pneumonia

FB = follicular bronchiolitis

LAM = lymphangioleiomyomatosis

LC = lymphangitis carcinomatosa

PAP = pulmonary alveolar proteinosis

IIP = idiopathic interstitial pneumonia

ILD = interstitial lung disease

LIP = lymphocytic interstitial pneumonia

CRYOPROBE TRANSBRONCHIAL LUNG BIOPSY IN DIFFUSE LUNG DISEASES

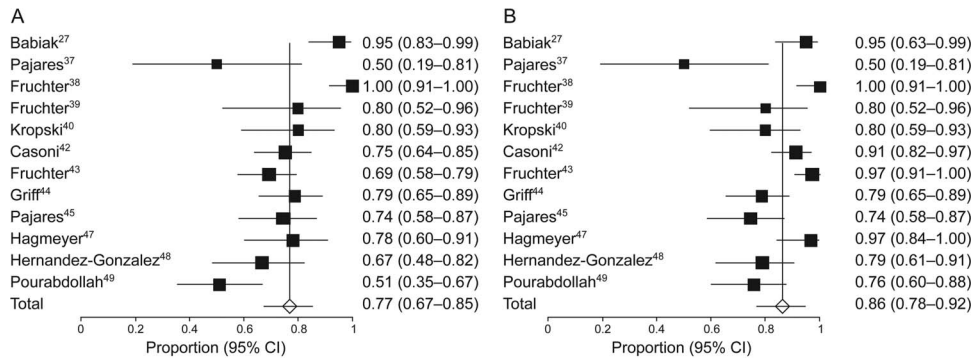


Fig. 2. Diagnostic yield of definite (A) and definite/probable (B) of transbronchial lung biopsy with cryoprobe (random effects model). The diagnostic yield in the individual studies is represented by a square (percentage) through which runs a horizontal line (95% CI). The diamond at the bottom represents the pooled diagnostic yield from the studies.

Table 6. Characteristics of Studies That Compared the Diagnostic Yield of Cryoprobe Biopsy With Flexible Forceps Biopsy

Author	Study Design	Diagnostic Accepted Standard	Methodology	Actual No. of Biopsy Specimens Obtained	Diagnostic Yield
Babiak et al <sup>27</sup>	Retrospective observational	Clinical, radiographic, and pathological findings with 6-month follow-up	FFB performed first followed by CB in the same subject; at least 1 biopsy with each technique per subject	CB: 1.8, FFB: 2	CB: 39/41, FFB: 24/41
Fruchter et al <sup>39</sup>	Retrospective observational	NR	CB and FFB performed in different subjects; FFB group taken from historical controls, 2–3 biopsies with CB, 6–8 biopsies with FFB	CB: 2 (2–3), FFB: 7 (6–8)	CB: 40/40, FFB: 37/40
Pajares et al <sup>45</sup>	Randomized controlled	Interdisciplinary discussion: clinical, pathologic, radiologic	FFB and CB in different subjects; at least three samples taken with each technique	CB: 3.7 ± 0.9, FFB: 3.5 ± 1.2	CB: 29/39, FFB: 13/38
Pourabdollah et al <sup>49</sup>	Prospective, observational	Medical history, radiographic, and laboratory findings	FFB performed first followed by CB in the same subject; 3–4 samples taken with FFB, one with CB	NR	CB: definite: 21/41, definite/probable: 31/41, FFB: 14/41

All values are mean ± SD or mean (range).

CB = cryoprobe biopsy

FFB = flexible forceps biopsy

NR = not reported

intervention for control; bleeding that led either to cardio-pulmonary instability or requirement of a blood transfusion or admission to the ICU) occurred in only 0.3% of cases, similar to that seen with flexible forceps biopsy during flexible bronchoscopy, despite the significantly large size of lung tissue samples.<sup>7</sup> It is postulated that the freezing effect of the cryoprobe coagulates the small vessels ruptured during the process of biopsy, thereby reducing the risk of significant bleeding. The data on mild and moderate bleeding are not presented because the definition of these categories was variable in the included studies. The mortality rate was also low (0.1%), comparable with

that seen with flexible forceps biopsy.<sup>7</sup> This is much lower than that for surgical lung biopsy (2–17%).<sup>17–23</sup> It is noteworthy that all of the studies considered in this review have excluded patients who had reduced lung function, evidence of pulmonary artery hypertension on echocardiography, hemodynamic instability, hypoxemia, or coagulopathy. Thus, the findings of safety of cryo-transbronchial lung biopsy in the present analysis do not apply to patients presenting with any of these features.

The present analysis has a few limitations. First, the diagnostic reference standards used in the studies are different. In the ideal scenario, the yield of a new diagnostic

CRYOPROBE TRANSBRONCHIAL LUNG BIOPSY IN DIFFUSE LUNG DISEASES

Studies	Estimate (95% CI)	Ev/CB	Ev/FFB
Babiak <sup>27</sup>	13.81 (2.93–65.14)	39/41	29/41
Fruchter <sup>38</sup>	7.56 (0.38–151.29)	40/40	37/40
Pajares <sup>45</sup>	5.58 (2.09–14.90)	29/39	13/38
Pourabdollah <sup>49</sup>	5.98 (2.29–15.64)	31/41	14/41
Overall $I^2 = 0\%$ , $P = .79$	6.70 (3.62–12.40)	139/161	88/160

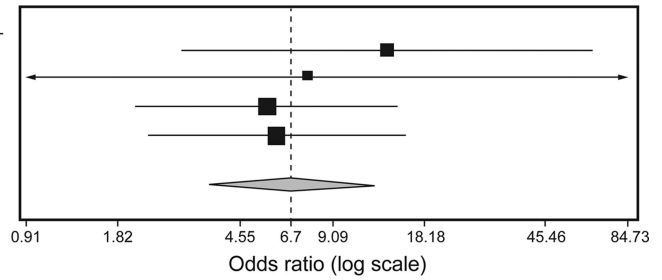


Fig. 3. Forest plot showing the diagnostic yield (both probable and definite) with transbronchial lung biopsy performed with cryoprobe (CB) versus flexible forceps biopsy (FFB). The diagnostic yield was significantly higher in the CB group (odds ratio with 95% CIs, random effects model).

Table 7. Complications Associated With Transbronchial Biopsy Reported in the Included Studies

Author (Year)	Severe Bleeding	Pneumothorax	Death
Babiak et al (2009) <sup>27</sup>	0	2 (due to FFB or CB)	0
Pajares et al (2010) <sup>37</sup>	0	0	0
Fruchter et al (2013) <sup>38</sup>	0	CB: 0, FFB: 1	0
Fruchter et al (2013) <sup>39</sup>	0	0	0
Kropski et al (2013) <sup>40</sup>	0	0	0
Yarmus et al (2013) <sup>41</sup>	0	1 (due to FFB or CB)	0
Casoni et al (2014) <sup>42</sup>	0	19	1
Fruchter et al (2014) <sup>43</sup>	0	2	0
Griff et al (2014) <sup>44</sup>	0	0	0
Pajares et al (2014) <sup>45</sup>	0	CB: 3, FFB: 2	0
Gershman et al (2015) <sup>46</sup>	0	CB: 15, FFB: 9	0
Hagmeyer et al (2015) <sup>47</sup>	2	6/32 (jet ventilation: 3/7 spontaneous breathing: 3/25)	2 (SLB group)
Hernandez-Gonzalez et al (2015) <sup>48</sup>	0	4	0
Pourabdollah et al (2015) <sup>49</sup>	NR	NR	NR

FFB = flexible forceps biopsy  
 CB = cryobiopsy  
 SLB = surgical lung biopsy  
 NR = not reported

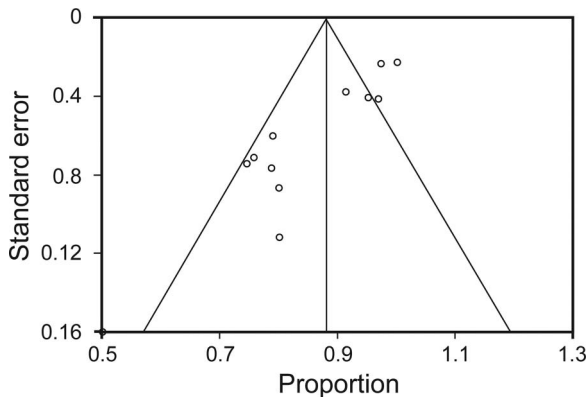


Fig. 4. Funnel plot comparing the proportion versus the SE of the proportion for the diagnostic yield. The circles represent the studies included in the meta-analysis. The line in the center indicates the summary proportion. The other lines represent the 95% CIs. There was evidence of publication bias.

modality such as cryo-transbronchial lung biopsy should be assessed using surgical lung biopsy as the reference standard, with both of the procedures performed in all of the patients. However, because surgical lung biopsy is invasive and is associated with high morbidity and mortality, many patients frequently do not consent for the performance of surgery; hence, it may not be feasible to have such a study design. A diagnosis achieved after a multidisciplinary discussion assimilating all of the clinical, radiologic, and histopathological data (also used in many of the included studies) constitutes the most feasible composite reference standard, endorsed by the American Thoracic Society/European Respiratory Society guidelines for diagnosis of idiopathic interstitial pneumonias.<sup>2,16</sup> Also, we attributed pneumothorax as a complication to cryo-transbronchial lung biopsy where both cryo-transbronchial lung biopsy and flexible forceps biopsy were performed in the same subject. However, these occurred in only 3 in-

stances, and we attributed them to cryo-transbronchial lung biopsy based on a worst case scenario analysis. Most of the studies in this analysis are retrospective observational studies, thus providing only moderate quality evidence for the utility of this technique. Finally, the studies included in this analysis have significant clinical heterogeneity because they have been performed in varied patient populations. There was also the presence of publication bias, which could impact the conclusions of the study. Hence, the results of the present analysis should be considered as hypothesis-generating and require confirmation in larger multi-center randomized trials.

### Conclusions

Transbronchial lung biopsy performed with a cryoprobe during flexible bronchoscopy is safe and offers a high diagnostic yield in subjects with diseases diffusely involving the lung parenchyma. In this early appraisal, the technique seems promising in the evaluation of diffuse parenchymal lung diseases.

### REFERENCES

- Deconinck B, Verschakelen J, Coolen J, Verbeken E, Verleden G, Wuyts W. Diagnostic workup for diffuse parenchymal lung disease: schematic flowchart, literature review, and pitfalls. *Lung* 2013;191(1):19-25.
- Maher TM. A clinical approach to diffuse parenchymal lung disease. *Immunol Allergy Clin North Am* 2012;32(4):453-472.
- Park CH, Paik HC, Haam SJ, Lim BJ, Byun MK, Shin JA, et al. HRCT features of acute rejection in patients with bilateral lung transplantation: the usefulness of lesion distribution. *Transplant Proc* 2014;46(5):1511-1516.
- Gasparetto EL, Ono SE, Escuissato D, Marchiori E, Roldan L, Marques HL, Frare e Silva RL. Cytomegalovirus pneumonia after bone marrow transplantation: high resolution CT findings. *Br J Radiol* 2004;77(921):724-727.
- Levin DC, Wicks AB, Ellis JH Jr. Transbronchial lung biopsy via the fiberoptic bronchoscope. *Am Rev Respir Dis* 1974;110(1):4-12.
- Ensminger SA, Prakash UB. Is bronchoscopic lung biopsy helpful in the management of patients with diffuse lung disease? *Eur Respir J* 2006;28(6):1081-1084.
- Du Rand IA, Blaikley J, Booton R, Chaudhuri N, Gupta V, Khalid S, et al. British Thoracic Society guideline for diagnostic flexible bronchoscopy in adults: accredited by NICE. *Thorax* 2013;68(Suppl 1):i1-i44.
- Poletti V, Patelli M, Poggi S, Bertanti T, Spiga L, Ferracini R. Transbronchial lung biopsy and bronchoalveolar lavage in diagnosis of diffuse infiltrative lung diseases. *Respiration* 1988;54(Suppl 1):66-72.
- Berbescu EA, Katzenstein AL, Snow JL, Zisman DA. Transbronchial biopsy in usual interstitial pneumonia. *Chest* 2006;129(5):1126-1131.
- Tomassetti S, Cavazza A, Colby TV, Ryu JH, Nanni O, Scarpi E, et al. Transbronchial biopsy is useful in predicting UIP pattern. *Respir Res* 2012;13:96.
- Fraire AE, Cooper SP, Greenberg SD, Rowland LP, Langston C. Transbronchial lung biopsy. Histopathologic and morphometric assessment of diagnostic utility. *Chest* 1992;102(3):748-752.
- Kendall DM, Gal AA. Interpretation of tissue artifacts in transbronchial lung biopsy specimens. *Ann Diagn Pathol* 2003;7(1):20-24.
- Raghu G, Collard HR, Egan JJ, Martinez FJ, Behr J, Brown KK, et al. An official ATS/ERS/JRS/ALAT statement: idiopathic pulmonary fibrosis: evidence-based guidelines for diagnosis and management. *Am J Respir Crit Care Med* 2011;183(6):788-824.
- Izbicki G, Shitrit D, Yarmolovsky A, Bendayan D, Miller G, Fink G, et al. Is routine chest radiography after transbronchial biopsy necessary?: A prospective study of 350 cases. *Chest* 2006;129(6):1561-1564.
- Kumar S, Agarwal R, Aggarwal AN, Gupta D, Jindal SK. Role of ultrasonography in the diagnosis and management of pneumothorax following transbronchial lung biopsy. *J Bronchology Interv Pulmonol* 2015;22(1):14-19.
- Travis WD, Costabel U, Hansell DM, King TE Jr., Lynch DA, Nicholson AG, et al. An official American Thoracic Society/European Respiratory Society statement: update of the international multidisciplinary classification of the idiopathic interstitial pneumonias. *Am J Respir Crit Care Med* 2013;188(6):733-748.
- Utz JP, Ryu JH, Douglas WW, Hartman TE, Tazelaar HD, Myers JL, et al. High short-term mortality following lung biopsy for usual interstitial pneumonia. *Eur Respir J* 2001;17(2):175-179.
- Kreider ME, Hansen-Flaschen J, Ahmad NN, Rossman MD, Kaiser LR, Kucharczuk JC, Shrager JB. Complications of video-assisted thoracoscopic lung biopsy in patients with interstitial lung disease. *Ann Thorac Surg* 2007;83(3):1140-1144.
- Kondoh Y, Taniguchi H, Kitaichi M, Yokoi T, Johkoh T, Oishi T, et al. Acute exacerbation of interstitial pneumonia following surgical lung biopsy. *Respir Med* 2006;100(10):1753-1759.
- Park JH, Kim DK, Kim DS, Koh Y, Lee SD, Kim WS, et al. Mortality and risk factors for surgical lung biopsy in patients with idiopathic interstitial pneumonia. *Eur J Cardiothorac Surg* 2007;31(6):1115-1119.
- Rena O, Casadio C, Leo F, Giobbe R, Cianci R, Baldi S, et al. Videothoracoscopic lung biopsy in the diagnosis of interstitial lung disease. *Eur J Cardiothorac Surg* 1999;16(6):624-627.
- Plönes T, Osei-Agyemang T, Elze M, Palade E, Wagnetz D, Loop T, et al. Morbidity and mortality in patients with usual interstitial pneumonia (UIP) pattern undergoing surgery for lung biopsy. *Respir Med* 2013;107(4):629-632.
- Matsuoka K, Kuroda A, Kang A, Imanishi N, Nagai S, Ueda M, Miyamoto Y. Surgical results of video-assisted thoracic surgery and risk factors for prolonged hospitalization for secondary pneumothorax in elderly patients. *Ann Thorac Cardiovasc Surg* 2013;19(1):18-23.
- Dhooira S, Bal A, Sehgal IS, Aggarwal AN, Behera D, Agarwal R. Transbronchial lung biopsy with a flexible cryoprobe: first case report from India. *Lung India* 2016;33(1):64-68.
- Hetzl J, Eberhardt R, Herth FJ, Petermann C, Reichle G, Freitag L, et al. Cryobiopsy increases the diagnostic yield of endobronchial biopsy: a multicentre trial. *Eur Respir J* 2012;39(3):685-690.
- Sehgal IS, Dhooira S, Agarwal R, Behera D. Use of a flexible cryoprobe for removal of tracheobronchial blood clots. *Respir Care* 2015;60(7):e128-e131.
- Babiak A, Hetzel J, Krishna G, Fritz P, Moeller P, Balli T, Hetzel M. Transbronchial cryobiopsy: a new tool for lung biopsies. *Respiration* 2009;78(2):203-208.
- Kmet LM, Lee RC, Cook LS. Standard quality assessment criteria for evaluating primary research papers from a variety of fields. Edmonton, Canada: Alberta Heritage Foundation for Medical Research; 2004.
- Freeman MF, Tukey JW. Transformations Related to the Angular and the Square Root. *Ann Math Stat* 1950;21(4):607-611.

30. Miller JJ. The Inverse of the Freeman-Tukey Double Arcsine Transformation. *Am Stat* 1978;32(4):138-138.
31. DerSimonian R, Laird N. Meta-analysis in clinical trials. *Control Clin Trials* 1986;7(3):177-188.
32. Deeks JJ, Higgins JPT, Altman DG. Analysing and presenting results. In: Alderson P, Green S, Higgins JPT, editors. *Cochrane Reviewers' Handbook* 422 [updated Mar 2004]. Chichester, UK: John Wiley Sons, Ltd, 2004;68-139.
33. Fleiss JL. Analysis of data from multiclinic trials. *Control Clin Trials* 1986;7(4):267-275.
34. Dear K, Begg C. An approach to assessing publication bias prior to performing a meta-analysis. *Stat Sci* 1992;7:237-245.
35. Egger M, Davey Smith G, Schneider M, Minder C. Bias in meta-analysis detected by a simple, graphical test. *BMJ* 1997;315(7109):629-634.
36. Begg CB, Mazumdar M. Operating characteristics of a rank correlation test for publication bias. *Biometrics* 1994;50(4):1088-1101.
37. Pajares V, Torrego A, Puzo C, Lerma E, Gil De Bernabé MA, Franquet T. [Transbronchial lung biopsy using cryoprobes]. *Arch Bronconeumol* 2010;46(3):111-115.
38. Fruchter O, Fridel L, Rosengarten D, Rahman NA, Kramer MR. Transbronchial cryobiopsy in immunocompromised patients with pulmonary infiltrates: a pilot study. *Lung* 2013;191(6):619-624.
39. Fruchter O, Fridel L, Rosengarten D, Raviv Y, Rosanov V, Kramer MR. Transbronchial cryo-biopsy in lung transplantation patients: first report. *Respirology* 2013;18(4):669-673.
40. Kropski JA, Pritchett JM, Mason WR, Sivarajan L, Gleaves LA, Johnson JE, et al. Bronchoscopic cryobiopsy for the diagnosis of diffuse parenchymal lung disease. *PLoS One* 2013;8(11):e78674.
41. Yarmus L, Akulian J, Gilbert C, Illei P, Shah P, Merlo C, et al. Cryoprobe transbronchial lung biopsy in patients after lung transplantation: a pilot safety study. *Chest* 2013;143(3):621-626.
42. Casoni GL, Tomassetti S, Cavazza A, Colby TV, Dubini A, Ryu JH, et al. Transbronchial lung cryobiopsy in the diagnosis of fibrotic interstitial lung diseases. *PLoS One* 2014;9(2):e86716.
43. Fruchter O, Fridel L, El Raouf BA, Abdel-Rahman N, Rosengarten D, Kramer MR. Histological diagnosis of interstitial lung diseases by cryo-transbronchial biopsy. *Respirology* 2014;19(5):683-688.
44. Griff S, Schönfeld N, Ammenwerth W, Blum TG, Grah C, Bauer TT, et al. Diagnostic yield of transbronchial cryobiopsy in non-neoplastic lung disease: a retrospective case series. *BMC Pulm Med* 2014;14:171.
45. Pajares V, Puzo C, Castillo D, Lerma E, Montero MA, Ramos-Barbón D, et al. Diagnostic yield of transbronchial cryobiopsy in interstitial lung disease: a randomized trial. *Respirology* 2014;19(6):900-906.
46. Gershman E, Fruchter O, Benjamin F, Nader AR, Rosengarten D, Rusanov V, et al. Safety of cryo-transbronchial biopsy in diffuse lung diseases: analysis of three hundred cases. *Respiration* 2015;90(1):40-46.
47. Hagemeyer L, Theegarten D, Wohlschlager J, Treml M, Matthes S, Priegnitz C, et al. The role of transbronchial cryobiopsy and surgical lung biopsy in the diagnostic algorithm of interstitial lung disease. *Clin Respir J* 2015; 10.1111/crj.12261.
48. Hernández-González F, Lucena CM, Ramírez J, Sánchez M, Jimenez MJ, Xaubet A, et al. Cryobiopsy in the diagnosis of diffuse interstitial lung disease: yield and cost-effectiveness analysis. *Arch Bronconeumol* 2015;51(6):261-267.
49. Pourabdollah M, Shamaei M, Karimi S, Karimi M, Kiani A, Jabbari HR. Transbronchial lung biopsy: the pathologist's point of view. *Clin Respir J* 2015; 10.1111/crj.12207.
50. Gupta D, Dadhwal DS, Agarwal R, Gupta N, Bal A, Aggarwal AN. Endobronchial ultrasound-guided transbronchial needle aspiration vs conventional transbronchial needle aspiration in the diagnosis of sarcoidosis. *Chest* 2014;146(3):547-556.
51. Goyal A, Gupta D, Agarwal R, Bal A, Nijhawan R, Aggarwal AN. Value of different bronchoscopic sampling techniques in diagnosis of sarcoidosis: a prospective study of 151 patients. *J Bronchology Interv Pulmonol* 2014;21(3):220-226.
52. Poletti V, Cazzato S, Minicuci N, Zompatori M, Burzi M, Schiattone ML. The diagnostic value of bronchoalveolar lavage and transbronchial lung biopsy in cryptogenic organizing pneumonia. *Eur Respir J* 1996;9(12):2513-2516.
53. Ibrahim AS, Allangawi MH, Sattar HA, Mobyed HS, Almohammed AA. Indications, diagnostic yields and complications of transbronchial biopsy over 5 years in the State of Qatar. *Saudi Med J* 2005; 26(4):641-645.
54. Hue SH. Complications in transbronchial lung biopsy. *Korean J Intern Med* 1987;2(2):209-213.