Value of Bedside Lung Ultrasound in Severe and Critical COVID-19 Pneumonia

Shuangshuang Kong, Jing Wang, Yuman Li, Ying Tian, Cheng Yu, Danqing Zhang, Hong Li, Li Zhang, Xueqin Pang, and Mingxing Xie

BACKGROUND: Lung ultrasound (LUS) is an effective imaging modality that can differentiate pathological lung from non-diseased lung. We aimed to explore the value of bedside LUS in patients with severe and critical coronavirus disease 2019 (COVID-19)-associated lung injury. METHODS: Sixty-three severe and 33 critical hospitalized subjects with COVID-19 were enrolled in this study. Bedside LUS was performed in all subjects; chest computed tomography was performed on the same day as bedside LUS in 23 cases. The LUS protocol consisted of 12 scanning zones. LUS score based on B-lines and lung consolidation was evaluated. RESULTS: The most common abnormality of LUS was the various forms of B-lines, detected in 93 (96.9%) subjects; as the second most frequent abnormality, 80 (83.3%) subjects exhibited lung consolidation, mainly located in the posterior lung region. Twenty-four (25.0%) subjects had pleural line abnormalities, and 16 (16.7%) had pleural effusion; 78 (81.3%) subjects had ≥ 2 abnormal LUS patterns, and 93 (96.9%) had bilateral lung involvement. The proportion of bilateral or unilateral lung consolidation and pleural effusion in the critical COVID-19 group were higher than that in the severe group (*P* < .05). The lung consolidation of critical subjects showed a marked increase in most lung areas, including bilateral lateral lung, posterior lung, and left anterior-inferior lung area. The median (interquartile range) LUS scores of critical cases were higher than those of severe cases: left: 14 (12–17) vs 7 (5–12); right: 14 (10–16) vs 8 (3–12); bilateral: 28 (23–31) vs 15 (8–22) (*P* < .001 for all). There was a good correlation between the LUS score and the chest computed tomography score (r = 0.887, *P* < .001). CONCLUSIONS: The most common abnormal LUS pattern in subjects with severe and critical COVID-19 pneumonia was B-lines, followed by lung consolidation. Bedside LUS can provide important information for pulmonary involvement in patients with COVID-19. *Key words: lung; ultrasound; diagnostic imaging; COVID-19; pneumonia; computed tomography.* [Respir Care 2021;66(6):920–927. © 2021 Daedalus Enterprises]

Introduction

The coronavirus disease 2019 (COVID-19) caused by severe acute respiratory syndrome coronavirus 2 (SARS-CoV-2) has spread worldwide, resulting in lung and other multiple organ damage and seriously threatening human life and health.[1-4] Severe and critical COVID-19 patients may have hypoxemia or respiratory failure, as well as shock or multiple organ failure, which require mechanical ventilation and monitoring. Chest computed tomography (CT) has

The authors are affiliated with the Department of Ultrasound, Union Hospital, Tongji Medical College, Huazhong University of Science and Technology, Wuhan, China. The authors are also affiliated with the Hubei Province Key Laboratory of Molecular Imaging, Wuhan, China.

Drs Kong, Wang, Li, and Tian are co-first authors.

This work was supported by the National Natural Science Foundation of China (Grant Nos. 81771851, 81727805, 81922033). The authors have disclosed no conflicts of interest.

Supplementary material related to this paper is available at http://www.rcjournal.com.

Correspondence: Mingxing Xie MD PhD, Department of Ultrasound, Union Hospital, Tongji Medical College, Huazhong University of Science and Technology, 1277# Jiefang Ave, Wuhan 430022, China. E-mail: xiemx@hust.edu.cn.

DOI: 10.4187/respcare.08382

been recommended for the diagnosis of COVID-19,[5,6] but it is limited when there is no bedside CT capability due to the high risk of transporting patients with COVID-19.[7] Lung ultrasound (LUS) identifies ultrasonic artifacts originating from the pleural line and can accurately differentiate pathological lung from non-diseased lung.[8] LUS has the advantages of being fast, noninvasive, convenient (ie, bedside availability),[8-11] and safe with no radiation exposure, all of which are especially suitable for the evaluation and serial observation of patients with severe and critical COVID-19.

The purposes of this study were to summarize the characteristics of LUS in patients with severe and critical COVID-19 in isolation wards, and to provide a reliable method to assess COVID-19–associated lung injury.

QUICK LOOK

Current knowledge

The coronavirus disease 2019 (COVID-19) can result in serious lung damage and complications. The high risk of transporting patients with COVID-19 limits chest computed tomography for critical patients. It is necessary to explore a different imaging tool, such as lung ultrasound (LUS), to evaluate associated lung involvement in pneumonia due to COVID-19.

What this paper contributes to our knowledge

The most common abnormal LUS pattern was B-lines, followed by lung consolidation in severe and critical pneumonia due to COVID-19. A strong correlation between LUS score and computed tomography score was observed, suggesting that bedside LUS is a reliable method to assess COVID-19-associated lung injury.

Methods

Subjects

We included 96 adult subjects who were diagnosed with severe or critical COVID-19 between January 25 and March 20, 2020, in the west branch of Union Hospital, Tongji Medical College, Huazhong University of Science and Technology. COVID-19 was confirmed in these 96 subjects with nucleic acid testing for the diagnosis of SARS-CoV-2 infection, referring to the diagnostic criteria from the National Health Commission of the People's Republic of China guidelines for COVID-19.[12] Of these subjects, 63 with severe COVID-19 were included on the basis of exhibiting any of the following: dyspnea, breathing frequency $\geq$ 30 breaths/min, $S_{pO_2} \leq 93\%$ at rest, $P_{aO_2}/F_{IO_2} \leq 300$ mm Hg, and lung infiltrates $> 50\%$ within 24–48 h. Thirty-three subjects with critical COVID-19 had respiratory failure requiring invasive mechanical ventilation, shock, or multisystem organ failure.

Clinical data for the present analysis were obtained from the medical record system of our hospital, which included clinical findings, medical history, and pathophysiologic findings such as vital signs and laboratory test results. This study was approved by the ethics committee of Union Hospital, Tongji Medical College of Huazhong University of Science and Technology, and informed consent was waived for this retrospective study.

LUS Image Acquisition and Score

Bedside LUS scans were ordered for subjects with severe and critical COVID-19 who presented with dyspnea after oxygen therapy through nasal cannula or mask. LUS was performed by 2 experienced sonographers who had completed LUS training (SK and YT). The images were assessed by these physicians (SK and YT), and they reached consensus on their findings. All subjects underwent bedside LUS examinations on the first day of hospitalization and before mechanical ventilation with the M9 Doppler ultrasonic diagnostic apparatus (Mindray Biomed Electronics, Shenzhen, China) with 1.0–5.0 MHz transducer or the GE LOGIQ E9 (GE Healthcare, Milwaukee, Wisconsin) with 1.0–6.0 MHz transducer. For each hemithorax, 6 regions were scanned: anterior, lateral, and posterior regions were delimited by anatomical landmarks of anterior and posterior axillary lines. Each area was divided in half, including superior and inferior region.[13-15] In each subject, anterior and lateral lung regions were scanned with the subject in the supine position, and the posterior region was scanned with the subject in a lateral or sitting position. All adjacent intercostal spaces must be explored parallel and perpendicular to ribs. For each explored region, the worst finding and the LUS score were recorded according to the following rating: the presence of lung sliding with A-lines or $<$ 3 isolated B-lines, 0; multiple well-separated B-lines, 1; multiple coalescent B-lines, 2; and consolidation, 3.[15,16] The cumulative LUS score corresponded to the sum of each region score, with totals ranging from 0 to 36.

Chest CT Assessment and Simplified Score

Twenty-three of 96 subjects with COVID-19, including 2 critically ill subjects and 21 severely ill subjects, underwent thin-section chest CT scans on the same day as LUS examinations. CT scans were performed during full inspiration and expiration, with a section collimation of 0.5 mm. All subjects were scanned in a helical CT scanner (SOMATOM Force, Siemens Healthineers, Erlangen, Germany) in the supine position. Major CT findings, including ground-glass opacities and consolidations, were recorded.[5,17] To quantify the extent of pulmonary abnormalities, a CT score was assigned

for each lobe of bilateral lung: absent, 0; < 5% of lobe, 1; 5–25% of lobe, 2; 26–49% of lobe, 3; 50–75% of lobe, 4; and 76–100% of lobe, 5.[18] The CT score was calculated by summing the scores from all 5 lung lobes, with totals ranging from 0 to 25.

Statistical Analyses

Statistical analyses were performed with SPSS 25.0 (IBM, Armonk, New York). Continuous normally distributed data are expressed as mean ± SD, and non-normally distributed data are expressed as median (interquartile range [IQR]). Comparison between severe and critical groups was performed with the 2-sample *t* test or the Mann-Whitney test for continuous variables. Categorical variables are expressed as percentage (%) and were compared using the chi-square test or the Fisher exact test. Correlations between LUS score and CT score and clinical data were evaluated with the Spearman correlation coefficient. A 2-tailed P value < .05 was considered statistically significant.

Results

Clinical Characteristics

The clinical characteristics of subjects with severe and critical COVID-19 are summarized in Table 1. Forty-five subjects were male, and 51 were female, with ages ranging from 32 to 97 y (mean 65 ± 13 y). The most common clinical symptoms were fever and cough. Compared with subjects with severe COVID-19, critically ill subjects were more likely to be older and had lower S_{pO_2}, lower lymphocyte count, higher levels of oxygen flow, and higher levels of D-dimer and B-type natriuretic peptide, as well as higher incidence of ARDS, acute kidney injury, acute heart injury, deep vein thrombosis, septic shock, pneumothorax, and mortality. There were no significant differences in gender, body mass index, body temperature, smokers, C-reactive protein, erythrocyte sedimentation rate, alanine aminotransferase, serum creatinine, clinical symptoms, and comorbidities between subjects with severe or critical COVID-19.

LUS Features

The median (IQR) time from the onset of the disease to LUS measurement in severe and critical subjects was 7 (6–10) d. All 96 subjects with COVID-19 had LUS abnormalities, which mainly manifested as patterns of B-lines (93 of 96, 96.9%) and different extent of consolidations (80 of 96, 83.3%). In addition, 24 of 96 (25.0%) subjects had a thickened and irregular pleural line. Pleural effusion was found in 16 of 96 (16.7%) subjects, including 11 cases with a small amount of effusion and 5 with a large amount of effusion. Of the 96 subjects, 78 (81.3%) had ≥ 2 abnormal LUS patterns, while 14 (14.6%) had all abnormal LUS patterns. The LUS characteristics of all 96 subjects with severe and critical COVID-19 are shown in the supplementary materials (available at http://www.rcjournal.com). The LUS features are presented in Figure 1.

The distribution of common LUS features, including B-lines and consolidation in all lung regions of subjects with severe and critical COVID-19, are described in Table 2. The incidences of consolidation in the bilateral lateral lung, posterior lung area, and left anterior-inferior lung of the critically ill group were higher than those of the severe group ($P < .05$ for all). The proportions of B-lines in the left inferior-lateral lung ($P = .02$) and right posterior-superior lung area ($P = .005$) of the group with severe COVID-19 were higher than those of the group with critical COVID-19.

In addition, 93 (96.9%) subjects had bilateral lung involvement. The distribution of LUS abnormalities in unilateral or bilateral lung are shown in Table 3. Compared with the group with severe COVID-19, the group with critical COVID-19 had a higher proportion of bilateral or unilateral lung consolidation and pleural effusion ($P < .05$ for all).

Eleven (11.5%) cases underwent serial bedside LUS measurement, and 2 cases progressed from the severe to critical stage (see the supplementary materials at http://www.rcjournal.com). One case was a 71-y-old woman with clinically diagnosed severe COVID-19 infection. A bedside LUS performed on admission showed abnormal B-lines pattern in all lung regions with no consolidations. On day 30, the subject suffered from respiratory failure, with an inability to maintain $S_{pO_2} > 90\%$ on high-flow oxygen via mask. When a ventilator was needed, the repeat bedside LUS revealed subpleural consolidations in bilateral lateral and posterior lung regions. The other confirmed case was a 76-y-old man who was admitted with symptoms of fever (up to 38.7°C), cough, fatigue, and dyspnea. Bedside LUS examination showed multiple B-lines and right pleural effusion, and no consolidation was observed. After 28 d of treatment, the subject's condition had not improved. A repeat LUS demonstrated increased pleural effusion, and consolidations had appeared in all lung areas.

LUS and Chest CT Score

The median (IQR) left, right, and bilateral LUS scores of critical COVID-19 cases were higher than those of severe COVID-19 cases: left: 14 (12–17) vs 7 (5–12); right: 14 (10–16) vs 8 (3–12); bilateral: 28 (23–31) vs 15 (8–22) ($P < .001$ for all) (Fig. 2). In this study, 23 subjects with COVID-19 underwent chest CT scan, with a median (IQR) CT score of 9 (5–14) and a median (IQR) LUS score of 12 (8–22). There was a good correlation between the LUS and CT scores ($r = 0.887$, $P < .001$) (Fig. 3A). The clinical and LUS characteristics of these 23 subjects with COVID-19 are shown in the supplementary materials (available at http://www.rcjournal.com).

Table 1. Clinical Characteristics of Subjects With Severe and Critical COVID-19

	Total	Severe COVID–19	Critical COVID–19	*P*
Subjects, *n* (male/female)	96 (45/51)	63 (25/38)	33 (20/13)	.057
Age, y	65.4 ± 12.7	63.4 ± 12.2	69.2 ± 12.7	.031
Body mass index, kg/m^2	24.2 ± 2.8	24.5 ± 3.1	23.8 ± 1.9	.29
Body temperature, °C	38.0 (37.5–38.9)	38.0 (37.6–38.8)	38.0 (37.3–39.0)	.71
Breathing frequency, breaths/min	20 (19–25)	20 (19–22)	24 (21–27)	< .001
Oxygen flow, L/min	5 (3–10)	4 (3–6)	10 (6–40)	< .001
S_{pO_2}, %	91 (89–92)	91 (90–92)	89 (88–90)	< .001
Smokers	5 (5.2)	2 (3.2)	3 (9.1)	.34
Clinical symptoms				
Fever	77 (80.2)	51 (81.0)	26 (78.8)	.79
Cough	63 (65.6)	43 (68.3)	20 (6.6)	.50
Expectoration	28 (29.2)	16 (25.4)	12 (36.4)	.35
Dyspnea	23 (24.0)	18 (28.6)	5 (15.2)	.21
Shortness of breath	37 (38.5)	22 (34.9)	15 (45.5)	.38
Chills	10 (10.4)	7 (11.1)	3 (9.1)	> .99
Chest tightness	31 (32.3)	21 (33.3)	10 (30.3)	.82
Fatigue	27 (28.1)	20 (31.7)	7 (21.2)	.34
Poor appetite	17 (17.7)	12 (19.0)	5 (15.2)	.78
Dizzy	7 (7.3)	5 (7.9)	2 (6.1)	> .99
Diarrhea	17 (17.7)	14 (22.2)	3 (9.1)	.16
Vomit	5 (5.2)	4 (6.3)	1 (3.0)	.66
Muscle soreness	13 (13.5)	11 (17.5)	2 (6.1)	.21
Laboratory results				
Lymphocyte count, $\times 10^9$/L	0.80 (0.55–1.27)	1.00 (0.59–1.40)	0.70 (0.52–1.08)	.039
C-reactive protein, mg/L	2.9 (5.2–68.6)	15.1 (4.2–66.8)	37.3 (9.1–71.1)	.63
Erythrocyte sedimentation rate, mm/h	49.0 (28.5–76.0)	46.0 (25.0–79.0)	53.0 (38.0–70.0)	.40
Alanine aminotransferase, U/L	32.5 (22.8–51.0)	60.0 (21.5–47.5)	33.0 (26.0–64.0)	.25
Serum creatinine, mmol/L	65.0 (54.4–80.7)	12.1 (54.0–79.0)	69.0 (55.0–85.0)	.41
B-type natriuretic peptide, pg/mL	65.4 (24.0–146.9)	48.4 (14.1–120.1)	108.1 (50.4–263.8)	.007
D-dimers, μg/mL	2.2 (0.9–4.8)	1.6 (0.6–4.0)	3.9 (2.1–7.1)	< .001
Comorbidities				
Cardiovascular disease	51 (53.1)	29 (46.0)	22 (66.7)	.08
Diabetes	10 (10.4)	7 (11.1)	3 (9.1)	> .99
COPD	7 (7.3)	4 (6.3)	3 (9.1)	.69
Pulmonary tuberculosis	2 (2.1)	0	2 (6.1)	.12
Malignant tumor	8 (8.3)	5 (7.9)	3 (9.1)	> .99
Complications				
ARDS	19 (19.8)	2 (6.1)	17 (27.0)	< .001
Acute kidney injury	3 (3.1)	0	3 (4.8)	.038
Acute heart injury	5 (5.2)	1 (3.0)	4 (6.3)	.046
Deep vein thrombosis	21 (21.9)	7 (21.2)	14 (22.2)	.001
Septic shock	8 (8.3)	0	8 (12.7)	< .001
Pneumothorax	3 (3.1)	0	3 (4.8)	.038
Prognosis				
Discharge	85 (88.5)	63 (100)	22 (66.7)	< .001
Death	11 (11.8)	0	11 (33.3)	< .001

Data are presented as *n* (%), median (interquartile range), or mean ± SD.

LUS Score and Clinical Data

LUS score had a weak correlation with oxygen flow (r = 0.363, *P* = .003) and S_{pO_2} (r = –0.340, *P* = .001) (Fig. 3B, C). However, LUS score was not associated with breathing frequency (r = 0.244, *P* = .056).

Discussion

Our results indicate that fever and cough were the most common clinical symptoms in subjects with severe and critical COVID-19, which is consistent with prior studies.[2,3] Subjects with COVID-19 were also likely to have numerous

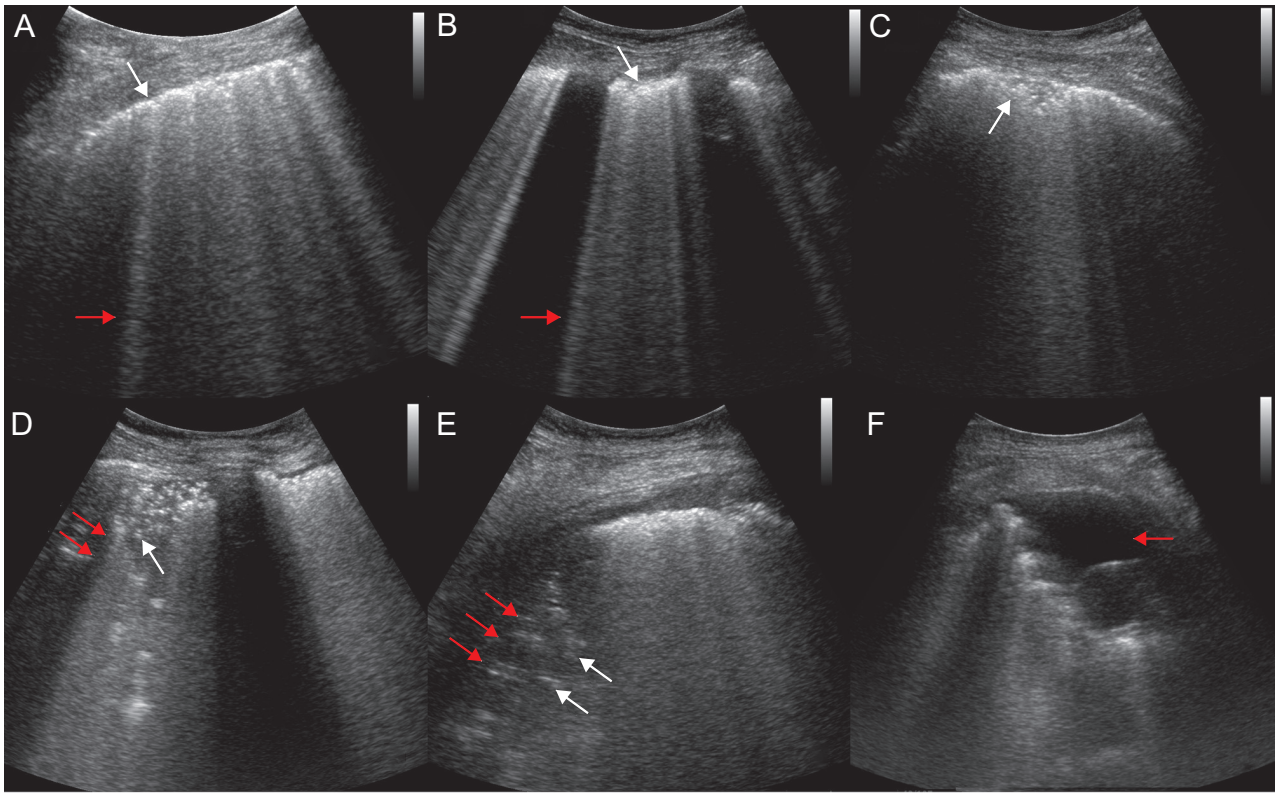

Fig. 1. Lung ultrasound (LUS) features of subjects with COVID-19. A and B: Multiple hyperechoic B-lines (red arrows) arise from the thickened and irregular pleural line (white arrows). C: Small consolidation is visualized as local subpleural hypoechoic with irregular boundary. D and E: Air bronchograms (white arrows) are identified by a linear hyperechoic within lung consolidations (red arrows). F: Pleural effusion is observed in the posterior lower lung region.

Table 2. B-Lines and Consolidation in All Lung Regions of Subjects With Severe and Critical COVID-19

		Multiple B-Lines			Consolidation		
		Severe ($n = 63$)	Critical ($n = 33$)	P	Severe ($n = 63$)	Critical ($n = 33$)	P
L1	Left anterior-superior lung	32 (50.8)	17 (51.5)	> .99	10 (15.9)	10 (30.3)	.12
L2	Left anterior-inferior lung	31 (49.2)	18 (54.5)	.67	10 (15.9)	13 (39.4)	.01
L3	Left superior-lateral lung	33 (52.4)	16 (48.5)	.83	13 (2.6)	15 (45.5)	.02
L4	Left inferior-lateral lung	32 (50.8)	8 (24.2)	.02	18 (28.6)	23 (69.7)	< .001
L5	Left posterior-superior lung	19 (30.2)	5 (15.2)	.14	30 (47.6)	28 (84.8)	< .001
L6	Left posterior-inferior lung	18 (28.6)	4 (12.1)	.08	31 (49.2)	29 (87.9)	< .001
R1	Right anterior-superior lung	34 (54.0)	21 (63.6)	.39	5 (7.9)	8 (24.2)	.055
R2	Right anterior-inferior lung	36 (57.1)	19 (57.6)	> .99	9 (14.3)	9 (27.3)	.17
R3	Right superior-lateral lung	32 (50.8)	10 (30.3)	.08	16 (25.4)	20 (6.6)	< .001
R4	Right inferior-lateral lung	24 (38.1)	9 (27.3)	.37	21 (33.3)	23 (69.7)	.001
R5	Right posterior-superior lung	20 (31.7)	2 (6.1)	.005	31 (49.2)	31 (93.9)	< .001
R6	Right posterior-inferior lung	17 (27.0)	3 (9.1)	.06	28 (44.4)	30 (9.9)	< .001

Data are presented as n (%).

changes in laboratory findings, underlying comorbidities, and complications, which are also in keeping with previous studies.[2-4] Compared with subjects with severe COVID-19, critical subjects had lymphopenia, high levels of D-dimer, higher incidence of complications, and higher mortality. These findings are similar to those previously observed

Table 3. LUS Signs and Scores of Subjects With Severe and Critical COVID-19

	Severe ($n = 63$)	Critical ($n = 33$)	P
Left lung			
Abnormal pleural line	12 (19.0)	6 (18.2)	> .99
Multiple B-lines	59 (93.7)	28 (84.8)	.27
Consolidation	39 (61.9)	29 (87.9)	.004
Pleural effusion	3 (4.8)	9 (27.3)	.003
LUS score	7 (5–12)	14 (12–17)	< .001
Right lung			
Abnormal pleural line	13 (2.6)	7 (21.2)	> .99
Multiple B-lines	57 (9.5)	29 (87.9)	.73
Consolidation	40 (63.5)	33 (100.0)	< .001
Pleural effusion	3 (4.8)	11 (33.3)	< .001
LUS score	8 (3–12)	14 (10–16)	< .001
Bilateral lung			
Abnormal pleural line	6 (9.5)	4 (12.1)	.73
Multiple B-lines	54 (85.7)	27 (81.8)	.77
Consolidation	31 (49.2)	30 (9.9)	< .001
Pleural effusion	2 (3.1)	8 (24.2)	.003
LUS score	15 (8–22)	28 (22–31)	< .001

Data are presented as n (%) or median (interquartile range).
LUS = lung ultrasound

between ICU and non-ICU subjects with COVID-19.[2,4] The differences in the characteristics of inflammatory markers, complications, and prognosis between the critical and severe groups may indicate that critically ill patients are more seriously injured.

In this study, all subjects with severe and critical COVID-19 had abnormal LUS findings, including B-lines, consolidations, abnormal pleural lines, and pleural effusions. Fourteen (14.6%) of the 96 subjects had all abnormal LUS patterns. The different degrees of lung injury and imbalance of air-liquid ratio results in multiple sonographic features. In 78 (81.3%) cases, various manifestations appeared in different lung regions, indicating that varying degrees of lung involvement can occur at the same time.

In our cohort, the most frequent LUS abnormality was multiple B-lines, which was detected in 93 (96.9%) subjects. B-lines are known as ultrasonic artifacts and present as hyperechoic vertical lines arising from the pleural line and spreading up to the edge of the screen, relating to the abnormal interlobular septa or alveoli edema.[19-21] Various patterns of B-lines are observed in the inflammatory exudation of pulmonary interstitium or alveoli. Multiple well-spaced B-lines and coalescent B-lines reflect pulmonary interstitial and alveolar edema, respectively. In addition, the second most common LUS pattern was consolidation, noted in 80

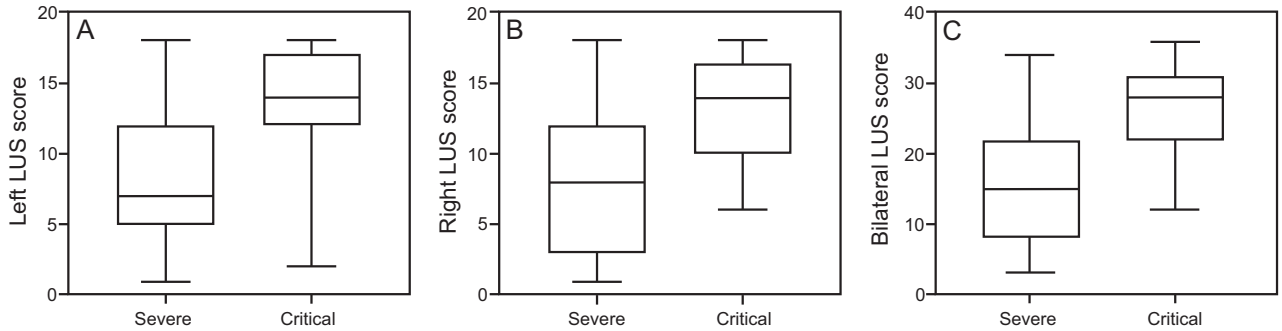

Fig. 2. Comparisons of left (A), right (B), and bilateral (C) LUS score between severe and critical COVID-19 cases. $P < .001$ for each. LUS = lung ultrasound.

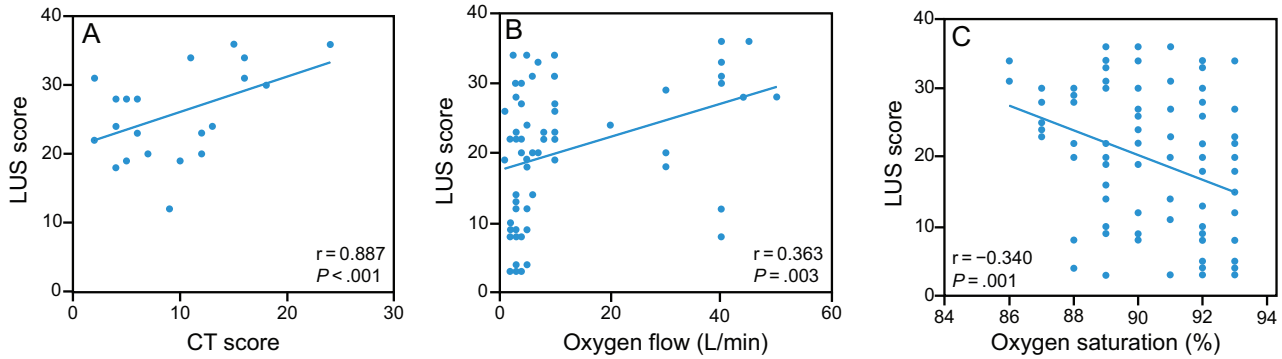

Fig. 3. Correlations between lung ultrasound (LUS) score and computed tomography (CT) score (A), oxygen flow (B), and oxygen saturation (C).

(83.3%) subjects with COVID-19 who had various extent of consolidation, which is caused by loss of air in alveoli, filling with exudates or even collapsing progressively. The proportion of consolidation in this cohort was higher than that reported in previous studies.[22-24] This discrepancy might be due to our study population of subjects with severe and critical COVID-19. Our findings indicate that lung pathology may evolve to consolidation as the disease progresses to the severe or critical stages.

The ultrasonic sign of a small consolidation is a local subpleural hypoechoic signal, while a large consolidation has a characteristic hepatization. Air bronchogram presented with penetration of gas through the bronchus into consolidation during inspiration.[25] There was no gas between the subpleural lung consolidation and chest wall, thus providing a good acoustic window for LUS examination of subjects with COVID-19. Moreover, we observed that 12 (12.6%) subjects displayed pleural effusions, which was caused by the accumulation of exudate in the chest with the progress of pneumonia. Until now, limited pathological reports from postmortem biopsies showed pulmonary edema, diffuse alveolar damage, desquamation of pneumocytes, and hyaline membrane formation in subjects with severe COVID-19.[26] The LUS findings of subjects with severe and critical COVID-19 in this study are in accordance with other recent pathological results.

In our study, 93 (96.9%) subjects had bilateral lung involvement. The incidence of bilateral or unilateral lung consolidation and pleural effusion in the group with critical COVID-19 was higher than that in the severe group. These results indicate that lung consolidation and pleural effusion are more likely to exist in critically ill patients with COVID-19. The consolidation in critically ill subjects showed a marked increase in prevalence in most lung regions, including bilateral lateral lung, bilateral posterior lung area, and left anterior-inferior lung. In these regions, the proportion of B-lines in the left inferior-lateral and right posterior-superior lung region of the critically ill group was lower than that in the group with severe COVID-19. These findings might be due to the progress of the disease, as the ultrasonic signs evolved from B-lines to consolidation, even with pleural effusion.

In the 11 subjects who had repeat LUS, 2 progressed from the severe stage to the critical stage; this was accompanied by changes in the LUS patterns. In these 2 subjects, the major change of LUS abnormalities at follow-up was the progression of consolidation. This finding indicates that lung pathology could develop to consolidation with lesion progression, and different LUS features may correlate with the severity of the lung injury in subjects with COVID-19. The changes of LUS features on repeated LUS suggests that bedside LUS may be a useful follow-up tool for the serial assessment of lung involvement in subjects with confirmed COVID-19.

The LUS score depends mainly on the involved lung regions and ultrasonic features, such as B-lines and consolidation, which can quantify the extent of lung lesions. In our cohort, the LUS scores of critical COVID-19 cases were higher than those of severe cases. These results suggest more severe lung injury in critically ill patients, and the LUS score may reflect the progression of lung lesions. In addition, we noted a weaker correlation between LUS score and oxygen flow and oxygen saturation in this study, which may also indicate that LUS reflects the degree of disease to some extent. Previous studies have reported good correlation between the total number of B-lines score and the high-resolution CT simplified score in subjects with interstitial lung disease.[27] Similarly, there was also a strong correlation between the LUS score and the chest CT score, which was used as a semi-quantitative approach to assess the extent and severity of infectious lung disease.[27,28] Our results demonstrate the value of LUS for the assessment of COVID-19 compared to the use of chest CT, which had been recommended as the first-line imaging test for identifying pneumonia. In addition, CT imaging studies have reported that early-stage lung lesions in subjects with COVID-19 are mainly located peripherally and subpleurally, and the distribution diffuses with the progress of the disease.[17] Because lung ultrasonic signs originate from the pleura line, the characteristics of subpleural region involvement can improve the accuracy of the LUS examination in patients with COVID-19.

Our data indicate that lung consolidations are mainly located in the posterior lung regions, followed by the lateral and anterior areas, which may be related to the gravity effect in supine position. It is worth noting that patients with COVID-19 often take the original supine position for bedside LUS examinations, and the dorsal lung region had a greater tendency to be involved with consolidation. Therefore, patients with COVID-19 need to be assisted in prone or lateral decubitus positions to fully expose the chest wall and expand the scope of the scan, which helps comprehensively assess the extent of lung injury.

There are several limitations in this study. First, this was a retrospective analysis, so extrapolation of our results could be affected by local bias; a prospective study using LUS would have greater scientific value. Second, because our center was a designated hospital to treat severe and critically ill patients with COVID-19 pneumonia in China, we could not obtain data from milder cases of COVID-19. Accordingly, our findings may not be applicable to the entire COVID-19 population. Third, this is a single-center study and is limited by the small sample size in our hospital. Therefore, multicenter studies with larger sample sizes are needed to confirm our findings. Fourth, it is difficult to detect central lung lesions with LUS without pleural involvement. Fifth, ultrasonic detection is limited by subcutaneous emphysema and the occlusion of scapula.[29] Finally, the good correlation of LUS scores with CT scores noted in our study may not be generalizable to the larger population

because we only had chest CT information for a small subset of subjects.

Conclusions

Subjects with severe and critical COVID-19 had typical LUS features, mainly consisting of B-lines and consolidation. A strong correlation between LUS score and CT score was observed, suggesting that bedside LUS is a reliable method to assess and monitor lung injury associated with COVID-19.

REFERENCES

1. Gralinski LE, Menachery VD. Return of the coronavirus: 2019-nCoV. Viruses 2020;12(2):135.
2. Huang C, Wang Y, Li X, Ren L, Zhao J, Hu Y, et al. Clinical features of patients infected with 2019 novel coronavirus in Wuhan. Lancet 2020;395(10223):497-506.
3. Chen N, Zhou M, Dong X, Qu J, Gong F, Han Y, et al. Epidemiological and clinical characteristics of 99 cases of 2019 novel coronavirus pneumonia in Wuhan, China: a descriptive study. Lancet 2020;395(10223):507-513.
4. Wang D, Hu B, Hu C, Zhu F, Liu X, Zhang J, et al. Clinical characteristics of 138 hospitalized patients with 2019 novel coronavirus-infected pneumonia in Wuhan, China. JAMA 2020;323(11):1061-1069.
5. Li B, Li X, Wang Y, Han Y, Wang Y, Wang C, et al. Diagnostic value and key features of computed tomography in coronavirus disease 2019. Emerg Microbes Infect 2020;9(1):787-793.
6. Xu X, Yu C, Qu J, Zhang L, Jiang S, Huang D, et al. Imaging and clinical features of patients with 2019 novel coronavirus SARS-CoV-2. Eur J Nucl Med Mol Imaging 2020;47(5):1275-1280.
7. Zhou F, Yu T, Du R, Fan G, Liu Y, Liu Z, et al. Clinical course and risk factors for mortality of adult inpatients with COVID-19 in Wuhan, China: a retrospective cohort study. Lancet 2020;395(10229):1054-1062.
8. Gillman LM, Kirkpatrick AW. Portable bedside ultrasound: the visual stethoscope of the 21st century. Scand J Trauma Resusc Emerg Med 2012;20:18.
9. Islam M, Levitus M, Eisen L, Shiloh AL, Fein D. Lung ultrasound for the diagnosis and management of acute respiratory failure. Lung 2020;198(1):1-11.
10. Lichtenstein DA. Ultrasound in the management of thoracic disease. Crit Care Med 2007;35(5 Suppl):S250-S261.
11. Volpicelli G, Elbarbary M, Blaivas M, Lichtenstein DA, Mathis G, Kirkpatrick AW, et al. International evidence-based recommendations for point-of-care lung ultrasound. Intensive Care Med 2012;38(4):577-591.
12. National Health Commission of the People's Republic of China. Chinese Management Guideline for COVID-19 (Trial Version 3.0). 2020 Available at: http://www.nhc.gov.cn/xcs/yqfkdt/202001/f492c9153ea9437bb587ce2ffcbee1fa.shtml. *Accessed January 23, 2020.*
13. Soummer A, Perbet S, Brisson H, Arbelot C, Constantin JM, Lu Q, et al. Ultrasound assessment of lung aeration loss during a successful weaning trial predicts postextubation distress. Crit Care Med 2012;40(7):2064-2072.
14. Bouhemad B, Dransart-Rayé O, Mojoli F, Mongodi S. Lung ultrasound for diagnosis and monitoring of ventilator-associated pneumonia. Ann Transl Med 2018;6(21):418.
15. Caltabeloti F, Monsel A, Arbelot C, Brisson H, Lu Q, Gu WJ, et al. Early fluid loading in acute respiratory distress syndrome with septic shock deteriorates lung aeration without impairing arterial oxygenation: a lung ultrasound observational study. Crit Care 2014;18(3)R91.
16. Wang G, Ji X, Xu Y, Xiang X. Lung ultrasound: a promising tool to monitor ventilator-associated pneumonia in critically ill patients. Crit Care 2016;20(1):320.
17. Shi H, Han X, Jiang N, Cao Y, Alwalid O, Gu J, et al. Radiological findings from 81 patients with COVID-19 pneumonia in Wuhan, China: a descriptive study. Lancet Infect Dis 2020;20(4):425-434.
18. Chang YC, Yu CJ, Chang SC, Galvin JR, Liu HM, Hsiao CH, et al. Pulmonary sequelae in convalescent patients after severe acute respiratory syndrome: evaluation with thin-section CT. Radiology 2005;236(3):1067-1075.
19. Dietrich CF, Mathis G, Blaivas M, Volpicelli G, Seibel A, Wastl D, et al. Lung B-line artefacts and their use. J Thorac Dis 2016;8(6):1356-1365.
20. Chiumello D, Mongodi S, Algieri I, Vergani GL, Orlando A, Via G, et al. Assessment of lung aeration and recruitment by ct scan and ultrasound in acute respiratory distress syndrome patients. Crit Care Med 2018;46(11):1761-1768.
21. Ji L, Li Y, Cao C, Lv Q, Xie M. Serial bedside lung ultrasonography in a critically ill COVID-19 patient. QJM 2020;113(7):491-493.
22. Lomoro P, Verde F, Zerboni F, Simonetti I, Borghi C, Fachinetti C, et al. COVID-19 pneumonia manifestations at the admission on chest ultrasound, radiographs, and CT: single-center study and comprehensive radiologic literature review. Eur J Radiol Open 2020;7:100231.
23. Xing C, Li Q, Du H, Kang W, Lian J, Yuan L. Lung ultrasound findings in patients with COVID-19 pneumonia. Crit Care 2020;24(1):174.
24. Lu W, Zhang S, Chen B, Chen J, Xian J, Lin Y, et al. A clinical study of noninvasive assessment of lung lesions in patients with coronavirus disease-19 (COVID-19) by bedside ultrasound. Ultraschall Med 2020;41(3):300-307.
25. Lichtenstein D, Mezière G, Seitz J. The dynamic air bronchogram. A lung ultrasound sign of alveolar consolidation ruling out atelectasis. Chest 2009;135(6):1421-1425.
26. Xu Z, Shi L, Wang Y, Zhang J, Huang L, Zhang C, et al. Pathological findings of COVID-19 associated with acute respiratory distress syndrome. Lancet Respir Med 2020;8(4):420-422.
27. Man MA, Dantes E, Domokos Hancu B, Bondor CI, Ruscovan A, Parau A, et al. Correlation between transthoracic lung ultrasound score and hrct features in patients with interstitial lung diseases. J Clin Med 2019;8(8):1199.
28. Wangkaew S, Euathrongchit J, Wattanawittawas P, Kasitanon N. Correlation of delta high-resolution computed tomography (HRCT) score with delta clinical variables in early systemic sclerosis (SSc) patients. Quant Imaging Med Surg 2016;6(4):381-390.
29. Reissig A, Copetti R. Lung ultrasound in community-acquired pneumonia and in interstitial lung diseases. Respiration 2014;87(3):179-189.